HISTOLOGICAL ANALYSIS OF EQUINE CARTILAGE DEVELOPMENT

What are the histological changes during cartilage development and can a prediction for osteochondrosis in later life be made?

Griffith Draviet (Mr Pine Chip x Grammy Award)

Research Project Veterinary Medicine Utrecht University

Dept. of Equine Sciences and Dept. of Biochemistry and Cell Biology

February/March 2014

Susan van der Vrande

Supervision: Janneke Boere, PhD student; Prof. P.R. van Weeren

Prefatory note:

The curriculum of Veterinary Medicine consists of several elements, of which one is a research project. In twelve weeks' time veterinary students from Utrecht University will carry out a research project. The subjects of these research projects vary. Students who have chosen for a clinical course related to companion animals are free to do their research project in another discipline, for example horses. This paper is the final report of a research project carried out by S.P.H. van der Vrande at the department of Biochemistry & Cell Biology at Utrecht University. The subject of this research project is the development of cartilage from young horses. Research was executed to learn more about the development of cartilage in the knee joint of foals, with special attention to the collagen orientation in the developing cartilage and the possible development of osteochondral lesions. Osteochondrosis is a major problem in the horse industry and lesions appear (and disappear) mostly in the first months of life. The histological research on the development of the equine juvenile cartilage is a way to learn more about the normal development of cartilage and possibly about the onset of osteochondrosis. Polarised light microscopy performed in this research project revealed new information about the normal development of equine cartilage. The practical work of this research project was executed in the histological laboratory of the IRAS and the orthopaedic research laboratory of the UMC Utrecht.

Susan van der Vrande

Table of contents:

Abstract

Osteochondrosis (OC) is a major problem in the horse industry. This developmental orthopedic disease is defined as a focal disturbance in endochondral ossification. During maturation of the skeletal system a complex process known as endochondral ossification takes place. The embryonic longitudinal bones are completely composed out of cartilage and most of this cartilage will be gradually be replaced by bone when a foal matures. Osteochondrosis is considered as a dynamic process; most often lesions can appear and disappear again during cartilage development in the first months of life. Remarkably is seems that after the age of 8 months the situation remains stable. There are several factors supposed to play a more or less significant role in the etiology of this multifactorial disease. For example rapid growth, heredity, biomechanical loading and nutrition are all studied and suspected to play a certain role in the etiology. Internationally a lot of research has been done by many scientists, focused on the etiology and pathology of equine OC. However, it is still unclear which process in the developing cartilage is the one that makes a lesion temporary or permanent. In literature only a few papers can be found which specify on the details of equine cartilage development. Therefore, in this study our research aim was to perform a thorough histological analysis of developing cartilage tissue. The studied samples were derived from 11 foals without clinical signs of orthopedic disease at the time of dead. In these tissue samples we investigated the following cartilage characteristics: cartilage thickness, cellularity, vascularity and collagen orientation. Cartilage thickness of both the lateral and medial femoral condyle was measured and compared in relation to each other and under influence of maturation. Age dependent cartilage cellularity and blood vessel distribution of the specimen was measured and possible differences between the lateral and medial femoral condyle were measured. The collagen structure was studied with a picrosirius red staining using polarized light microscopy. Besides collecting detailed information about the development of cartilage, early histological changes that could be precursors for OC lesions in later life were not found. Cartilage thickness was found to be related to age, in both lateral and medial femoral condyles. Cartilage thickness was significantly higher in the medial femoral condyle compared to the lateral femoral condyle. Cell density was found to decreases during maturation which is in line with the expectations, the location (lateral or medial) does show an unexpected difference. Cell density appears to be higher in the lateral femoral condyle. No significant difference in cell density could be found for the different subregions in the cartilage of the foals. Developing cartilage is found to become avascular at the age of approximately 5 months. Data show a sigmoidal relationship between vascularity and age, indicating a limited start value for amount of blood vessels in the tissue during development. There are no significant differences between the lateral and medial femoral condyle and no significant differences between the different subregions in the cartilage. Against expectations, we found that collagen orientation is already present as early as 10 months gestation and is identical to the orientation known for articular cartilage in adult animals. Collagen structure in the superficial zone of the cartilage was static and similarly orientated in tissue of all ages (age range: 10 months gestation - 6 months and 15 days post-partum), whereas only the underlying non-oriented part of the cartilage is gradually taken over by bone formation during joint maturation.

Introduction

Normal development - Endochondral ossification

During growth and development of the skeletal system the embryonic cartilaginous model (1) of the longitudinal bones is gradually replaced by bone. The complex process by which this happens is known as endochondral ossification (1). The start and continuation of this process does not happen unprompted.

The behaviour of chondrocytes during endochondral ossification is a complex process which needs to be strictly regulated. There are several factors which can work together or act individually on chondrocyte metabolism and the extracellular matrix to complete the endochondral ossification. In the prenatal foal there is an embryonic cartilage model which is formed through the condensation of mesenchymal stem cells (1). Differentiation of the mesenchymal cells results in the formation of chondrocytes. The newly formed chondrocytes start with the secretion of both extracellular matrix and regulatory factors and thereby take care of the formation of their own extracellular environment.

The extracellular matrix of the growing cartilage consist of water, different types of collagens, proteoglycans and glycoprotein's (2), which is subsequently invaded by blood vessels and a mixture of cells. These invading cells (including osteoclasts, bone marrow stromal cells, and osteoblasts (differentiated stromal cells) are responsible for the formation of the primary and secondary ossification fronts (1), see figure 1.

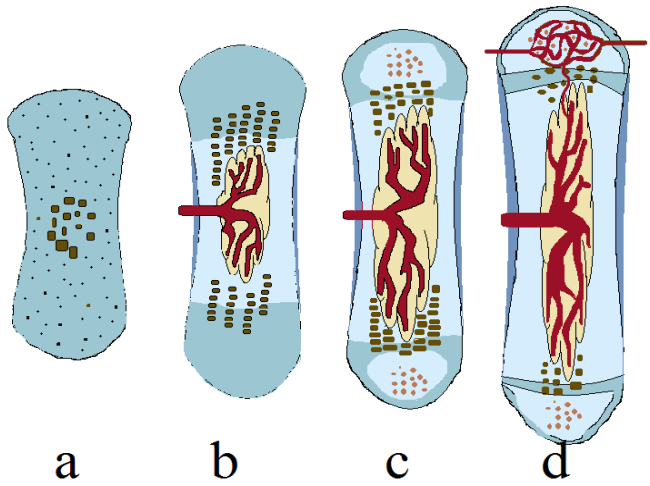

Figure 1: The process of endochondral ossification. Homogenous distributed dots indicate the resting chondrocytes; centrally located squares indicate proliferative and (pre)hypertrophic chondrocytes. a) The cartilage model. b) Formation of the primary ossification centre with chondrocyte hypertrophy and invasion of blood vessels. c) Formation of the secondary centres of ossification. In between the centres of ossification the growth plate is established. The growth plate is responsible for the longitudinal growth of the bone. d) Blood vessels invade the secondary ossification front. Ossification centres are completed.

The invading blood vessels and osteogenic cells initiate the mineralization process of the embryonic cartilage model during endochondral ossification (3). The bone marrow stromal cells differentiate into osteoblasts and on their turn differentiate into osteocytes, the final bone cells (inactive osteoblast trapped within the formed bone in lacunae, connected by caniculi).

Extracellular matrix vesicles (produced by chondrocytes and osteoblasts) help in the mineralization process by depositing their calcium and phosphorus load and indirectly decreasing breakdown of mineralization by secreting the enzyme alkaline phosphatase (which degrades inhibitors of mineralization) (3). If this process of endochondral ossification occurs without disturbances, the cartilage model will be replaced by bone and endochondral ossification is complete. If, however, this process is interrupted (by so far unknown factors), osteochondral lesions can occur.

A disruption of endochondral ossification will lead to growth inhibition in the disrupted area and therefor differences in thickness of the epiphyseal cartilage. Because of longer diffusion distances,

the cells nutrition is impaired and overall support is affected, causing local weakness in the affected cartilage and finally leading to necrosis of cells (4). The process of endochondral ossification cannot convert necrotic areas in the cartilage into bone and a osteochondral lesion is what could remain (5).

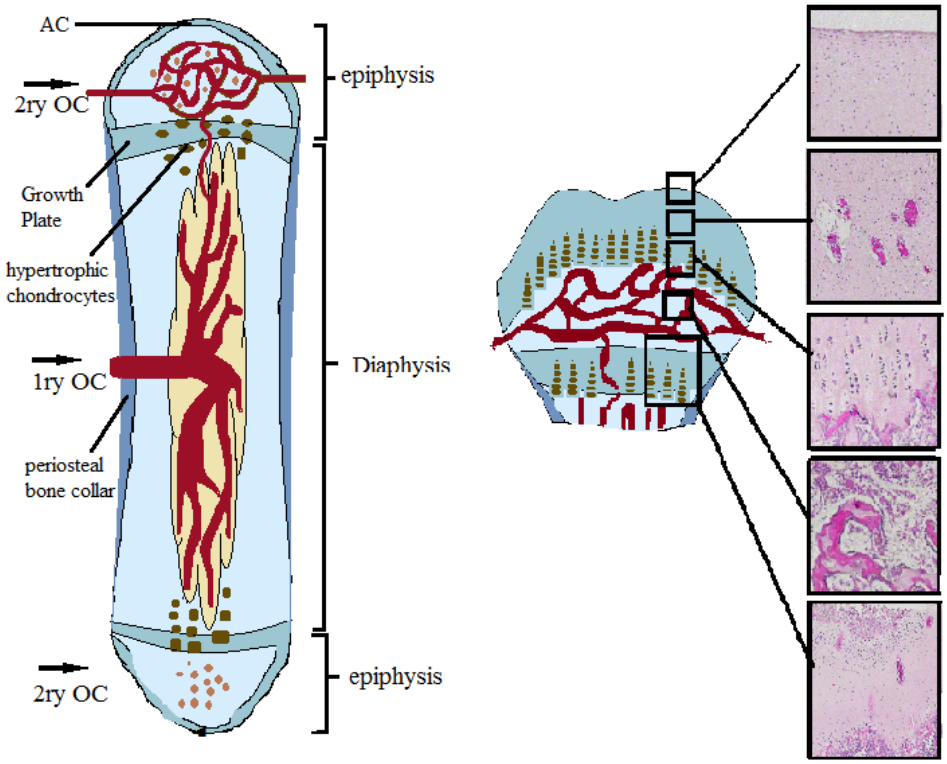

Figure 2. Left panel: Bone anatomy with primary ossification front (1ry OC) and secondary ossification centres (2ry OC). AC= articular cartilage, defined as the cartilage at the surface of the epiphysis that contains no blood vessels (32). Right panel: enlarged representation of the growth plate, secondary ossification front and the articular cartilage in the developing bone/cartilage. Boxes show histological section (H&E staining) of correlating regions of the secondary ossification front and the articular cartilage.

Onset of Osteochondrosis

For years osteochondrosis (OC) was considered to be a static disease in which horses were strictly affected or strictly not affected. This statement was doubted by the scientist Strömberg *et al.,* who showed already in 1979 that osteochondral lesions could be found in repeated examinations over time in horses affected with OC (6). Not only this study, but other studies as well showed that OC is not a static disease at all (7) and more recent studies showed that during the first months postpartum osteochondral lesions can appear and disappear again. This dynamic character of osteochondral lesions seems to be joint related (4). Taken into account the biological variance in the individual

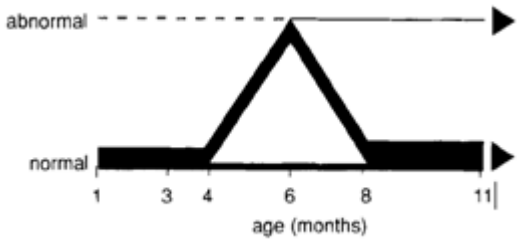

Figure 3: diagram of the general early development of osteochondral lesions at the middle region of the lateral femoral ridge. From: K.J. Dik et al. (1999).

development in horses with osteochondral lesions a general pattern of development of osteochondral lesions can be found for specific joints (8). In this research project the lateral and femoral condyle of the femur were examined. According to literature, at these locations osteochondral lesions are found to develop mostly from the age of 4-5 months, with a maximum of newly formed lesions at the age of 6 months. After the age of 6 months the amount of developing lesions decreases and the repair of the defects increases or stays the same. This is shown in the diagram in figure 3, adapted from Dik *et al*. 1991 (8). According to this study it is assumed that after 8 months the osteochondral lesions remain the same and the dynamic process of OC becomes static around this age (8). This implicates that the developing equine knee is extremely vulnerable at the age of 4-8 months. In order to unravel the dynamic process of cartilage development and possible OC lesion formation, in our study the focus will lie on the development of the equine cartilage specifically during these significant first 8 months of development. Important characteristics of developing cartilage (vascularity, thickness, cellularity and collagen orientation) will be examined, as discussed below.

Vascularity

Blood vessels in the growing cartilage run in the cartilage canals which are responsible for the supply of nutrition to the growth cartilage and for the delivery of new cells and overall support. They also play a significant role in the formation of the ossification centres (9). Cartilage canals are present in growth cartilage during a limited period of time. Both afferent and efferent blood vessels run within the cartilage canals (10), entering the cartilage canals from the perichondrium (11,12). In growth cartilage there are no anastomoses formed between cartilage canals (13), instead cartilage canals are found to cross into the underlying bone and form anastomoses there with the vessels of the bone marrow (10), see figure 2 right panel. The aetiology of OC is often related to vascularity (9,14,15), therefor in the present study the aim was to evaluate the developments of the vasculature during cartilage development.

The research questions that we liked to answer were:

- What is the course of blood vessels development during maturation and at which age does the cartilage become avascular?
- If the cartilage canals regress in the growing cartilage, could a difference in vasculature (qualitatively/quantitatively) be found in different regions of the cartilage (region close to the bone, middle region and the region close to the articular surface.)

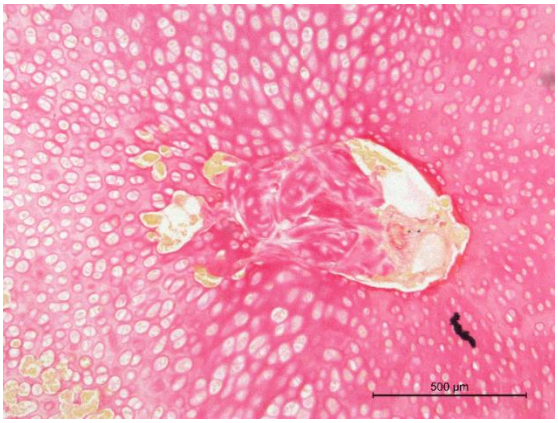

Figure 4: Endochondral ossification of a cartilage canal. Picrosirius red staining, 2,5x magnification. Collagen was stained red, proteins were stained yellowish.

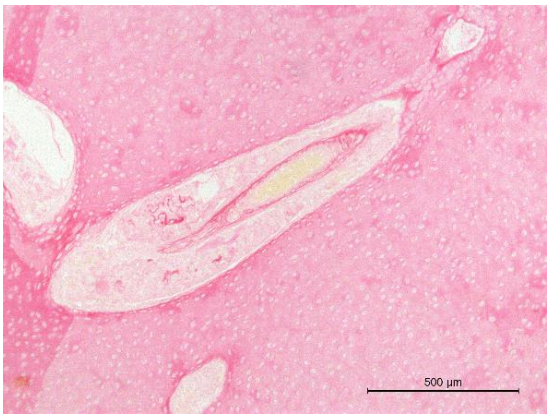

Figure 5: A cartilage canal with containing blood vessels. Obliquely raised. Picrosirius red staining, 2,5x magnification.

- Is there a difference in vascular development between the lateral and medial site of the femoral condyle?

We hypothesized that during maturation the cartilage canals start to regress and that the regression is complete at the age of approximately 7 months postpartum. Furthermore we expected to find differences in vascularity in the 3 defined subregions from bone to cartilage surface, with the highest blood vessel count in the zone closest to the bone.

Cartilage thickness

Cartilage thickness contributes fundamentally to the tissues' biomechanical function (16) and therefor is an important factor to examine in this study. It is suggested that cartilage thickness is area specific and dependent on biomechanical loading (17). In this study we compared cartilage thickness to other variables such as age, cartilage cellularity and anatomical region. In this way we attempted to define the changes in the cartilage layer that occur during normal development and possibly find disturbances that could be early signs for OC. The research questions were:

- Is there a significant difference between the cartilage thickness in the medial or lateral condyle?
- Can a correlation be found between age and cartilage thickness, and at which age does cartilage thickness remain stable?

Cellularity

In the current research project cell density was measured and compared to age, location (lateral or medial), subregion (close to the surface, middle, deep) and blood vessels per mm2. Research questions concerning cellularity were:

- Can a difference be found in cell density between the lateral and medial condyle of the femur?
- Can a significant difference in cell density be found between the different subregions? (Close to the bone, middle, close to the surface.)
- Does cell density decrease during maturation?

Collagen orientation

The spatial organization of the collagen fiber network plays an important role for the biomechanical function of the joint (18,19). There are different types of collagen present in cartilage. In articular cartilage (AC) the type II collagen is the most abundant extracellular matrix molecule (20). Type II collagen resists the expanding pressure from the proteoglycans in the cartilage and the shear stress that is produced during joint movement (21-23). Until now there has been little attention for type II collagen in the developing cartilage, notwithstanding the possible relation with early osteochondrotic lesions (24). In our study we attempted to analyze and describe the development in the 3D structure of collagen fibers using picrosirius red staining and polarized light microscopy. In adult horses the collagen of the AC is oriented in a specific organization known as the "Benninghof structure" (25). The Benninghof model describes three different layers. First, at the articular cartilage surface there is a thin superficial zone, see figure 6 A. The collagen fibers in this zone are arranged parallel to the articular cartilage surface. Second, moving towards the bone, there is a thicker transitional zone in which the collagen orientation is random and lacking a dominant orientation, see figure 6 B. The third and last layer described in the Benninghof structure is the deep zone, see figure 6 C, which is the thickest layer with the collagen fiber orientation either radial or perpendicular to the subchondral bone (25). Because of the very low regenerative and remodeling capacity of mature cartilage (26), the correct development of this "Benninghof structure" during cartilage maturation is crucial for the future function of the cartilage. Additionally, several researchers focused on the question if there already is a collagen orientation in the prenatal animal or, instead, does the collagen structure develop after birth, for example under the influence of biomechanical loading. In this research paper there will be a focus on this subject as well. This background information lead to the following research questions:



Figure 6: Example of the Benninghof structure in an adult horse (Horse 14). 2,5 x magnification, scale bar 500µm. A=superficial layer. B=transitional layer C=deep layer. D=Bone/cartilage transition

- Can a Benninghof structure be found in the collagen orientation in tissue from prenatal foals? And if not, at which age does Benninghof structure originates?
- Could a difference in collagen orientation be found between the lateral and medial condyle of the femur?

Materials and Methods:

Osteochondral plugs

Osteochondral plugs from the foals used in this study were obtained after euthanasia, abortion or after spontaneous death. For an example of the osteochondral plug see figure 7. In this study osteochondral plugs of 11 foals examined (n=11), including 2 prenatal foals. The cause of abortion or death, age, breed and sex are collected and presented in Table 1. Age varies between prenatal foals from 10 months pregnancy till foals aged 6 months and 15 days. Most of the foals are from the KWPN breed (n= 9), one Arabian horse and one Quarter horse are involved in this study. In each foal three osteochondral plugs are collected at the medial and lateral side of the femoral condyle of the right knee. A corer with a diameter of 6 mm is used to collect the samples. One osteochondral plug from each site is stored in 4% formaldehyde solution (Klinipath) directly after collection. The oldest sample was stored in formaldehyde for more then 1,5 year before the onset of this study. Two months before the onset of this study all samples are fixed again in fresh 4% formaldehyde. The samples are decalcified with 0,34M (pH=8) EDTA for the duration of one week (detailed protocol in appendix). After decalcification the samples were placed in the Shandon Citadel 1000 tissue processor and eventually embedded in paraffin. Series of ten 5 µm thick sections where cut from each block and numbered. The microtome used in this study is a Micro Tec CUT 4060 microtome. Bone/Cartilage is a challenging tissue to cut, therefore microtome blades of the type Leica 113243186 are used in this research project. Temperature of the *Klinipath* water bath was set 39,0°C. Only *Superfrost-plus®* microscope slides are used in this study to increase adhesion. Slides where placed in a 37,5°C incubator overnight. Before the staining procedure, slides where placed in a 60°C incubator for 3-4 hours and deparaffinised by subsequent incubation in xylene for four minutes (twice), EtoH 100%, EtOH 96%, EtOH 70%, EtOH 50% and aquadest for two minutes each.

Figure 7: Osteochondral plug of horse 1, KWPN aged 1 day, lateral femoral condyle.

Table 1: Overview of the horses used in this research project

Horse	Age	Sex	Breed	Reason for euthanasia
1	10 months gestation	Stallion	KWPN	Abortion due to surgery mother
2	10 months gestation	Mare	KWPN	Died immediately after sectio caesarea
3	11 days	Stallion	KWPN	Malformations
4	1 day	Mare	KWPN	arthrogrypose carpi/malformations
5	2 months 3days	Mare	KWPN	Invagination ilium
6	2 months 21 days	Stallion	KWPN	Diarrheic, colitis, bite wounds dog
7	4 months 25days	Mare	KWPN	Uneven feet
8	6 months 15 days	Stallion	Quarter Horse	Severe ataxia
9	28 days	Stallion	Arabian Horse	Septic, extremely weak
10	18 days	Mare	KWPN	Uneven curved legs
11	1 day	Stallion	KWPN	Rupture of urinary bladder, prolapse

H&E staining:
The Mayer's haematoxylin and Eosin Stain (Klinipath) was used to give a general overview of the tissue. The slides were stained by subsequent incubation in haematoxylin for four minutes, rinsing tap water for 10 minutes, eosin for three minutes, EtOH 70% for 30 seconds and EtOH 96%, EtOH 100% (twice) and xylene (twice) for one minute each. (Detailed protocol can be found in the appendix.)

Cartilage thickness:
Cartilage thickness was measured in H&E stained sections in LAS (Leica application suite) version 4.2. Stitch images (4x magnification) were made to create an image in which the full thickness of the cartilage can be seen in a single view. With every new image taken the stitch function of LAS v4.2 was used to assure the quality of the stitch. Cartilage thickness in each complete stitch image was calculated as the average of triple measurements in each image. See figure 8 for an example of the cartilage measurement. Cartilage thickness was measured on the medial and the lateral side of each horse.

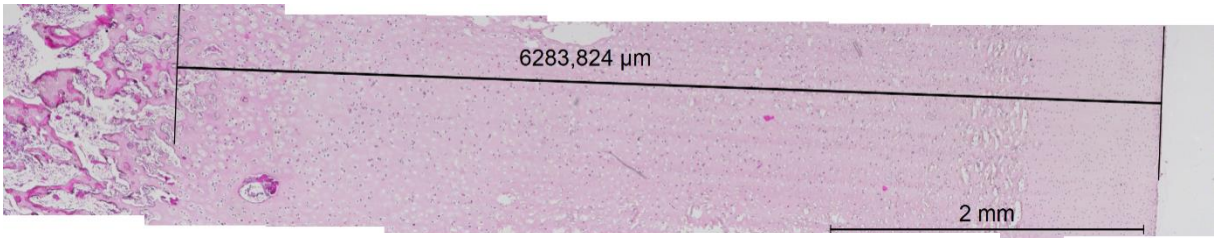

Figure 8: Example of a stitch picture with the measurements of cartilage thickness.

Cell density:
To determine the cellularity (number of cells/mm2) of the juvenile equine cartilage nuclei were counted in several regions of the cartilage. Because of the high range in cartilage thickness, each sample was lengthwise divided into 3 equal sized subregions for orientation: lower region (closely to the bone), the middle region and the top region (close to the articular surface), see figure 9. Dividing the cartilage into these subregions is not described in earlier literature. In this way the subregions could be compared between samples, with the size of each region being proportionally to the total length of the cartilage. To count the nuclei a ImageJ/Fiji macro was used.

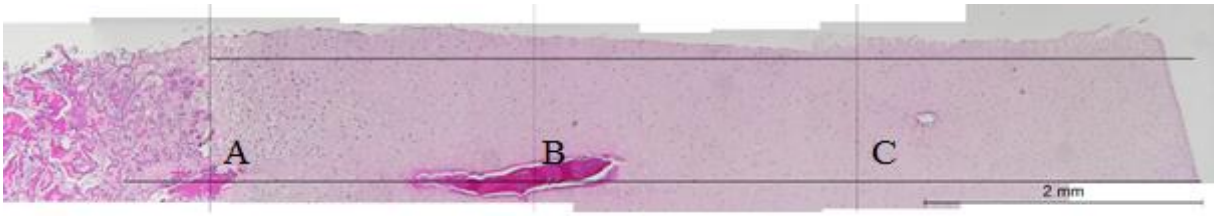

Figure 9: Example of the three sub regions in the stitch image. A) lower subregion B) middle subregion C) top subregion.

In each subregion 4 boxes are selected and imaged (10x magnification) by LAS 4.2. These files are opened in ImageJ and nuclei and cell density (nuclei/mm2) are measured by the macro. The macro for cell count also provides an option to scale the quality of the cell count. Some of the results were therefore marked as poor and excluded. For each section, 4 images (10x magnification) were taken with in each subregion (microscope Olympus color CCD with LAS 4.2 software). In ImageJ these images were analyzed using an ImageJ/Fiji macro for nuclei count and surface area measurement, specifically developed for this tissue. This procedure was performed for all horses except horses 7 and 8. These latter ones were the oldest horses in the study and therefore had a cartilage thickness that was too small to fit 4 images per subregion taken at 10x magnification. To overcome this scaling problem, the protocol was adapted as follows: a manual cell count was performed for the lateral samples of horse 7 and 8. In the medial sample of horse 7 one image is taken in each subregion. In the medial sample of horse 8 there was no possibility to measure values in the middle and lower region, therefor only the values of the top region were collected.

Vascular density
The vascular density (number of blood vessels per mm2) of the cartilage was determined in the stitch images by counting the blood vessels in each subregion and calculating the surface area of the corresponding subregions using ImageJ. Vascular density was calculated for each subregion and for the total section. In cases were the same blood vessel was present in more than one subregion, the vessel was counted in all subregions.

Picrosirius red staining:
Prior to staining the slides where deparaffinized according to the deparaffinization protocol (see appendix). The slides were stained by subsequent incubation in picrosirius red solution (0,1% Sirius Red F3BA in picric acid $C_6H_3N_3O_7$) for 60 minutes, 0,01M HCL for 5 minutes, aquadest for one minute, EtOH 100% for one minute (three times) and xylene for three minutes (twice). Stained sections were evaluated using a microscope (Zeiss Axio Scope) with polarized light filter and Olympus DP25 camera. Polarized light microscopy is a technique to evaluate the collagen structure in the cartilage and is known as the “golden standard of histology” (27)(28). Images were taken at 2,5x; 10x and 20x

magnification and analysis was done using Ce2Il^D software. The samples are individually evaluated, examined parameters were the presence of collagen orientation in the cartilage (parallel, radial, perpendicular or unorganized collagen orientation), presence of different layers and overall quality of birefringence. Sections were examined at the angle that revealed the maximum birefringence of the collagen fibers. Images (2,5x magnification) were taken of the top layer of the cartilage in the horses 1 t/m 11 and 14, both at the medial and lateral condyles. Additionally, images (2,5x; 10x and 20x magnification) were taken of the complete cartilage of the medial femoral condyle of the horses 1,3,6,8,9 and 14, in order to create an overview of collagen distribution at several time points during development. (10 months gestation, 11 days, 28 days, 2months 21 days, 6 months 15 days and 19 years.)

Adult horses:

To compare the cartilage characteristics of foals with mature horses cartilage samples of 4 adult horses were taken along in this study. The adult samples were obtained from the OR-69 study carried out by Malda *et al.* (2013) (16). Four horses were chosen by their low Mankin score, age and weight. The Mankin score is used to score the condition of the cartilage. A Mankin score of 0 indicates a normal structure, normal cells, normal safranin-O staining and an intact tidemark integrity (29). Table 2 shows the adult horses participating in this study.

Table 2: Overview of the adult horses used in this study

Horse	Age	Mankin score	Weight
12	8	0	550
13	19	0	600
14	19	0	600
15	8	0	450

Cartilage thickness was measured in the same way as it is done in the juvenile cartilage. To check the accuracy of the measurements the cartilage thickness measured in this study was compared to the cartilage thickness measured by the study of Malda *et al.* (2013) (16,18). Identical results were obtained. Division of total cartilage area in three subregions and determination of blood vessel density was done in the same way as in the cartilage of foals. Cell count was performed in a slightly different way. The area of the subregions was measured in ImageJ and the cells within this region of interest were counted by hand with the *PickPointer* option in ImageJ.

Statistical analysis

Statistical analysis was performed using SPSS v20. P-values were calculated using 95% confidence intervals. Significance of boxplots was tested using regression analysis corrected for age. When two groups were compared (lateral and medial) and data were normally distributed a paired t-test was used, if data were not normally distributed a Wilcoxon Signed Rank test was used (non-parametric). When three groups were compared (subregions) a repeated measures ANOVA was used. Linear regression analysis with calculation of regression coefficient and slope decline between groups was compared using ANOVA.

Results:

Cartilage thickness:

Table 3 shows the rounded values of cartilage thickness measured in this study. Cartilage thickness varies from 1,24 mm in the lateral condyle of the foal aged 4 months 25 days till 26,12 mm in the medial condyle of the foal aged 18 days.

Table 3: Average cartilage thickness in mm of the lateral and medial femoral condyle. Horses number 12, 13, 14 and 15 are the adult horses examined. The values of the medial condyle from horse number three and four are excluded due to an incorrect stitch picture which made a reliable measurement impossible.

Horse	Age	Cartilage thickness (mm)	
		Lateral	Medial
1	10 months gestation	12,59	22,86
2	10 months gestation	17,85	16,03
3	11 days	12,17	-
4	1 day	12,63	-
5	2 months 3days	7,02	8,77
6	2 months 21 days	6,25	8,95
7	4 months 25days	1,76	1,60
8	6 months 15 days	1,24	1,60
9	28 days	8,00	12,72
10	18 days	12,07	26,13
11	1 day	8,28	17,25
12	8 years	1,31	2,58
13	19 years	1,44	3,47
14	19 years	1,37	2,09
15	8 years	1,44	2,33

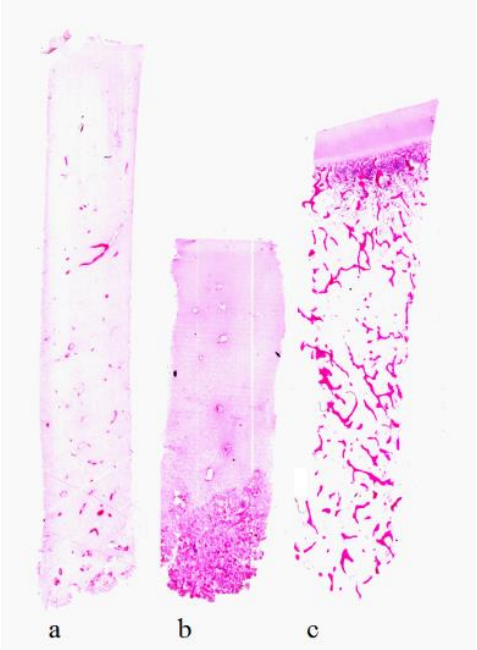

Figure 10: Scans of H&E stained osteochondral sections of the medial condyle of the femur taken from 3 horses at (a) 10 months gestation, (b) 2m21d postpartum and (c) 4m25d postpartum, , illustrating the large differences in cartilage thickness between immature and mature horses.

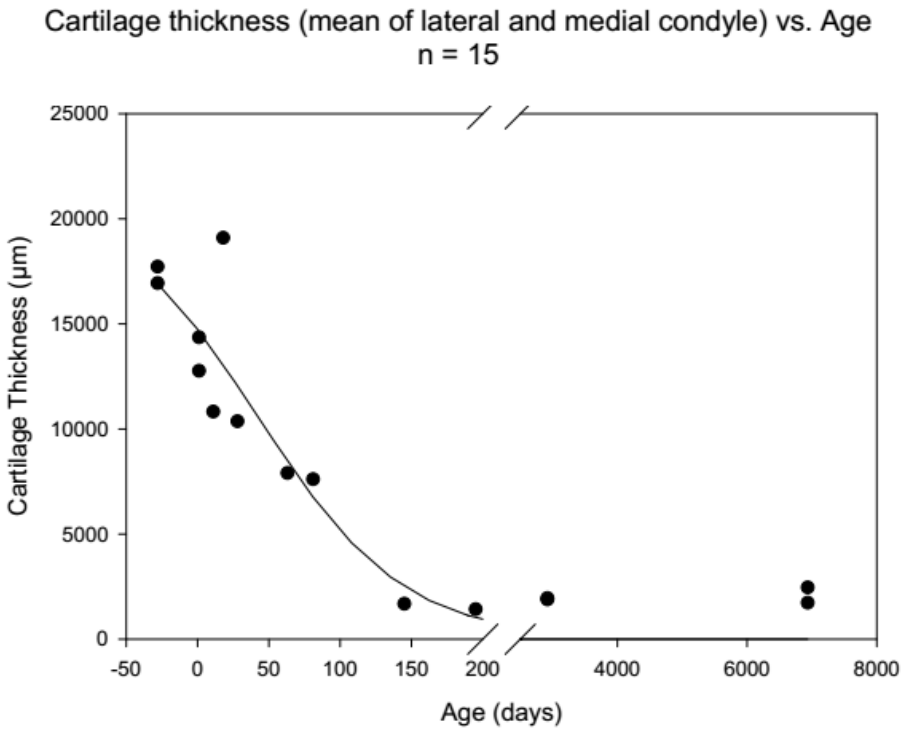

Figure 11: Cartilage thickness measurement in 11 foals and 4 adult horses. X-axis break omits ages between 200 and 2500 days, indicating the separation between foals (< 7 months) and adults (> 8y).Note that the data points for two adults with age 8 years (2920 days) are overlapping. Each data point represents the mean of 6 measurements in one animal: cartilage thickness measured in the lateral condyle (3 measurements) and the medial condyle (3 measurements).

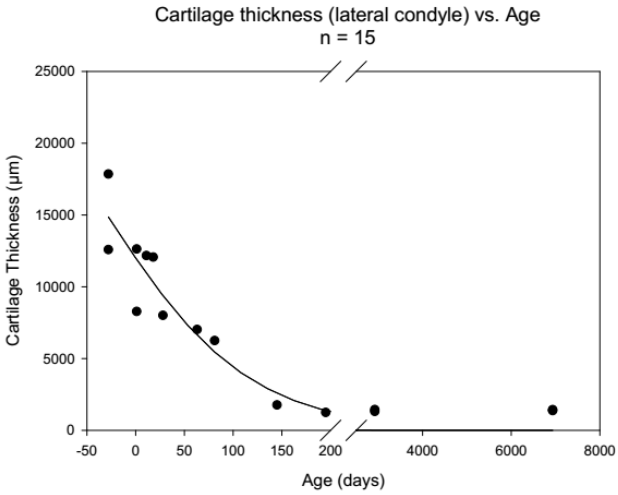

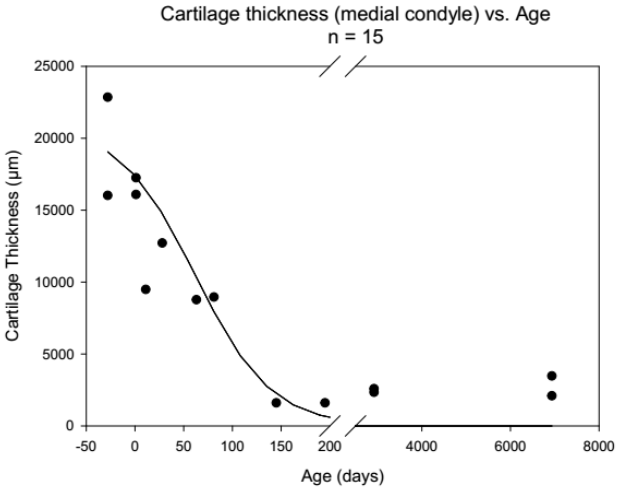

Figure 12 + 13: Cartilage thickness is slightly lower in lateral condyle compared to medial condyle, but both showing a sigmoidal relationship with age. Each data point represents the mean of 3 measurements in one animal.

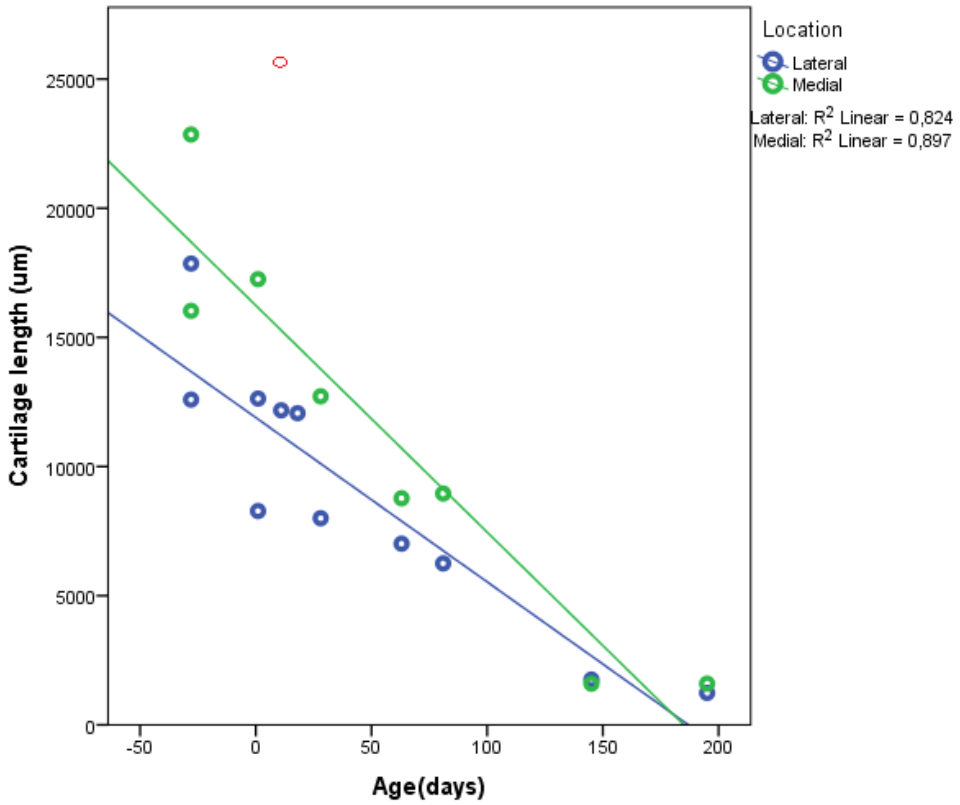

Figure 14: Equine cartilage thickness decreases during development in lateral (n=11) and medial (n=8) condyles. Red dot represents medial outlier. Lateral R^2=0,824. Medial R^2=0, 897. Age range (10 months gestation-6m15d) The cartilage thickness in the medial condyle decreases significantly faster compared to the lateral condyle when the outlier is excluded. (p<0,033)

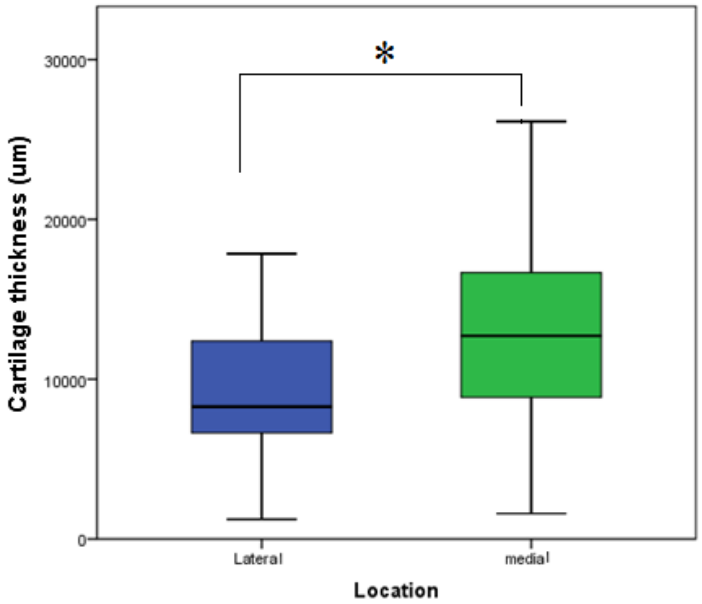

Figure 15: Boxplot showing the distribution of cartilage thickness at two locations (lateral n=11 and medial n=9) of the femoral condyle (10 months gestation-6m15d). Cartilage thickness is significantly higher at the medial condyle (p<0,0396). The box indicates the 25th-75th interquartile range (IQR) with the bold horizontal line as the median of all measurements; whiskers represent minimum and maximal values of the data set.

Vascular density

Table 4: Blood vessel density of cartilage decreases during development in medial and lateral femoral condyles. Values represent the sum of total counts in all three subregions.

Horse	Age	Average amount of blood vessels/mm2	
		Lat	Med
1	10 months gestation	1,0281	0,8015
2	10 months gestation	0,6523	0,5906
3	11 days	0,9040	0,9033
4	1 day	0,2803	0,7034
5	2 months 3days	0,6525	0,4521
6	2 months 21 days	0,1332	0,6790
7	4 months 25days	0	0
8	6 months 15 days	0	0
9	28 days	0	0,4071
10	18 days	0,6048	0,4071
11	1 day	1,4014	0,4344
12	8 years	0	0
13	19 years	0	0
14	19 years	0	0
15	8 years	0	0

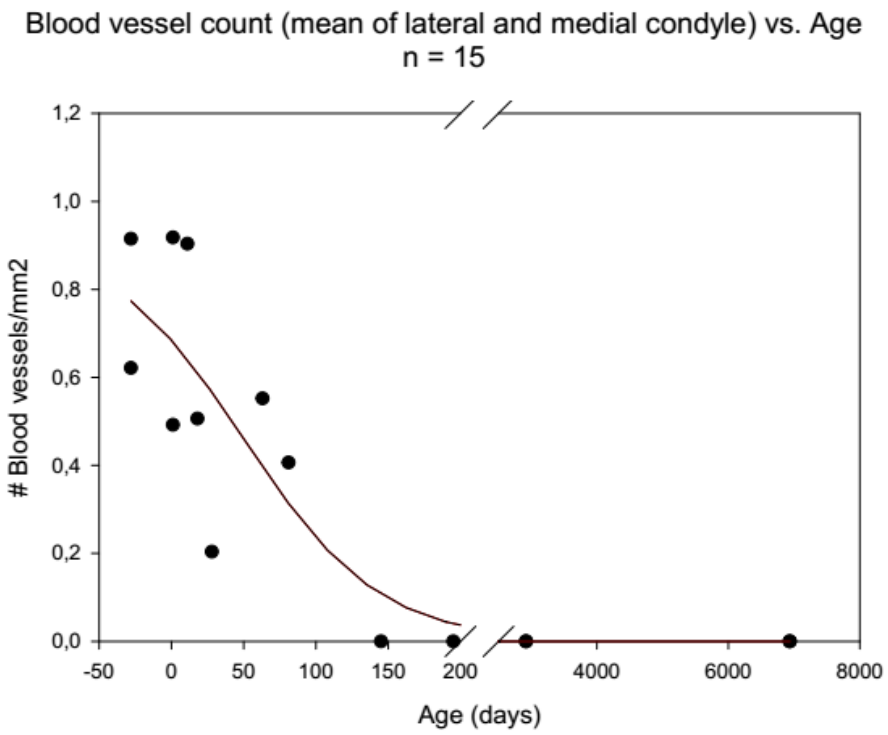

Figure 16: Number of blood vessels per square mm measured in 11 foals and 4 adult horses. X-axis break omits ages between 200 and 2500 days, indicating the separation between foals (< 7 months) and adults (> 8y). Note that the data points for two adults with age 8 years (2920 days) and two adults with age 19 years (6935 days) are overlapping. Each data point represents the mean of 6 measurements in one animal: number of blood vessels counted per mm2 in the lateral condyle (3 measurements) and the medial condyle (3 measurements).

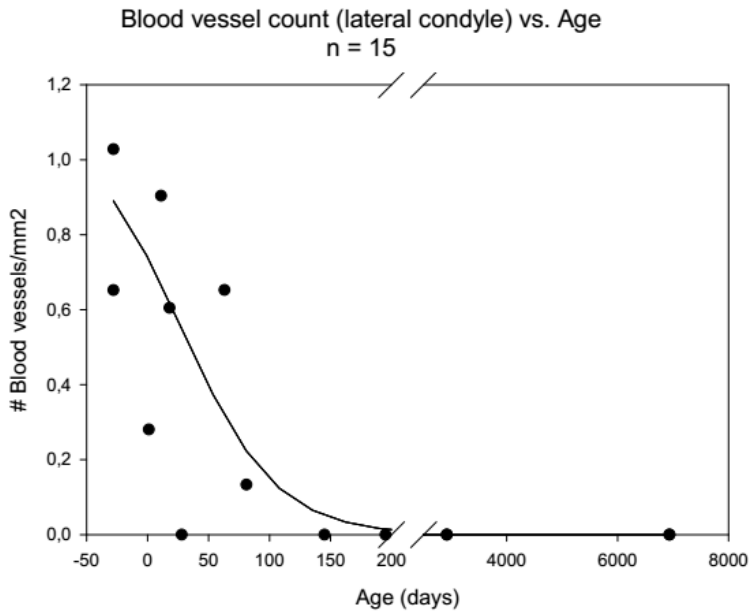

Figure 17: Vascularity is more random in the lateral condyle compared to the medial condyle, only showing a sigmoidal relationship in the lateral condyle. Figure shows the relation between vascularity and age in the lateral femoral condyle.

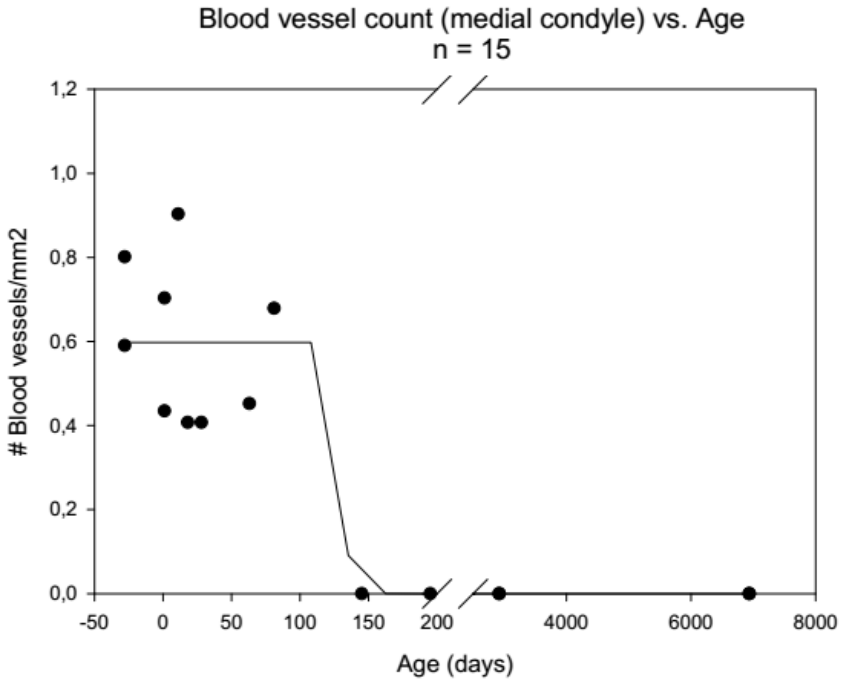

Figure 18: Vascularity is more random in the lateral condyle compared to the medial condyle, only showing a sigmoidal relationship in the lateral condyle. Figure shows the relation between vascularity and age in the medial femoral condyle.

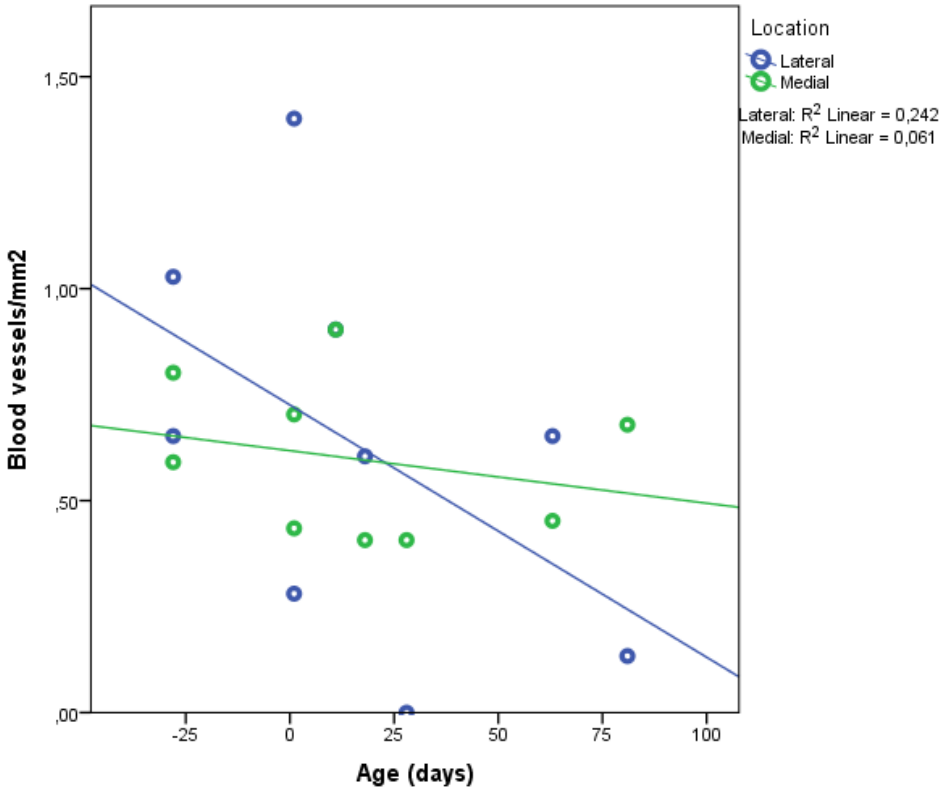

Figure 19: Scatterplot showing the relation between blood vessels/mm2 and age. No significant difference could be found, correlation is weak/absent. Linear lines for the medial values (n=9) en the blue values (n=9). Horses 7+8 are excluded in this figure due to their 0 values Lateral: R^2=0,242 Medial: R^2=0,061.

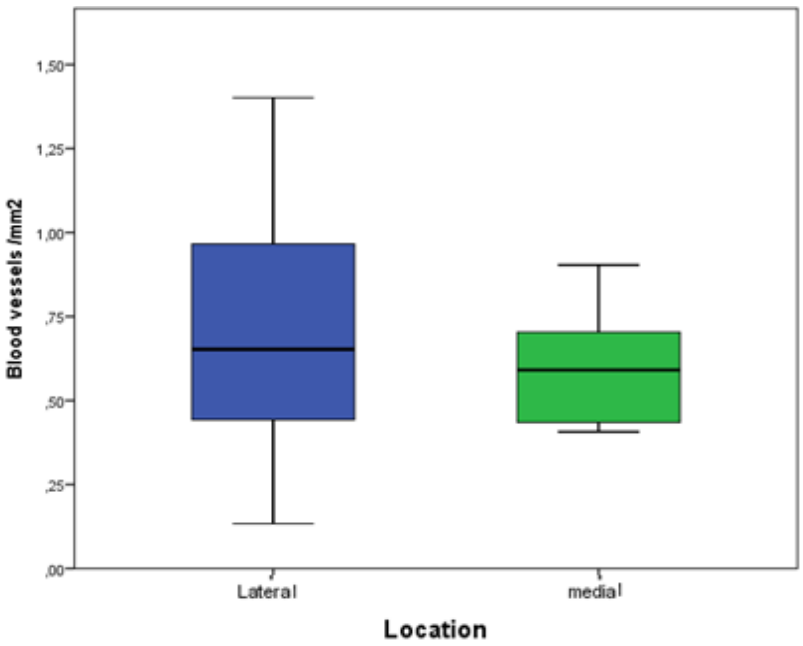

Figure 20: Boxplot showing blood vessel density (vessels/mm2) at two locations (medial and lateral) of the femoral condyle. Horses 7+8 are excluded in this figure due to their 0 values. Each plot includes 9 measurements (vessel density in horse 1 t/m 6 + 9,10 and 11; age range: 10 months gestation - 2m21d). The box indicates the 25th-75th interquartile range (IQR) with the bold horizontal line as the median of all measurements; whiskers represent minimum and maximal values of the data set. No significance difference between the two locations could be found.

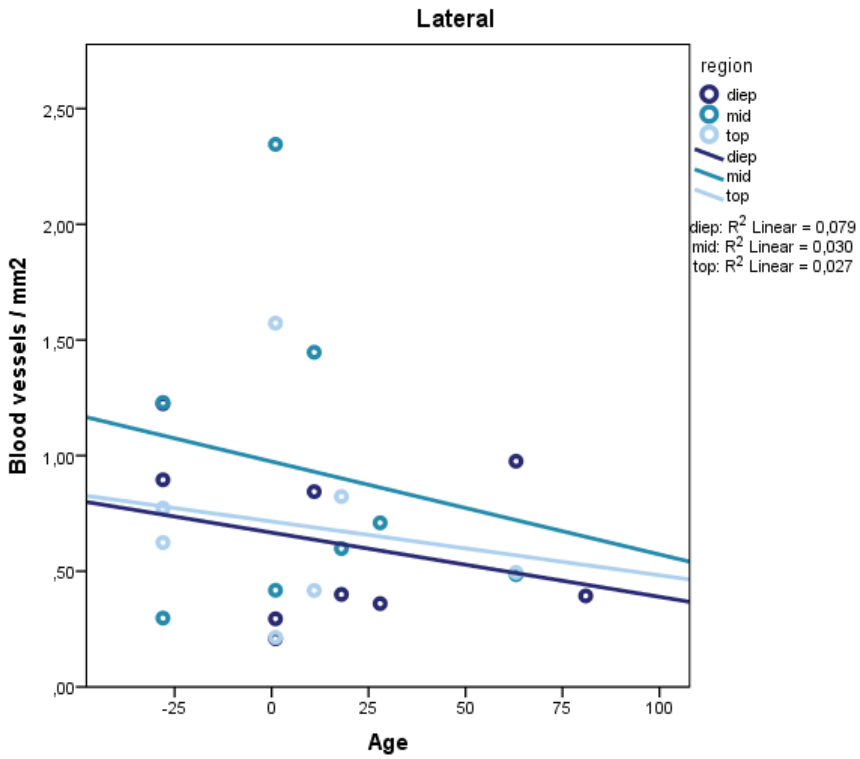

Figure 21: The blood vessels / mm2 in the different subregions of the lateral condyle related to age, showing no significant difference in decrease of the vessels between the different subregions. Horses 7+8 are excluded in this figure due to their 0 values. Deep subregion R^2=0,079, middle subregion: R^2=0,030 and top subregion R^2= 0,027.

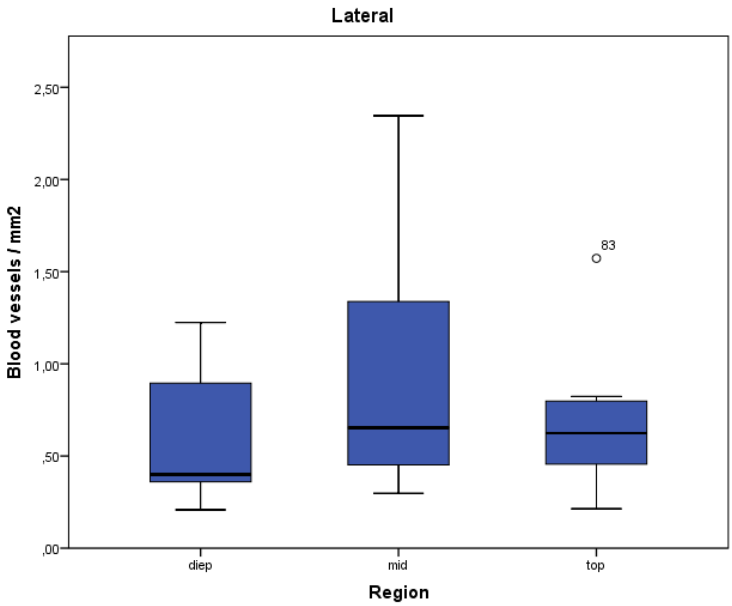

Figure 22: Boxplot showing blood vessel density (vessels/mm2) in the different subregions at the lateral femoral condyle, showing no significant differences in vessel density between the different subregions. Horses 7+8 are excluded in this figure due to their 0 values. Each plot includes 9 measurements (vessel density in horse 1 t/m 6 + 9,10 and 11; age range: 10 months gestation - 2m21d). The box indicates the 25th-75th interquartile range (IQR) with the bold horizontal line as the median of all measurements; whiskers represent minimum and maximal values of the data set. Outlier indicated as single value.

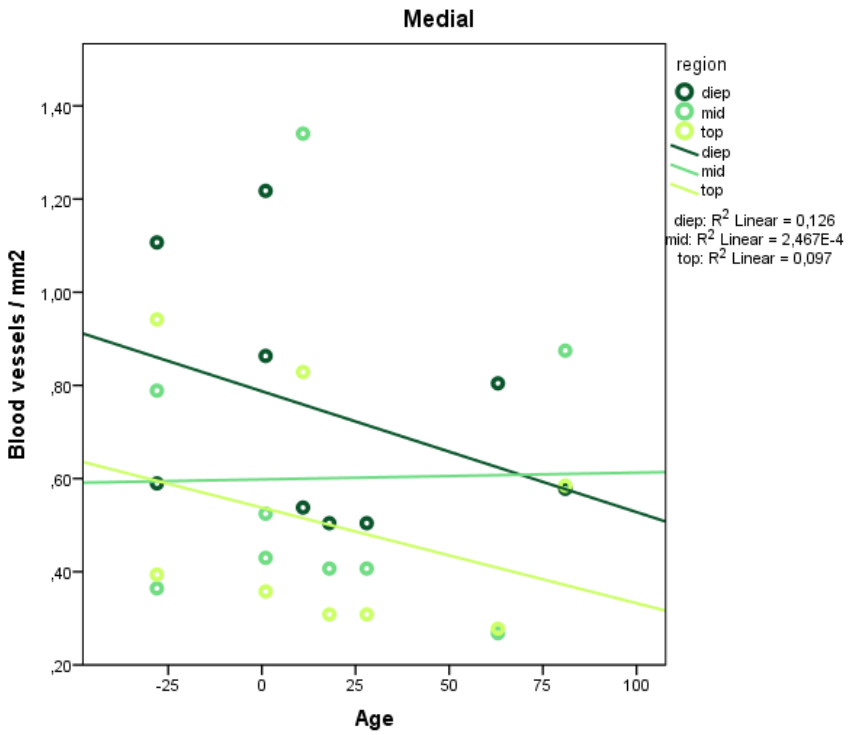

Figure 23: Blood vessel density (vessels/mm2) in the different subregions of the medial condyle related to age. No significant difference between the subregions could be found, correlation is weak/absent. Deep subregion R^2=0,126, middle subregion: R^2=2,467E-4 and top subregion R^2= 0,097. Horses 7+8 are excluded in this figure due to their 0 values.

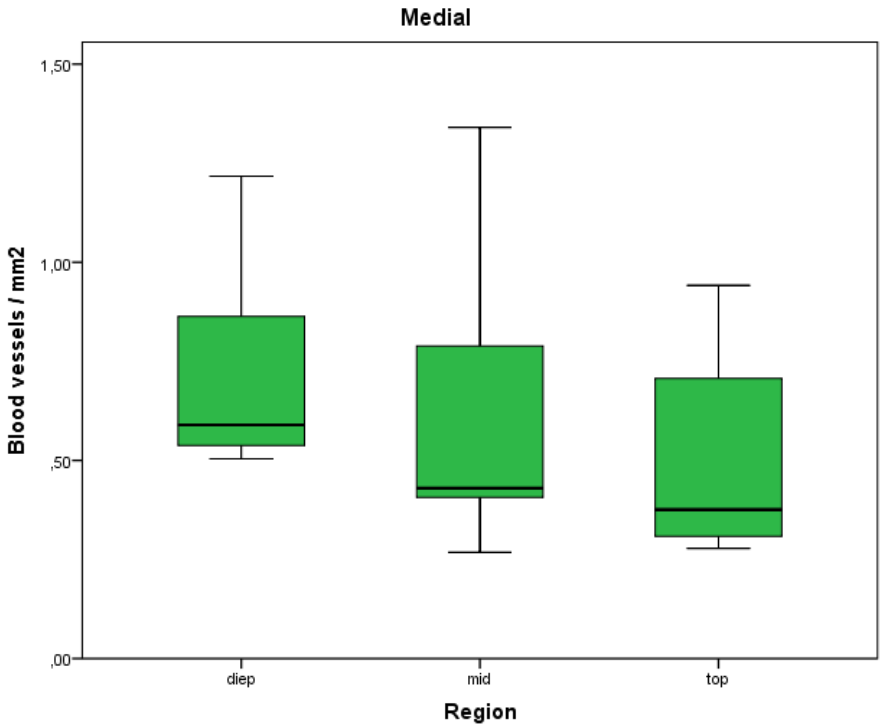

Figure 24: Boxplot showing blood vessel density (vessels/mm2) in the different subregions at the medial femoral condyle. Vessel density shows to be highest in the subregion close to the bone and seems to decrease when moving to the top subregion, however, no significant difference could be found between the different subregions. Horses 7+8 are excluded in this figure due to their 0 values. Each plot includes 9 measurements (vessel density in horse 1 t/m 6 + 9,10 and 11; age range: 10 months gestation - 2m21d). The box indicates the 25th-75th interquartile range (IQR) with the bold horizontal line as the median of all measurements; whiskers represent minimum and maximal values of the data set.

Cell density:

Table 5: In addition to the horse number and age of the horses this table shows the average amount of cells/mm2 in the total sample of either the lateral or medial site. Horse number 13, 14 and 15 are the adult horses examined, in horse 12 a reliable cell count was impossible.*
**Total includes the three subregions.*

Horse	Age	Average amount of cells/mm2	
		Lat	Med
1	10 months gestation	910,2067	840,2240
2	10 months gestation	720,2842	1903,7468
3	11 days	804,6942	583,7640
4	1 day	933,2472	670,1120
5	2 months 3days	636,7356	665,3747
6	2 months 21 days	571,9208	487,5107
7	4 months 25days	1103,3592	581,2636
8	6 months 15 days	-	324,8830
9	28 days	709,7992	609,3885
10	18 days	1224,3755	752,5840
11	1 day	948,7511	689,4910
12	8 years	-	-
13	19 years	164,622	129,336
14	19 years	201,585	174,6567
15	8 years	183,455	259,6553

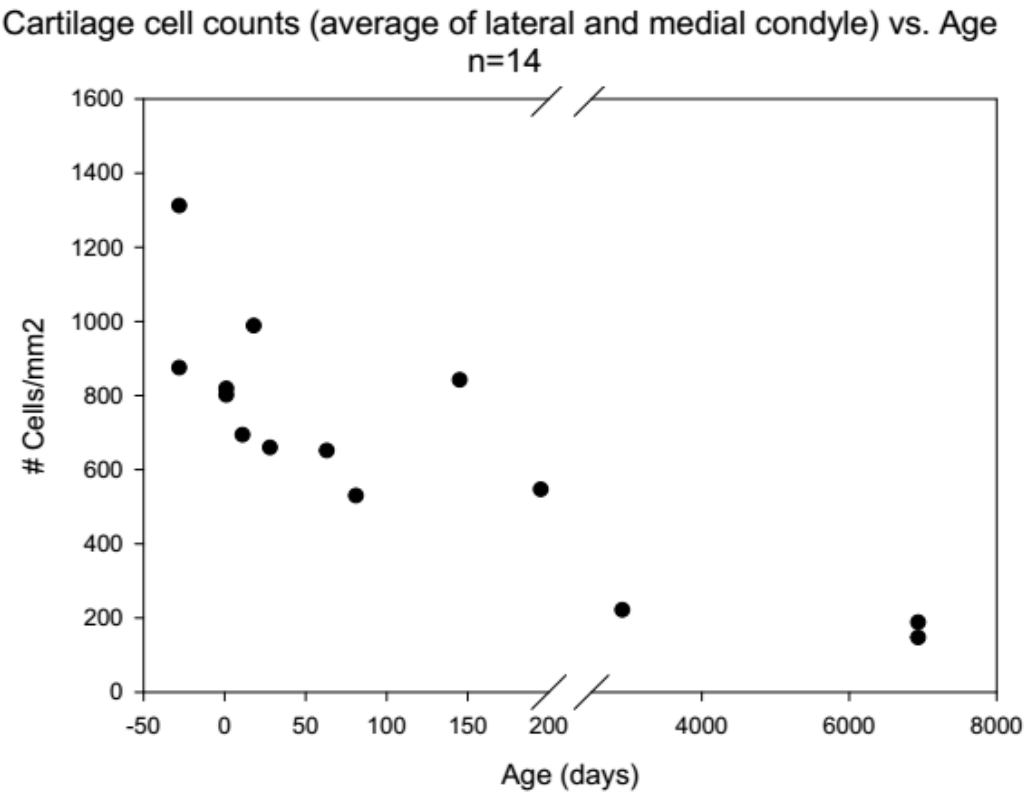

Figure 25: Number of cells per square mm measured in 11 foals and 3 adult horses. X-axis break omits ages between 200 and 2500 days, indicating the separation between foals (< 7 months) and adults (> 8y). Each data point represents the mean of 6 measurements in one animal: number of cells counted per mm2 in the lateral condyle (3 measurements) and the medial condyle (3 measurements).

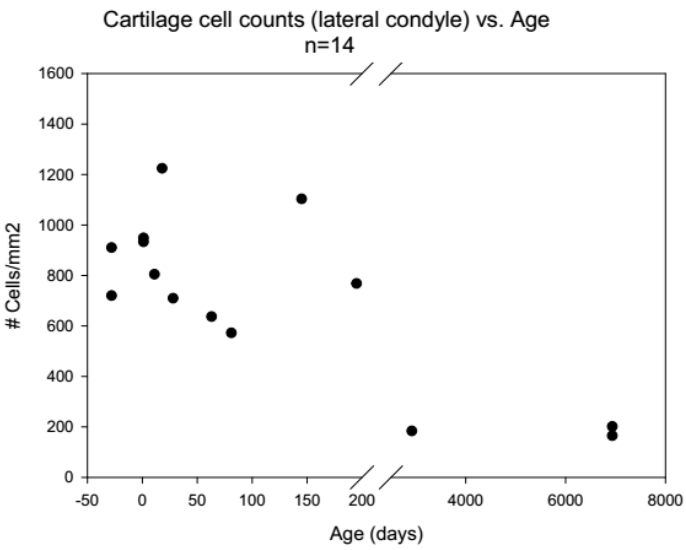

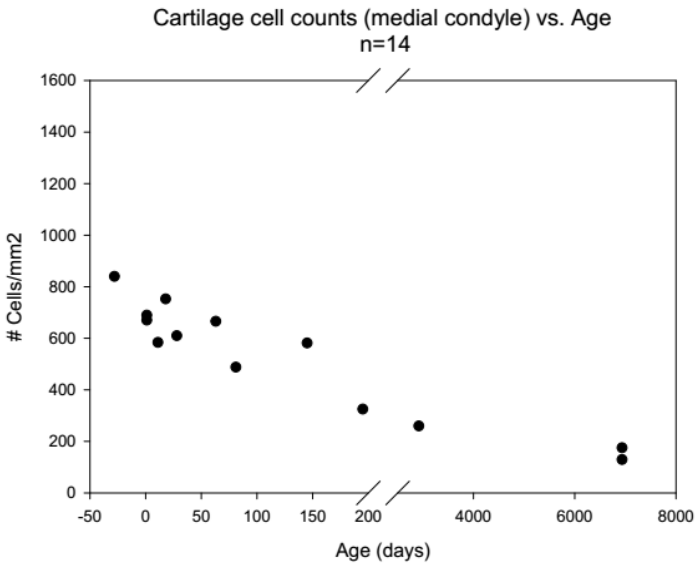

Figure 26 a+b: Cellularity is slightly higher in cartilage of the lateral condyle (a) compared to the medial condyle (b), also showing a larger variation in the data.

Note:

For statistical analysis logarithmic conversion (natural logarithm) was performed because data were not normally distributed (see appendix figure 1 and 2). On the normalized data a linear regression was performed with average amount of cells as dependent variable and location, subregion and age as independent variables. Graphs in figure 27 t/m 32 contain a "ln cells/mm2" value on the y-axis instead of "#Cells/mm2" value which was presented on the y-axis of figure 25 and 26 a + b.

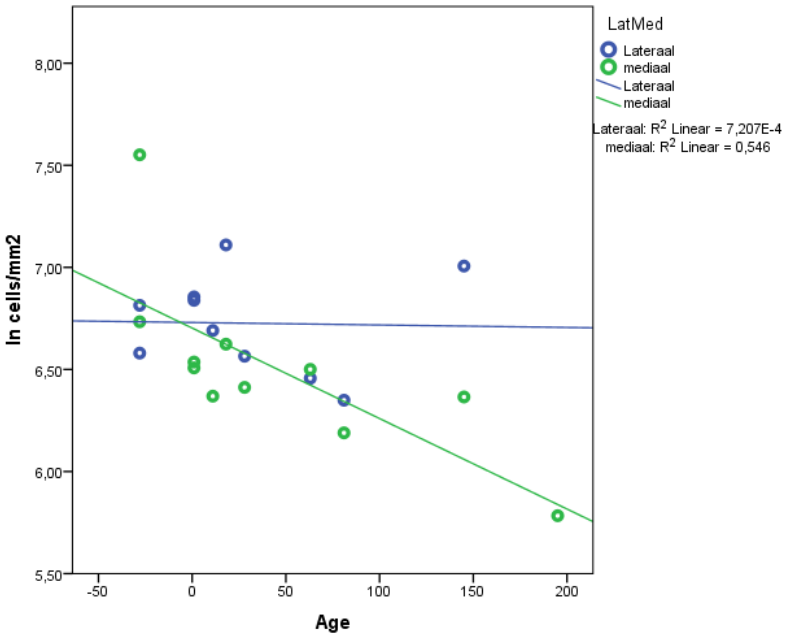

Figure 27: Natural logarithm of the average amount of cells/mm2 in the total sample from both the lateral (n=10) and medial (n=11) condyle related to age. Lateral R^2=7,207E-4 Medial R^2=0,546. Lateral no correlation can be found, medial a slight decrease during maturation can be found.

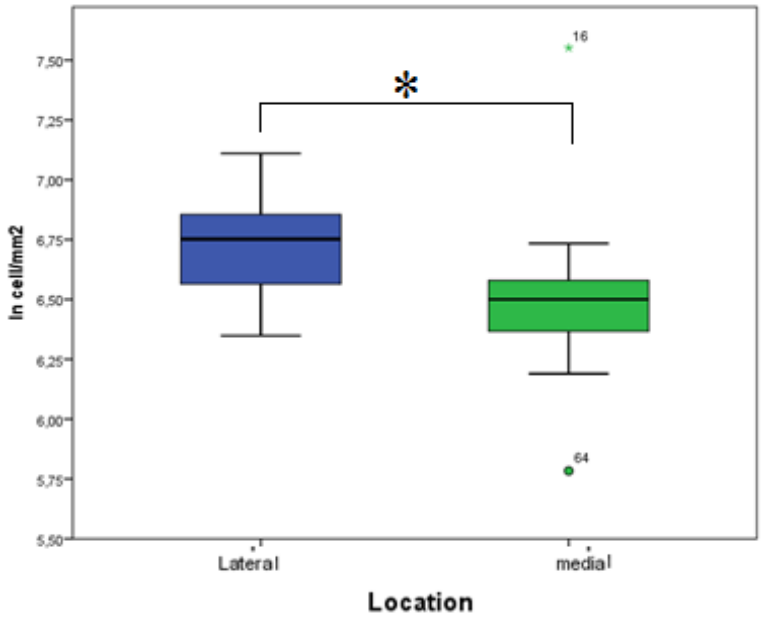

Figure 28: Boxplot showing the distribution of natural logarithm of the average amount of cells/mm2 in the different locations. Lateral plot includes 10 measurements. Medial plot includes 11 measurements (10 months gestation-6m15d). The box indicates the 25th-75th interquartile range (IQR) with the bold horizontal line as the median of all measurements; whiskers represent minimum and maximal values of the data set. Outliers are presented as single values. A significant difference between the cell density in the medial and lateral femoral condyle (p<0,026) can be found if outliers are excluded, even when corrected for age. Cell density in the lateral femoral condyle turned out to be significantly higher.

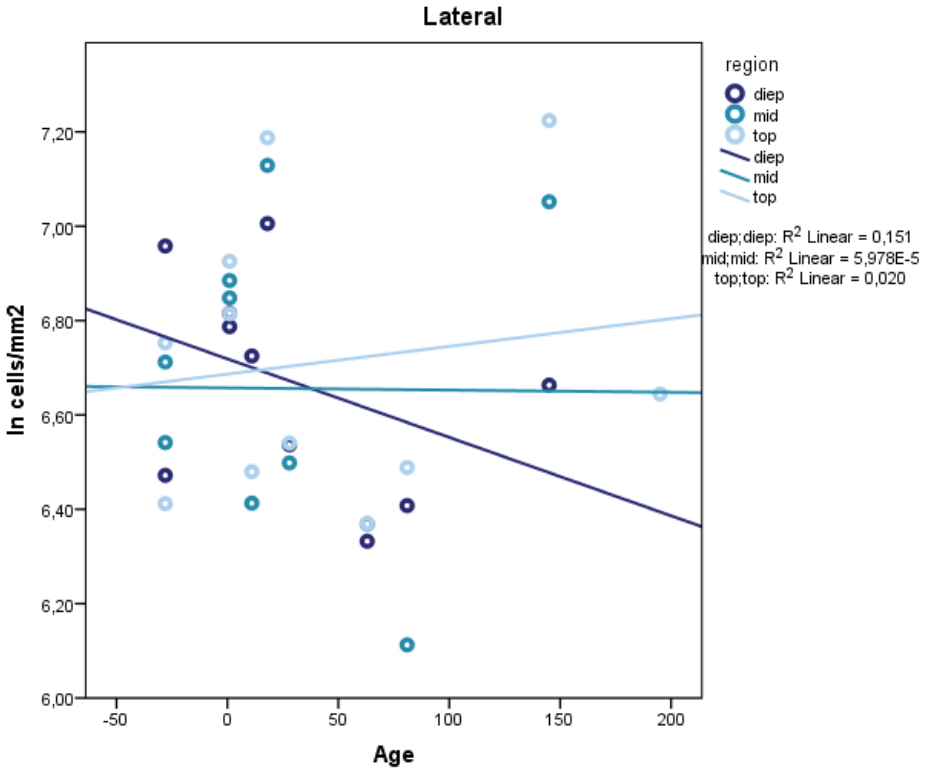

Figure 29: Natural logarithm of the average amount of cells/mm2 in the different subregions from the lateral condyle related to age. No significant difference between the subregions could be found, correlation is weak/absent. Deep subregion R^2=0,151, Middle subregion R^2=5,978E-5, top subregion R^2=0,020.

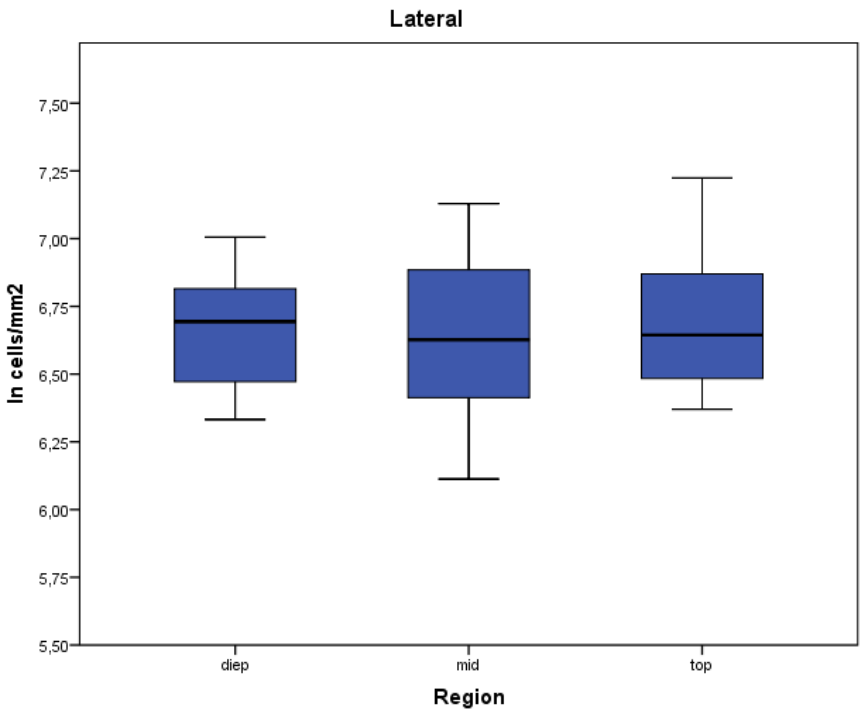

Figure 30: Boxplot showing the distribution of the natural logarithm of the average cells/mm2in the different subregions at the lateral femoral condyle, no significant differences can be found between the different subregions. Each plot includes average measurements (of 4 single measurements) for 10 animals (age range 10 months gestation-4m25d). The box indicates the 25th-75th interquartile range (IQR) with the bold horizontal line as the median of all measurements; whiskers represent minimum and maximal values of the data set.

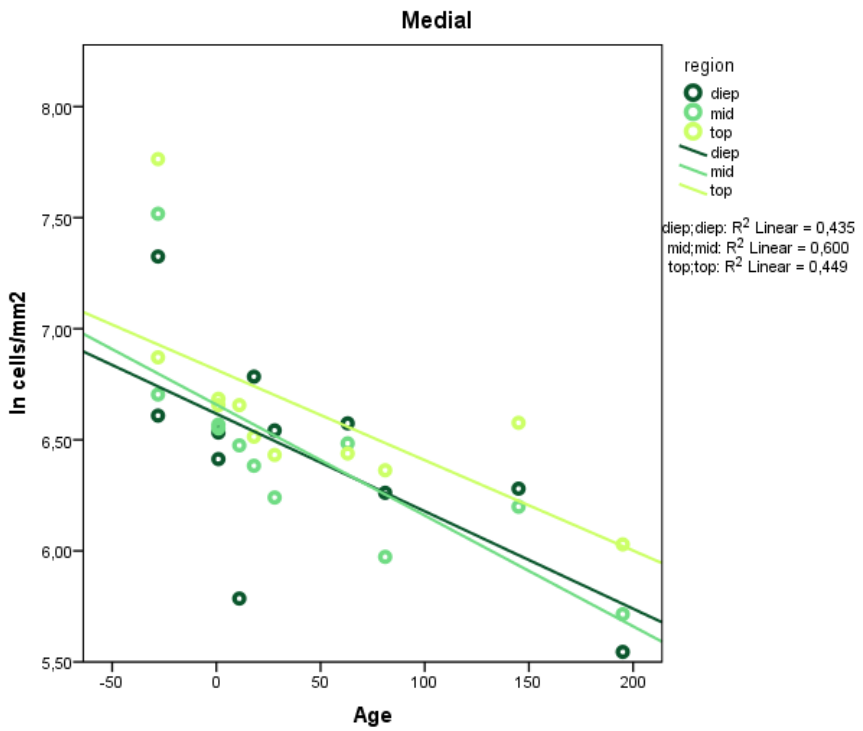

Figure 31: Natural logarithm of the average amount of cells/mm2 in the subregions from the medial condyle related to age. Deep zone R^2=0,435, Middle zone R^2=0,600, Top zone R^2=0,449. Cell density decreases with age at the medial femoral condyle, but no significant difference between the different subregions can be found.

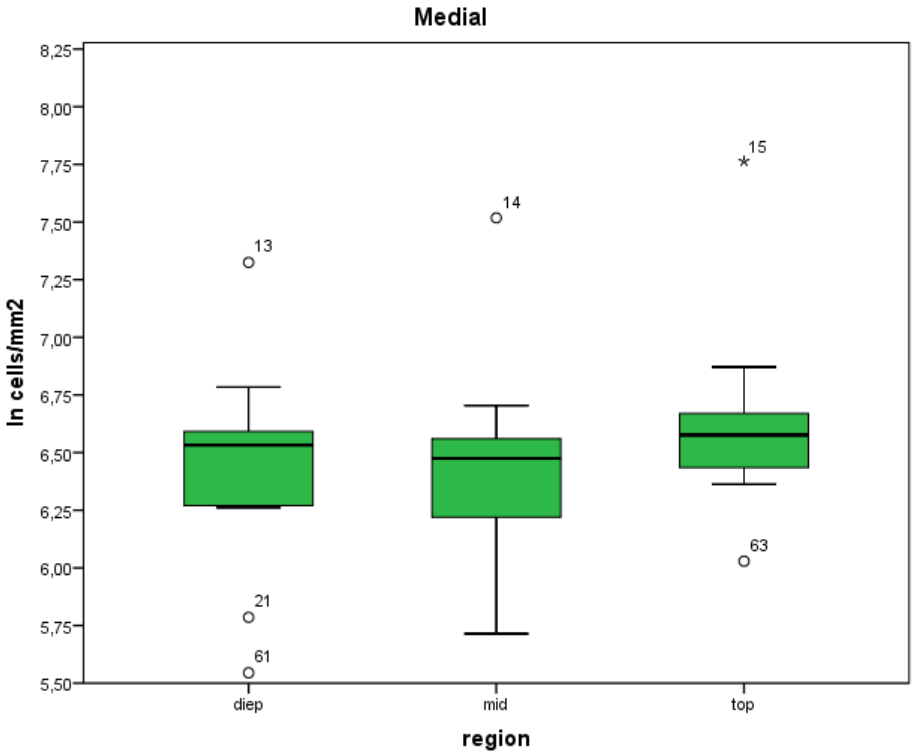

Figure 32: Boxplot showing the distribution of the natural logarithm of the average cells/mm2in the different subregions at the medial femoral condyle, no significant differences can be found between the different subregions. Each plot includes average measurements (of 4 single measurements) for 11 animals (age range 10 months gestation- 6m15d). The box indicates the 25th-75th interquartile range (IQR) with the bold horizontal line as the median of all measurements; whiskers represent minimum and maximal values of the data set.

Collagen orientation:

For all the foals (horse 1 t/m 11) and one adult horse (horse 14) the upper part of the cartilage of the lateral femoral condyle is shown in figure 33 and the upper part of the cartilage of the medial condyle is shown in figure 34. For foals 1,3,6 and 9 two figures are shown per animal: 1) an overview of the entire section of the osteochondral plug (figures 35, 37, 39, 41, 43, 44), and 2) a zoom on the upper part of the cartilage (figures 36, 38, 40, 42). For the horses 8 and 14 one figure is shown which includes both an overview of the entire section of the osteochondral plug and a zoom on the upper part of the cartilage.

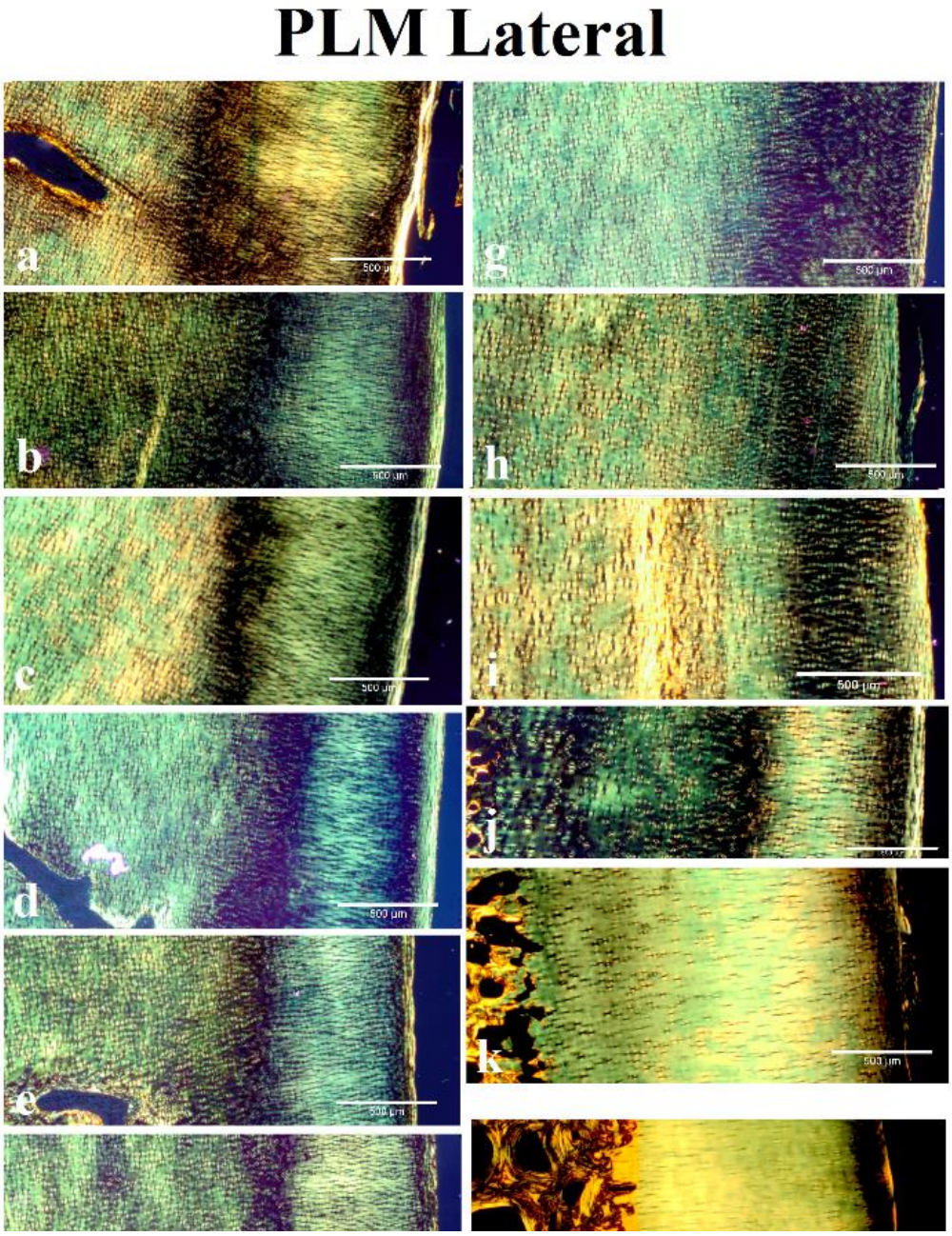

Figure 33: Collagen orientation shown in picrosirius red stained sections of the lateral side of the femoral condyle, 2,5 x magnification, visualized with PLM. Scale bar = 500µm. a= Horse 1, age: 10m gestation. b=Horse 2, age: 10 months gestation. c=Horse 4, age: 1d. d=Horse 11, age: 1d. e=Horse 3, age: 11d. f= Horse 10, age: 18d. g= Horse 9, age: 28 d. h= Horse 5, age: 2m3d. I = Horse 6, age: 2m21d. j= Horse 7, age: 4m15d. k=Horse 8, age: 6m25d. l= Adult horse 14 age 19 years.

PLM Medial



Figure 34: Collagen orientation shown in picrosirius red stained sections of the medial side of the femoral condyle, 2,5 x magnification, visualized with PLM. Scale bar = 500µm. a= Horse 1, age: 10m gestation. b=Horse 2, age: 10 months gestation. c=Horse 4, age: 1d. d=Horse 11, age: 1d. e=Horse 3, age: 11d. f= Horse 10, age: 18d. g= Horse 9, age: 28 d. h= Horse 5, age: 2m3d. i= Horse 6, age: 2m21d. j= Horse 7, age: 4m15d. k=Horse 8, age: 6m25d. l= Adult horse 14 age 19 years.

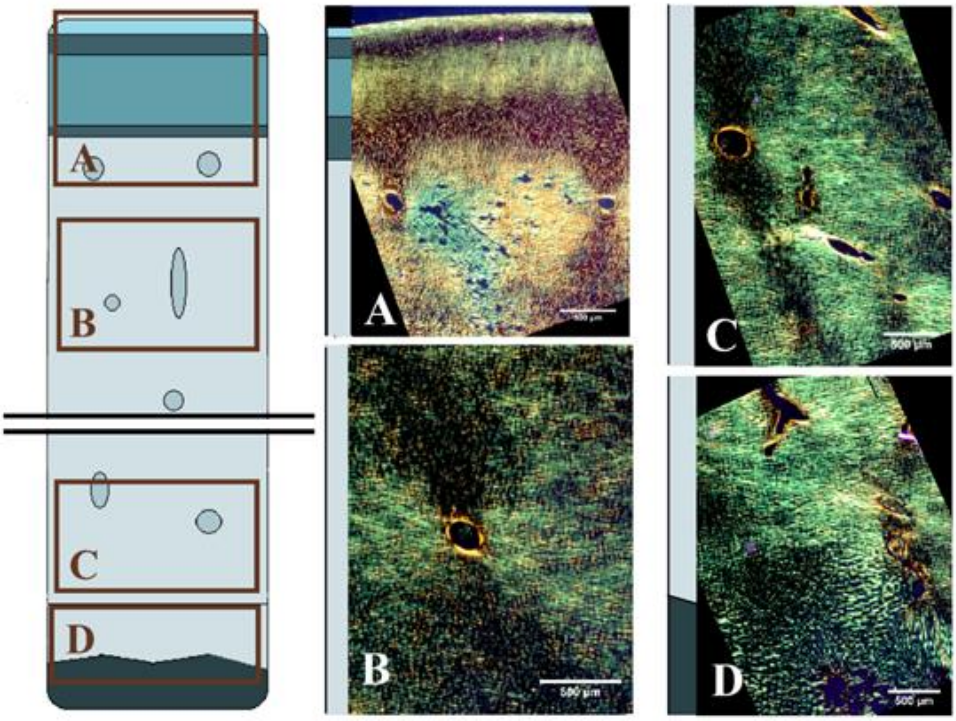

Figure 35: Overview of collagen orientation (picrosirius red staining with PLM) of the medial femoral condyle of horse 1, age: 10m. gestation. Illustration on the left is a representation of the total sample. Note that the size of the illustration is not in proportion to the real size of the sample (gap between the two black lines represents the largest piece of the growth cartilage layer). PLM images correspond to boxes in the illustration on the left. Colours in the illustration correspond to the colour bar next to the images. 2,5x magnification, scale bar = 500 µm. A) Top of the cartilage, different layers can be distinguished. In the first layer the orientation of the collagen fibres is parallel to the surface (superficial layer). In the second layer no predominant orientation is present (transitional layer). In the third layer the orientation of the collagen fibres is perpendicular to the articular surface (deep layer). The fourth layer lacks predominant collagen orientation and is the transition zone between the AC and growth cartilage. In the last zone the growth cartilage is visible. B) Cartilage canal deeper in the growth cartilage. C) several cartilage canals in the lower part of the cartilage. D) Cartilage close to the bone/cartilage transition.

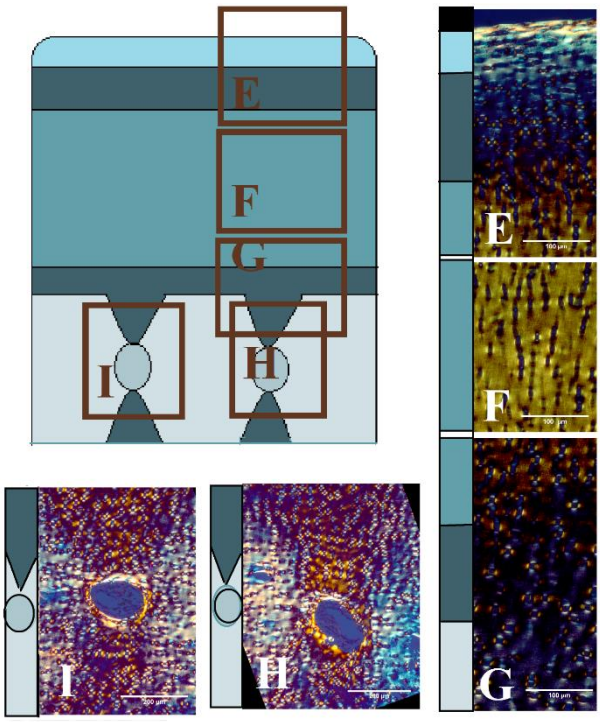

Figure 36: Zoom on collagen orientation (picrosirius red staining with PLM) of the top layer of the medial femoral condyle of horse 1 , age: 10m. gestation. Illustration on the top left shows a representation of the top of the sample. PLM images correspond to boxes in the illustration on the left. Colours in the illustration correspondend to the colour bar next to the images. E/F/G 20x magnification, scale bar = 100 µm. H/I 10x magnification, scale bar = 200 µm E)Top of the articular cartilage. In the first layer (superficial layer)the orientation of the collagen fibres is parallel to the surface. In the second layer (transitional layer)no predominant orientation is present. In the third layer (deep layer) the orientation of the collagen fibres is perpendicular to the articular surface. F) The third zone (deep layer) in which the orientation is clearly perpendicular to the surface. G) In this picture still three different layers are present. First the perpendicular layer (deep layer) is still visible, second there is another layer which lacks a dominant orientation. Transition zone between the AC en growth cartilage. The last layer is the beginning of the growth cartilage. I) and H) Zoom on blood vessel directly under the AC.

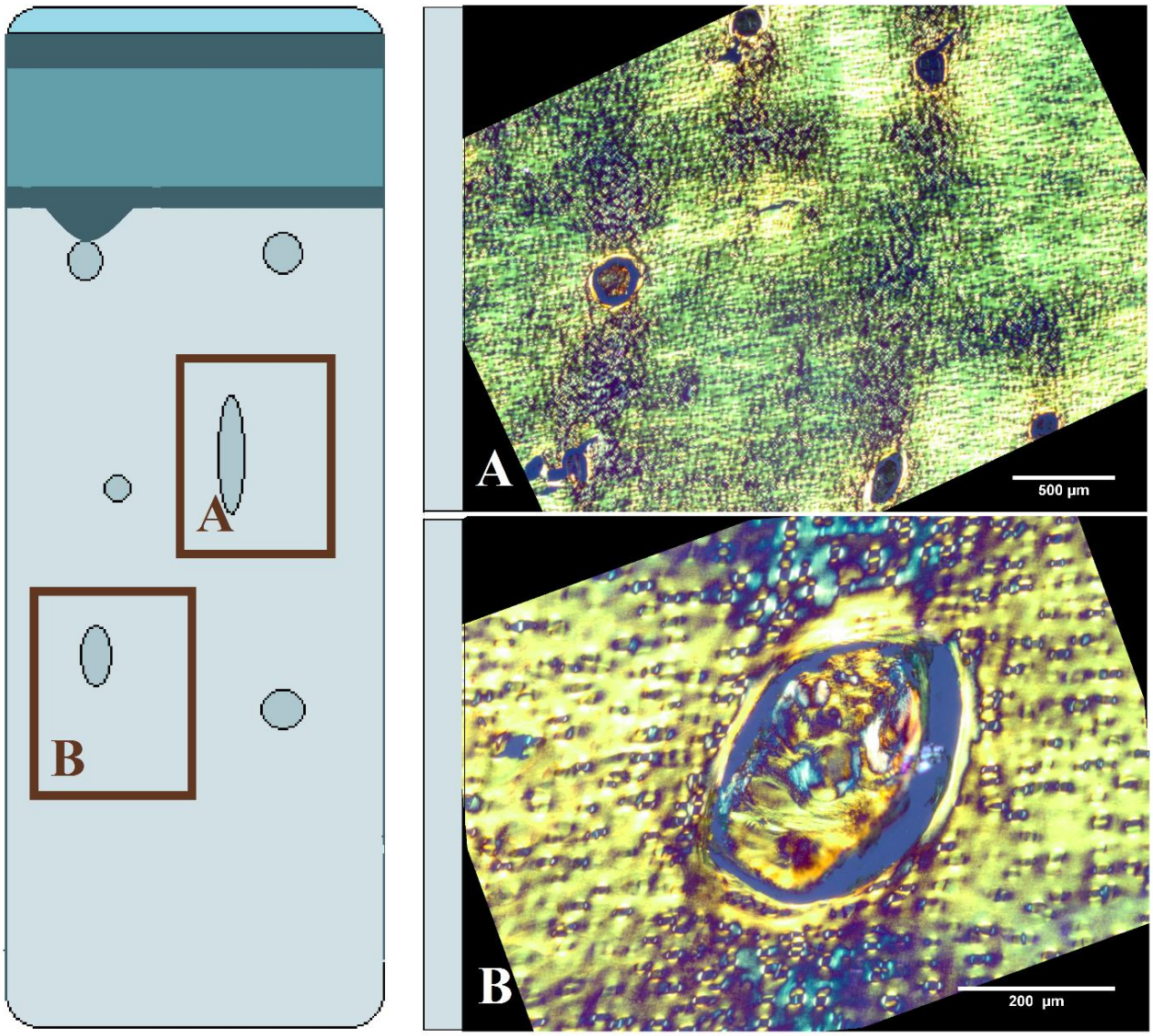

Figure 37: Overview of collagen orientation (picrosirius red staining with PLM) of the medial femoral condyle of horse 3, age: 11days. Illustration on the left shows the complete sample. PLM images correspond to boxes in the illustration on the left. Colours in the illustration correspondend with the colour bar next to the images. A) 2,5x magnification, scale bar = 500 µm. Several cartilage canals can be seen in the growth cartilage directly under the articular cartilage. Note the disorganized collagen orientation around and in between the cartilage canals. B) 10x magnification, scale bar= 200 µm. Cartilage canal in the middle of the growth cartilage with surrounding collagen fibres with different orientation.

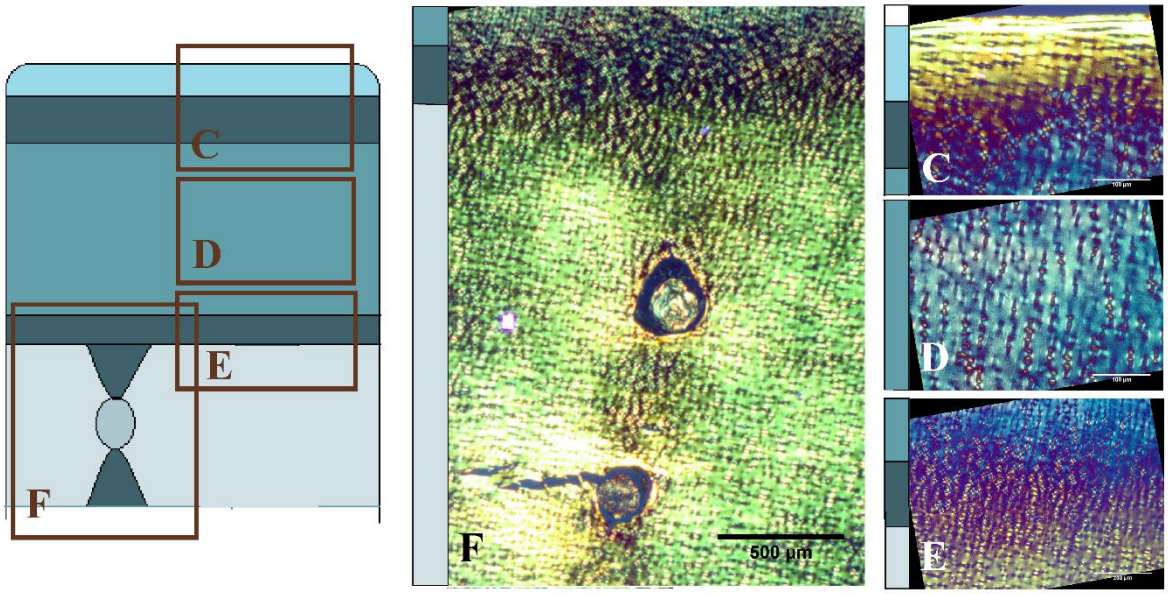

Figure 38: Zoom on collagen orientation (picrosirius red staining with PLM) of the upper part of the cartilage of the medial femoral condyle of horse 3, age: 11 days. Illustration on the left shows a representation of the sample. PLM images correspond to boxes in the illustration on the left. Colours in the illustration correspondend to the colour bar next to the images. C) 20x magnification, scale bar= 100 µm. First layer is the superficial layer, the orientation of the collagen fibres is parallel to the surface. In the second layer (transitional layer) a predominant orientation is absent. in the third layer (deep layer) the orientation of the collagen fibres is perpendicular to the articular surface. D) 20x magnification, scale bar= 100 µm. Deep layer in which the orientation is clearly perpendicular to the surface. E) 10x magnification, scale bar= 200 µm In this picture still three different layers are present. First the perpendicular layer (deep layer) is visible, second there is another layer which lacks a dominant orientation (second transitional layer). The last layer is the beginning of the growth cartilage.



Fig 39: Overview of collagen orientation (picrosirius red staining with PLM) of the medial femoral condyle of horse 9, age: 28 days. Illustration on the left shows the complete sample. PLM images correspond to boxes in the illustration on the left. Colours in the illustration correspondent to the colour bar next to the images. A/B/C/E 10x magnification, scale bar = 200 µm. D/F 2,5x magnification, scale bar = 500 µm. The growth cartilage consist of well-organized areas interspersed with unorganized or less structured areas which gradually become more structured during development. Blood vessels are partly surrounded by a less structured area, the older the foal the more structured the surrounding of the vessels becomes (see figures of older horses). A) Collagen orientation in the top of the growth cartilage. B) Collagen orientation in the middle of the growth cartilage. C) Collagen orientation in the lower region of the growth cartilage. D) Cartilage canals directly under the articular cartilage. E) Cartilage canal and surrounding collagen orientation. Fa) Bone/cartilage transition.



Figure 40: *Zoom on collagen orientation (picrosirius red staining with PLM) of the upper part of the cartilage from the medial femoral condyle of horse 9, age: 28 days. Illustration on the left shows the upper part of the sample. PLM images correspond to boxes in the illustration on the left. 20x magnification, scale bar = 100 µm. F) Top of the articular cartilage. In the first layer (superficial layer) the orientation of the collagen fibres is parallel to the surface. In the second layer (transitional layer) a predominant orientation is not present and in the third layer (deep layer) the orientation of the collagen fibres is perpendicular to the articular surface. G) The third layer (deep layer) in which the orientation is clearly perpendicular to the surface. H) In this picture still three different layers are present. First layer is the perpendicular layer (deep layer), second there is a layer which lacks an dominant orientation (second transitional layer, between the AC and growth cartilage). The last layer is the beginning of the growth cartilage.*

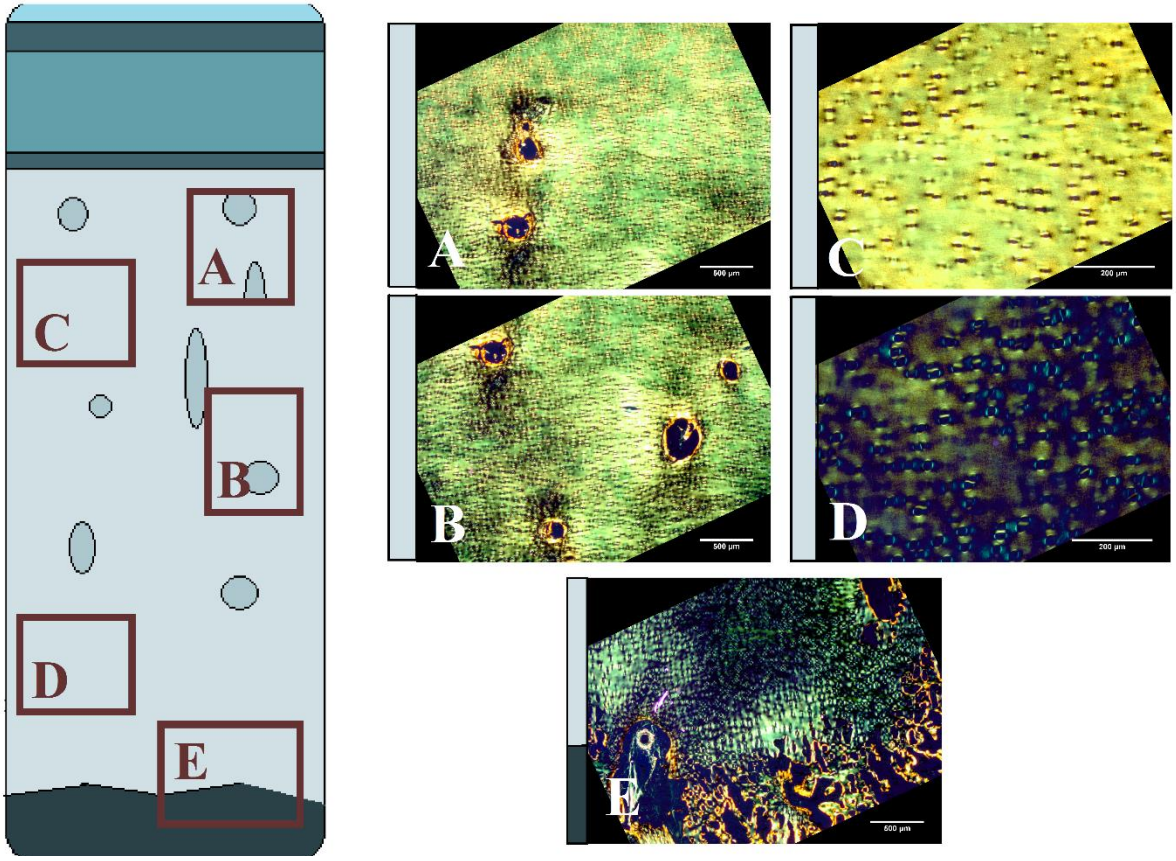

Figure 41: Overview of collagen orientation (picrosirius red staining with PLM) of the medial femoral condyle of horse 6, age: 2 months 21 days. Illustration on the left shows a representation of the complete sample. PLM images correspond to boxes in the illustration on the left. Colours in the illustration correspondend to the colour bar next to the images. A/B/E 2,5x magnification, scale bar = 500 µm. C/D 10x magnification, scale bar = 200 µm A) Cartilage canals directly under the articular cartilage. Note the collagen orientation surrounding the cartilage canals which is more structured compared to younger foals. B) Cartilage canals in the middle of the growth cartilage. Note the collagen orientation surrounding the cartilage canals which is more structured compared to younger foals.. C) Orientation of the collagen fibres in the top of the growth cartilage (well structured). D) Orientation of the collagen fibres in the lower part of the growth cartilage (less structured).

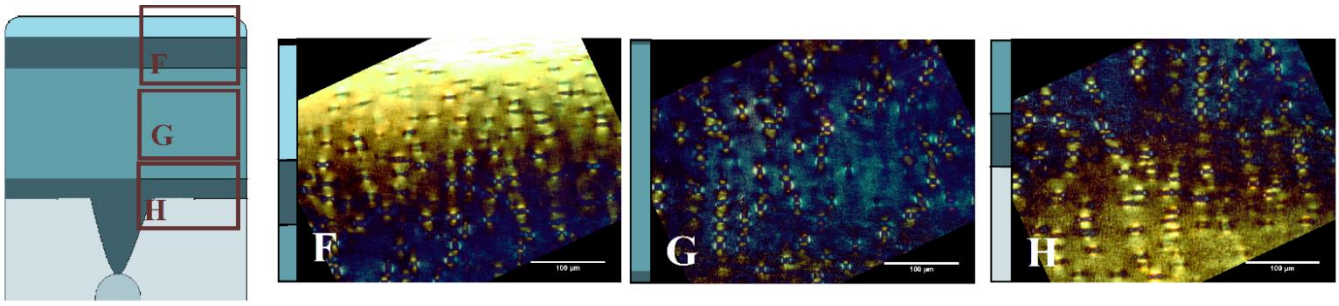

Figure 42: Zoom on collagen orientation (picrosirius red staining with PLM) in the upper part of the cartilage of the medial femoral condyle of horse 6, age: 2 months 21 days. Illustration on the left represents the top of the sample. PLM images correspond to boxes in the illustration on the left. A/B/E 2,5x magnification, scale bar = 500 µm. C/D 10x magnification, scale bar = 200 µm F) Top of the articular cartilage. In the first layer (superficial layer) the orientation of the collagen fibres is parallel to the surface. In the second layer (transitional layer) a predominant orientation is not present. In the third layer (deep) the orientation of the collagen fibres is perpendicular to the articular surface. G) The third layer (deep layer) in which the orientation is clearly perpendicular to the surface. H) In this picture still three different layers are present. First, the perpendicular layer(deep layer) is visible, second there is a second layer which lacks a dominant orientation (second transitional layer). The last layer is the beginning of the growth cartilage.



Figure 43: Overview of collagen orientation (picrosirius red staining with PLM) of the medial femoral condyle of horse 8, age: 6 months 15 days. Image on the left (2,5x magnification, scale bar = 500 µm) shows the entire thickness of the cartilage in the sample. PLM images correspond to boxes in the illustration on the left. Colours in the illustration correspondend to the colour bar next to the images. A/B/C/D 20x magnification, scale bar = 100 µm. E/F 10x magnification, scale bar = 200 µm. A) Upper part of the articular cartilage. In the first layer (superficial layer) the orientation of the collagen fibres is parallel to the surface. In the second layer (transitional layer) a predominant orientation is not present and in the third layer (deep layer) the orientation of the collagen fibres is perpendicular to the articular surface. B) Orientation of the collagen fibres in the deep zone is clearly perpendicular to the surface. C) In this image two different layers are visible, in the first layer (deep zone) the collagen orientation is still perpendicular to the articular surface. The second layer (transitional layer) seems to lack a predominant orientation, however there seems to be more orientation if compared to the same region in the other horses. D) The transition between the second transitional zone without dominant collagen orientation and the growth cartilage. E) The deep zone of the Benninghof structure is still visible at the top of the image. The growth cartilage/bone transition is visible in the bottom part of the image. F) First layer visible is the second transitional layer, followed by the growth cartilage/bone transition zone. In the lower part of this image newly formed bone is visible.



Figure 44: Overview of collagen orientation (picrosirius red staining with PLM) of the medial femoral condyle of adult horse 14 age: 19 years. Image on the left (2,5x magnification, scale bar = 500 µm) shows the entire thickness of the cartilage in the sample. Note that less layers are present compared to the foals involved in this study. PLM images correspond to boxes in the illustration on the left. Colours in the illustration correspondend to the colour bar next to the images. A) 2,5x magnification, scale bar = 500 µm. Mature articular cartilage. In the first layer (superficial layer) the orientation of the collagen fibres is parallel to the surface. In the second layer (transitional layer) a predominant orientation is not present and in the third layer (deep layer) the orientation of the collagen fibres is perpendicular to the articular surface. Fourth layer indicates the bone/cartilage transition zone. B/C/D 20x magnification, scale bar = 100 µm. B) upper part of the articular cartilage. In the first layer (superficial layer) the orientation of the collagen fibres is parallel to the surface. In the second layer (transitional layer)a predominant orientation is absent. In the third layer (deep layer) the orientation of the collagen fibres is perpendicular to the articular surface. C) deep layer, orientation of the collagen fibres is clearly perpendicular to the surface. D) Bone cartilage transition.

Discussion & Conclusion

Cartilage thickness:

A lot of research has been done regarding to cartilage thickness, mostly compared to body mass and loading. For example, Malda *et al*. (2013) showed the relation between articular cartilage thickness and body mass in 58 different mammalian species (16). However, only a few articles gave considerable attention to the changes in cartilage thickness during development. Oikawa *et al.* showed a decrease in cartilage thickness during maturation in the third equine metacarpal bone in Thoroughbreds (age range: 1 day - 264 months n=84)(30) and Nakano *et al.* (1987) showed an increase and later decrease of cartilage thickness in porcine cartilage during development (age range: 3 days – 30 weeks n=25) (31). Both these studies do not contain prenatal samples, in the current study prenatal foals are included which revealed more detailed information about cartilage thickness development. Cluzel *et al.* (2013) also measured cartilage thickness in prenatal foals, however in that study the relation between cartilage thickness and age is not shown (20).

In addition to loading also age is probably of influence on cartilage thickness since endochondral ossification is responsible for the mineralization of the cartilage model. It was expected that the cartilage thickness remains stable at the age of approximately 7 months. Besides the relation of cartilage thickness with age, possibly a difference between the thickness in de medial and lateral femoral condyle can be found. As stated before, the biomechanical loading is highest on the medial condyle of the femur. Therefore it was expected that the cartilage at the medial site was thicker compared to the lateral condyle.

The results of our study, comparing foals and adult horses, show a sigmoidal relationship between cartilage thickness and age. This indicated a limited start value for cartilage thickness during development. The cartilage thickness of horse 1 (age 10m gestation) is the first data point and maximum value used in the current study. However, it is unclear when cartilage thickness is maximal during prenatal development. Possibly the maximum value for cartilage thickness is reached at the age involved in the current study (10m gestation) but maximum cartilage thickness can also be reached in the first or last months of gestation. The adult horses examined in this study have a mean cartilage thickness of 1,387 mm in the lateral femoral condyle and 2,616 mm in the medial femoral condyle. The foals examined in the current study have a mean cartilage thickness of 9,078 mm in the lateral femoral condyle and 12,789 mm in the medial femoral condyle. At the lateral site the mean value for thickness of the adult cartilage is reached during maturation in between the age of 4 months and 25 days (Horse 7) and 6 months and 15 days (Horse 8). At the medial side the same age is expected, however the mean of the adult cartilage thickness (2,616 mm) is thicker than the cartilage thickness measured in horse 7 (1,60 mm) and 8 (1,60 mm). This difference needs to be studied before any reliable statement can be made, our hypothesis is that cartilage thickness decreases during development until a certain point and at this point cartilage thickness slightly increases again under the influence of loading.

Only looking at data for the foals, regression analysis results in a linear relationship between age and cartilage thickness (decreasing during development) with a correlation coefficient (R^2) of 0,897 for the medial femoral condyle and 0,824 for the lateral femoral condyle if the outlier is excluded. The R^2

(square of the correlation coefficient) represents the proportion of the total variance in one variable which can be explained by its linear relationship with the other variable. Therefore 89,7% for medial and 82,4% for the lateral femoral condyle of the total variance of cartilage thickness can be explained by its linear relationship with the variable age. The linear regression model with age and location (lateral or medial) as independent variables and average cartilage thickness as dependent variable show that cartilage thickness is significantly related to age ($p<0,05$). It also reveals that the decrease in cartilage thickness occurs significantly faster in the medial femoral condyle compared to the lateral femoral condyle ($p<0,05$) when the outlier is excluded. Besides age, cartilage thickness is significantly related to location as well. Cartilage thickness is significantly higher in the medial condyle compared to the lateral femoral condyle ($p<0,05$).

In conclusion, cartilage thickness decreases during maturation (with a remarkable decrease from 1-3 cm before birth to a final 2mm in adults) and thickness is significantly higher and decreases significantly faster in the medial condyle compared to the lateral condyle (if outlier is excluded). If adult horses were included, a sigmoidal relationship between cartilage thickness and age was found, indicating a limited start value for cartilage thickness during development. If only the foals were taken into account, a linear relation of cartilage thickness and age was found. Cartilage thickness remains stable from the age of approximately 5 months on the lateral condyle. The medial condyle needs to be studied further before a conclusion can be made.

Vascularity:

Since cartilage in mature horses is avascular the answer to the research question “What is the course of blood vessels development during maturation and at which age does the cartilage become avascular?” seems to be obvious. However, the time course in which the cartilage canals regress was still one of our interests. Lecocq *et al.* found that the vascular density was higher in the youngest prenatal foals in their study (16). Due to the fact that the knee joint is most vulnerable at the age of 4-8 months (see figure 3) and is proposed to be the most vascularized joint after birth (16), we hypothesized that during maturation the cartilage canals start to regress and that the regression is complete at the age of approximately 7 months postpartum. Possible differences in cartilage canal regression speed (and correlated amount of blood vessels per square millimeter) between the lateral and medial site of the femoral condyle could be explained by for example the loading difference between the two sites, knowing that during peak loading, the medial condyle is bearing approximately 75% of the total loading (17). Furthermore we expected to find differences for these parameters in the 3 defined subregions from bone to cartilage surface, with the highest blood vessel count in the zone closest to the bone.

It needs to be mentioned that vascularity is difficult to measure in 5um cartilage tissue sections (false negative and double positive counts very high) and can be better analysed using microCT in order to create a 3D view of blood vessel distribution in the tissue. However, in general, data show a clear decrease of blood vessel counts during the first months of development. The adult horses examined in this study (Horse 12, 13, 14 and 15, n=4) all showed to be avascular. The foals examined in this study showed blood vessels until the age of 4 months and 25 days (horse 7). In total nine foals showed blood vessels and two foals did not. The two foals which lack blood vessels are the oldest foals examined in this study. This implicates that around the age of 5 months cartilage becomes

avascular. More specific, vessels seem to regress between the age of 2 months and 4 months according to our data for horse 6 and 7. To describe the course of the development of the blood vessels a graph was created in which the number of blood vessels per square millimetre was plotted against the age of the foals. In this graph horse 7 and 8 had an appreciable influence on the linear regression line because their values for blood vessels per square millimetre are zero. This problem was overcome by the exclusion of the values of horse 7 and 8. Linear regression analysis showed that vessel density was negatively correlated to age (p<0,05), meaning that when the horse matures the cartilage becomes avascular. Location (lateral of medial) does not show a significant difference in vessel density. The different subregions do not show significant differences in vessel density either.

In conclusion**,** vascularity decreases during development and blood vessels completely disappear around 5 months of age. Data show a sigmoidal relationship between vascularity and age, indicating a limited start value for amount of blood vessels in the tissue during development. There are no significant differences between the lateral and medial condyle in vessel density and no significant differences between the cell density in the different subregions in the cartilage.

Cell density:

Chondrocytes are the resident cells of the cartilage. They vary in organisation and phenotype depending on their location in the cartilage (deep or surface layers) in adults (32,33). Klein *et al*. stated that chondrocytes closely to the surface of the cartilage are densely populated and that density is lower in the deeper zones of the cartilage (32). However, the study of Klein *et al*. was based on bovine cartilage. Similarly, in a study from Quinn *et al*. in 2005, which focused on the human knee joint, found that in the superficial layer the cell density was higher than in the underlying zones (34). Additionally, in that same study cell density was higher in de cartilage from the medial condyle compared to the lateral condyle, again indicating the importance of loading on cartilage organization. However, the locomotion of humans and the loading on the knee joint is totally different from the locomotion and loading pattern in the equine species and for that reason a different result can be expected. Based on the study of Klein *et al.*, it is expected that there will be a difference in cell density between the lateral and medial site. Chondrocytes are dependent on nutrition and overall support by supplying blood vessels or diffusion from the synovial fluid. Therefore it was expected that cell density was highest around the blood vessels and lowest in the top subregion of the cartilage. Overall, blood vessels concentration decreases during maturation, as discussed above. Expected was that chondrocytes will have less support and some of them will, as a consequence, undergo apoptosis/necrosis and cell density becomes lower during maturation.

A significant difference (p<0,05) between the cell density of the lateral and medial femoral condyle in foals is found when outliers are excluded. The boxplot shows a higher cell density in the lateral femoral condyle, which is in contrast to the results found by Klein *et al.* in the human knee (32). However, the difference found in this research project is not significant (p=0,074) if outliers are included. A difference in cell density of the different subregions is expected from the results of previous studies. A Pearson's correlation of 0,143 is found for the correlation between cell density and subregion, thus no significant differences can be found for cell density in the three different subregions. Cell density decreases when age increases (p<0,05).

In conclusion, cellularity decreases during development and stabilizes around 7 months of age. However, a clear mathematical relationship could not be found. The lateral femoral condyles cell density is significantly higher if compared to the cell density in the medial condyle. No significant difference could be found for the different subregions in the cartilage.

Collagen orientation:

As mentioned before, in adult horses the collagen of the articular cartilage is oriented in a specific organization known as the "Benninghof structure" (25). There has been debate about the validity of this hypothetical structure, but Huges *et al.* concluded that these differences in opinion are probably a result of the different methods of fixation used in the different studies (35). From several studies it was concluded that the Benninghof structure of collagen fiber orientation is absent at birth (19,36-38) and horses are born with a uniform cartilage composition (39). Van Turnhout *et al.* found that directly after birth the dominant collagen orientation in equine cartilage is parallel to the cartilage surface. They conclude that the structural remodeling of collagen into a Benninghof structure in the articular cartilage takes place in the first months postpartum, because they were able to see the Benninghof structure only in animals of ten months and older. Furthermore the collagen orientation was found to be parallel to the articular cartilage throughout the entire cartilage depth in stillborn foals. At 4.5 months postpartum van Turnhout *et al.* founds a collagen orientation which was interpreted as a result in between the Benninghof structure and the parallel orientation (25). Concerning the study of type II collagen in developing cartilage, Bland and Ashburst documented in 1996 on the temporal distribution of different types of collagen in foetal and juvenile rabbit articular cartilage. In their study there is no type II collagen found before the age of three weeks postpartum in the menisci and no collagen type II is found in the tibial plateau before the age of 6 weeks postpartum (40,41). Based on the findings from similar studies mentioned above, it is not likely to find a Benninghof like structure in tissue from prenatal foals in our study, but rather a developing process of collagen orientation throughout the first months postpartum. If there is an influence of loading on the collagen orientation in equine juvenile cartilage a difference between the lateral and medial side and between the prenatal foals and foal which have been under influence of loading directly after birth could be expected.
In this research project a Benninghof structure has been found in the two prenatal foals participating, horse 1 and horse 2, both at the medial and lateral femoral condyle. This indicates that a Benninghof structure is already present before birth in horses. This conclusion is not in line with the conclusions of the research carried out by Bland *et al.* in the New Zealand white rabbits (40), the study of Julkunen *et al*. (37), the study of Rieppo *et al*. (38) and the study of van Turnhout *et al.* (42). However, it is partly in line with the results from the study of Lecocq *et al. (24)* and Cluzel *et al (20).* The difference between the cartilage development of the horse and for example the rabbit possibly can be declared by the fact that rabbits are examples of an altricial species and horses are examples of precocial species. This statement needs to be further studied before it is considered as truth. In this research project a Benninghof structure is found in 87,5% of the examined slides. In total 24 slides were examined, in 21 slides a Benninghof structure was found. The absence of the Benninghof structure in the three sections were considered as practical artefacts of polarized light microscopy. (The correct angle of the light might not be found during microscopy.) The Benninghof structure consist of three layers, however in the examination of the foal samples more layers are present in

the cartilage. Besides the superficial layer, the transitional layer and the deep layer with fibre orientation radial/perpendicular to the subchondral bone there is a second transitional zone with a lack of dominant collagen orientation (shown as a dark area in PLM images) present in almost all foals in the articular cartilage. Only horse 5 (lateral + medial), horse 6 (lateral) and the adult horse 14 do not show a second transitional layer. The layer is weak in horse 7 (medial) and horse 8 (lateral). The finding of this second transitional zone is in line with the results of Lecocq *et al. (24)*. The second transitional layer is followed by the rest of the growth cartilage which has a different appearance in the different foals. The remaining growth cartilage consist of well-organized areas interspersed with unorganized or less structured areas in the youngest foals and, gradually during development, more structure into the fibre orientation is visible. In the growth cartilage the blood vessels are partly surrounded with a less structured area, the older the foal the more structured the surrounding of the vessels is. The results of the PLM imaging technique do not implicate that there is any difference between the lateral and medial femoral condyle.

In the current study we show that the Benninghof structure is already apparent in the articular cartilage of prenatal foals and seems to further develop during the first months of life. The collagen orientation in the growth cartilage in the youngest foals is partly well organised and in other areas lack a predominant collagen structure, this gradually improves during aging. The mineralisation process converts the complete growth cartilage into bone and will eventually reach the third zone of the Benninghof structure. This is the point where endochondral ossification is complete.

Prediction for osteochondrosis?

This research project starts with the question “What are the histological changes during cartilage development and can a prediction for osteochondrosis in later life be made?” The first part of the question is answered by the examined parameters discussed above. However, the question if a prediction for osteochondrosis can be made remains unanswered. The developing process of the cartilage is an extremely important event for the long term quality of the cartilage, however in the current research project no clear (precursors of) osteochondral lesions were found. Further research in cartilage development may contribute to the complete understanding of the developmental disease osteochondrosis.

Shortcomings:

Three osteochondral plugs are taken on both the lateral as medial site, one of these plugs is used for histology in this research project. The plugs are all taken at the craniodorsal region of the condyles, but not all at the exact same anatomical location and with different insertion angles. This does have an influence on the measured values of cartilage thickness. The osteochondral plugs used in this study are stored in formaldehyde for a long period of time before the onset of this study (1,5 years). This could possibly influence the results. Huges *et al.* stated that the differences in fixation methods could lead to different results with polarized light microscopy (35). However, in this study the collagen orientation is clearly visible with polarized light microcopy, indicating that the long formaldehyde fixation does not cause any distortions in the tissues collagen orientation. Luthra solution is often used for decalcification but instead in this study an 0,34M (pH=8) EDTA solution is

used; in this way the samples can - besides histochemical stainings - also be used for immunohistochemistry in the future (not always possible with Luthra decalcification).

The cartilage of 11 foals is evaluated in this study. Most of the foals (n=9) where from the KWPN breed, however there were two other breeds (Quarter horse and Arabian horse) participating in this study. The oldest foal examined in this study with an interesting age for knee development (age 6 months 15 days) is from the Quarter horse breed. In this research project no influences of breed or sex are considered and possible deviations due to breed or sex are not taken into account.

There are two papers published in which foetal and postnatal equine cartilage development are examined with inter alia polarised light microscopy. One of these papers is a result from the study of Cluzel *et al. (20)*, the other from Lecocq *et al.* (24). As in this study, both used a picrosirius red staining and evaluated it with PLM. However, there are some differences in the picrosirius staining protocol. In the current study we made use of a protocol for picrosirius staining obtained from the IRAS, which is specialised in visualization of collagen in meat products (43). In the study of Cluzel *et al.* and Lecocq *et al.*, a different picrosirius red staining protocol was used. The major difference is the addition of a digestion step with papain to strip the proteoglycans and permit the stain to access the collagen fibres (24). Both researchers added this extra papain step in their protocols after personal communication with Dr. K. Pritzker (Mount Sinai Hospital, Toronto). In the literature an improvement of 700% in birefringence is found after addition of the papain step (44). However, in this study the birefringence of the collagen fibres is clearly visible without this additional step.

Cartilage thickness, cellularity and vascularity are all measured using the stitch images made in LAS v4,2. This stitch images have been carefully put together. Still there are some artefacts found in the stitch images. Two of the stitch images are found to be incorrect and excluded from the study. It cannot be guaranteed that all the other stitch images are a perfect reflection of the real samples. With histology a 2D image is made of a 3D object. Blood vessels squirm though the cartilage and when a section slide for histology is made a single blood vessel can be broached multiple times. This can influence the reliability of the measurements. This problem could be solved by making a 3D image of the blood vessels in the cartilage, which will be described later in the section future plans. Cell density is measured with different methods. Either a computer program and manual cell counts are performed. The computer program is specifically made for this research project but still there can be differences between the manual cell counts and the computer modulated cell counts.

Future plans

In the near future MicroCT will be performed. A test with micro CT has already been carried out with some promising results. The aim of the addition of microCT is to give a 3D image of the cartilage and cartilage canals/blood vessels. A subsequent PLM study combined with Fourier Transformed Infrared Imaging (FTIRI) technique will be carried out in Finland by Janneke Boere coming August. More foal samples were collected and need further processing to amplify the data sets.

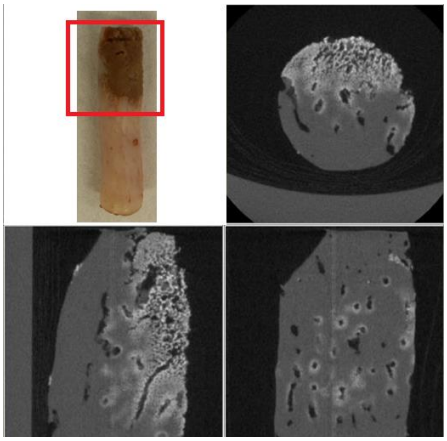

Figure 45: test sample microCT. Osteochondral plug, foal aged 10 months gestation. Resolution 20µm. Cartilage canals are visible within the cartilage.

Acknowledgements

I wish to thank various people for their contribution to this project. Special thanks should be given to Janneke Boere, my research project supervisor for her professional guidance and valuable support. I would like to thank Chris van der Lest for his statistical and overall support. I would like to express my very great appreciation to Dr René van Weeren, Jos Malda, Ben Gorissen and the other members of the centaur meeting group for their valuable and constructive suggestions and support during this research project. I would like to thank Monique Tersteeg and Mattie Rijen for their valuable technical support on this project and Rob Bleumink and Richard Wubbolts for their help and assistance with the microscope and analysis.

References

(1) Mackie EJ, Ahmed YA, Tatarczuch L, Chen KS, Mirams M. Endochondral ossification: how cartilage is converted into bone in the developing skeleton. Int J Biochem Cell Biol 2008;40(1):46-62.

(2) Bjeffcott L, Henson FMD. Studies on growth cartilage in the horse and their application to aetiopathogenesis of dyschondroplasia (osteochondrosis). Veterinary Journal; 1998.156: 3, 177-192.5 pp 1998.

(3) Lawrence LA. Principles of bone development in horses. In: Pagan JD, editor. Nottingham: Nottingham University Press; 2005.

(4) Weeren PR. Equine osteochondrosis: a challenging enigma. Pferdeheilkunde; 2005.21: 4, 285-290, 292 2005.

(5) Carlson CS, Cullins LD, Meuten DJ. Osteochondrosis of the articular-epiphyseal cartilage complex in young horses: evidence for a defect in cartilage canal blood supply. Veterinary Pathology; 1995.32: 6, 641-647 1995.

(6) Stromberg B. A review of the salient features of osteochondrosis in the horse. Equine Vet J 1979 Oct;11(4):211-214.

(7) van Weeren PR, Jeffcott LB. Problems and pointers in osteochondrosis: Twenty years on. Vet J 2013 Jul;197(1):96-102.

(8) Dik KJ, Enzerink E, van Weeren PR. Radiographic development of osteochondral abnormalities, in the hock and stifle of Dutch Warmblood foals, from age 1 to 11 months. Equine Vet J Suppl 1999 Nov;(31)(31):9-15.

(9) Ytrehus B, Carlson CS, Ekman S. Etiology and pathogenesis of osteochondrosis. Veterinary Pathology; 2007.44: 4, 429-448 2007.

(10) Hayashi K. Three-dimensional organization of the cartilage canal--a scanning electron-microscopic study by vascular cast of the rabbit's femoral head. Nihon Seikeigeka Gakkai Zasshi 1992 May;66(5):548-559.

(11) Olstad K, Ytrehus B, Ekman S, Carlson CS, Dolvik NI. Epiphyseal cartilage canal blood supply to the tarsus of foals and relationship to osteochondrosis. Equine Vet J 2008;40(1):30-39.

(12) Blumer MJF, Longato S, Fritsch H. Structure, formation and role of cartilage canals in the developing bone. Annals of Anatomy 2008;190(4):305-315.

(13) Visco DM, Hill MA, Van Sickle DC, Kincaid SA. The development of centres of ossification of bones forming elbow joints in young swine. J Anat 1990 Aug;171:25-39.

(14) Olstad K, Ytrehus B, Ekman S, Carlson CS, Dolvik NI. Epiphyseal cartilage canal blood supply to the tarsus of foals and relationship to osteochondrosis. Equine Veterinary Journal; 2008.40: 1, 30-39 2008.

(15) Ytrehus B, Ekman S, Carlson CS, Teige J, Reinholt FP. Focal changes in blood supply during normal epiphyseal growth are central in the pathogenesis of osteochondrosis in pigs. Bone 2004 Dec;35(6):1294-1306.

(16) Malda J, de Grauw JC, Benders KEM, Kik MJL, van de Lest CHA, Creemers LB, et al. Of Mice, Men and Elephants: The Relation between Articular Cartilage Thickness and Body Mass. PLoS ONE 2013;8(2).

(17) Frisbie DD, Cross MW, McIlwraith CW. A comparative study of articular cartilage thickness in the stifle of animal species used in human pre-clinical studies compared to articular cartilage thickness in the human knee. Veterinary and Comparative Orthopaedics and Traumatology 2006;19(3):142-146. 22 ref.

(18) Malda J, Benders KEM, Klein TJ, de Grauw JC, Kik MJL, Hutmacher DW, et al. Comparative study of depth-dependent characteristics of equine and human osteochondral tissue from the medial and lateral femoral condyles. Osteoarthritis Cartilage 2012;20(10):1147-1151.

(19) Turnhout MCv, Haazelager MB, Gijsen MAL, Schipper H, Kranenbarg S, Leeuwen JL. Quantitative description of collagen structure in the articular cartilage of the young and adult equine distal metacarpus. Animal Biology 2008 1-2 November 2007;58(4):353-370.

(20) Cluzel C, Blond L, Fontaine P, Olive J, Laverty S. Foetal and postnatal equine articular cartilage development: Magnetic resonance imaging and polarised light microscopy. Eur Cells and Mater 2013;26:33-48.

(21) Bank RA, Soudry M, Maroudas A, Mizrahi J, TeKoppele JM. The increased swelling and instantaneous deformation of osteoarthritic cartilage is highly correlated with collagen degradation. Arthritis Rheum 2000 Oct;43(10):2202-2210.

(22) Grunder W. MRI assessment of cartilage ultrastructure. NMR Biomed 2006 Nov;19(7):855-876.

(23) Basser PJ, Schneiderman R, Bank RA, Wachtel E, Maroudas A. Mechanical Properties of the Collagen Network in Human Articular Cartilage as Measured by Osmotic Stress Technique. Arch Biochem Biophys 1998 3/15;351(2):207-219.

(24) Lecocq M, Girard CA, Fogarty U, Beauchamp G, Richard H, Laverty S. Cartilage matrix changes in the developing epiphysis: early events on the pathway to equine osteochondrosis? Equine Vet J 2008;40(5):442-454. many ref.

(25) Turnhout MCv, Haazelager MB, Gijsen MAL, Schipper H, Kranenbarg S, Leeuwen JL. Quantitative description of collagen structure in the articular cartilage of the young and adult equine distal metacarpus. Animal Biology 2008 1-2 November 2007;58(4):353-370.

(26) Brama PA, TeKoppele JM, Bank RA, Barneveld A, van Weeren PR. Development of biochemical heterogeneity of articular cartilage: influences of age and exercise. Equine Vet J 2002 May;34(3):265-269.

(27) Xia,Y.Ramakrishnan, N.& Bidthanapally, A. The depth-dependent anisotropy of articular cartilage by Fourier-transform infrared imaging (FTIRI) 780 – 788 . Osteoarthritis Cartilage 2007;15:780-788.

(28) Alhadlaq HA1, Xia Y, Moody JB, Matyas JR. Detecting structural changes in early experime ntal osteoarthritis of tibial cartilage by microsc opic magneticresonance imaging and polarised light microscopy. . Ann Rheum Dis 2004 jun;63(6):709-717.

(29) Pearson RG, Kurien T, Shu KS, Scammell BE. Histopathology grading systems for characterisation of human knee osteoarthritis--reproducibility, variability, reliability, correlation, and validity. Osteoarthritis Cartilage 2011 Mar;19(3):324-331.

(30) Oikawa M, Yoshihara T, Kaneko M. Age-related changes in articular cartilage thickness of the third metacarpal bone in the Thoroughbred. Japanese Journal of Veterinary Science 1989;51(4):829-842. 12 ref.

(31) Nakano T, Brennan JJ, Aherne FX. Leg weakness and osteochondrosis in swine: a review. Canadian Journal of Animal Science; 1987.67: 4, 883-901 1987.

(32) Klein TJ, Chaudhry M, Bae WC, Sah RL. Depth-dependent biomechanical and biochemical properties of fetal, newborn, and

tissue-engineered articular cartilage. J Biomech 2007;40(1):182-190.

(33) Stockwell RA, Meachim A. The chondrocytes. In: Freeman MAR(), editor. Adult articular cartilage Turnbridge Wells, England: Pitmann Medical; 1979. p. 69-144.

(34) Quinn TM, Hunziker EB, Hauselmann HJ. Variation of cell and matrix morphologies in articular cartilage among locations in the adult human knee. Osteoarthritis Cartilage 2005 Aug;13(8):672-678.

(35) Hughes L, Archer C, Gwynn I. The ultrastructure of mouse articular cartilage: collagen orientation and implications for tissue functionality. A polarised light and scanning electron microscope study and review. . Eur Cell Mater 2005 jun;20(9):68-84.

(36) van Turnhout MC, Schipper H, Engel B, Buist W, Kranenbarg S, van Leeuwen JL. Postnatal development of collagen structure in ovine articular cartilage. BMC Dev Biol 2010 Jun 7;10:62-213X-10-62.

(37) Julkunen P, Iivarinen J, Brama PA, Arokoski J, Jurvelin JS, Helminen HJ. Maturation of collagen fibril network structure in tibial and femoral cartilage of rabbits. Osteoarthritis Cartilage 2010 Mar;18(3):406-415.

(38) Rieppo J, Hyttinen MM, Halmesmaki E, Ruotsalainen H, Vasara A, Kiviranta I, et al. Changes in spatial collagen content and collagen network architecture in porcine articular cartilage during growth and maturation. Osteoarthritis Cartilage 2009 Apr;17(4):448-455.

(39) Brommer H, Brama PA, Laasanen MS, Helminen HJ, van Weeren PR, Jurvelin JS. Functional adaptation of articular cartilage from birth to maturity under the influence of loading: a biomechanical analysis. Equine Vet J 2005 Mar;37(2):148-154.

(40) Bland YS1 AD. Changes in the content of the fibrillar collagens and the expression of their mRNAs in the menisci of the rabbit knee joint during development and ageing.. Histochem J 1996 April;28(4):265-274.

(41) Bland YS1 AD. Development and ageing of the articular cartilage of
the rabbit knee joint: distribution of the fibrillar collagens.. Anat Embryol (Berl) 1996 Dec;194(6):607-19 1996 Dec;194(6):607-619.

(42) Turnhout MCv, Haazelager MB, Gijsen MAL, Schipper H, Kranenbarg S, Leeuwen JL. Quantitative description of collagen structure in the articular cartilage of the young and adult equine distal metacarpus. Animal Biology 2008 1-2 November 2007;58(4):353-370.

(43) Flint FO, Pickering K. Demonstration of collagen in meat products by an improved picro-Sirius red polarisation method. Analyst 1984 Nov;109(11):1505-1506.

(44) Melrose J, Smith S, Ghosh P. 3.2.5.3. Picrosirius Red. In: Sabatini M, De Ceuninck F, Pastoureau P, editors. Methods in molecular medicine: Cartilage and Osteoarthritis Volume 2: Structure and in vivo analysis Totowa, New Jersey: Human Press; 2004. p. 54-56.

Appendix

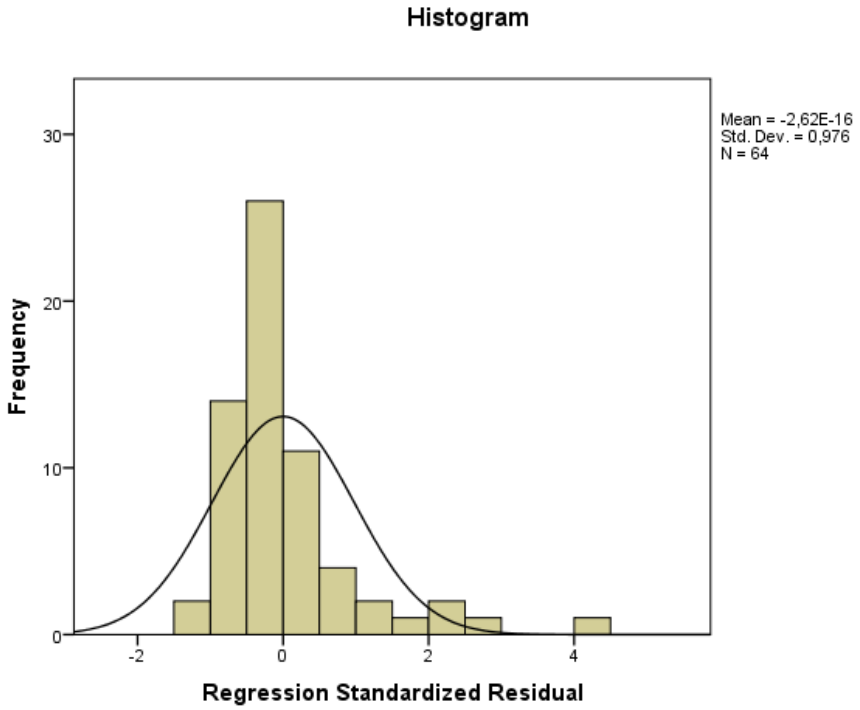

Figure 1: Histogram does not show a satisfying normal distribution. Dependent variable is the average amount of cells/mm2.

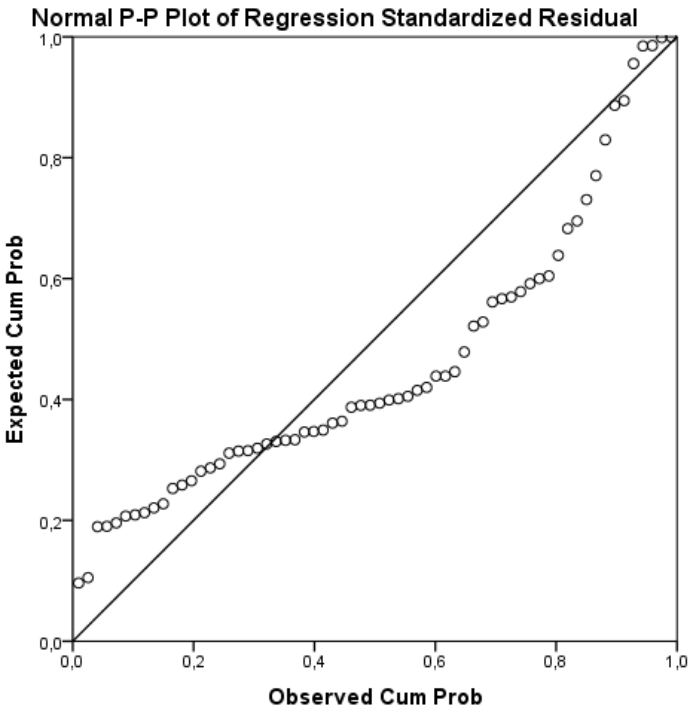

Figure 2: Normal P-P Plot of regression standardized Residual with cells/mm2 as the dependent variable. Note the difference between the observed and the expected values.

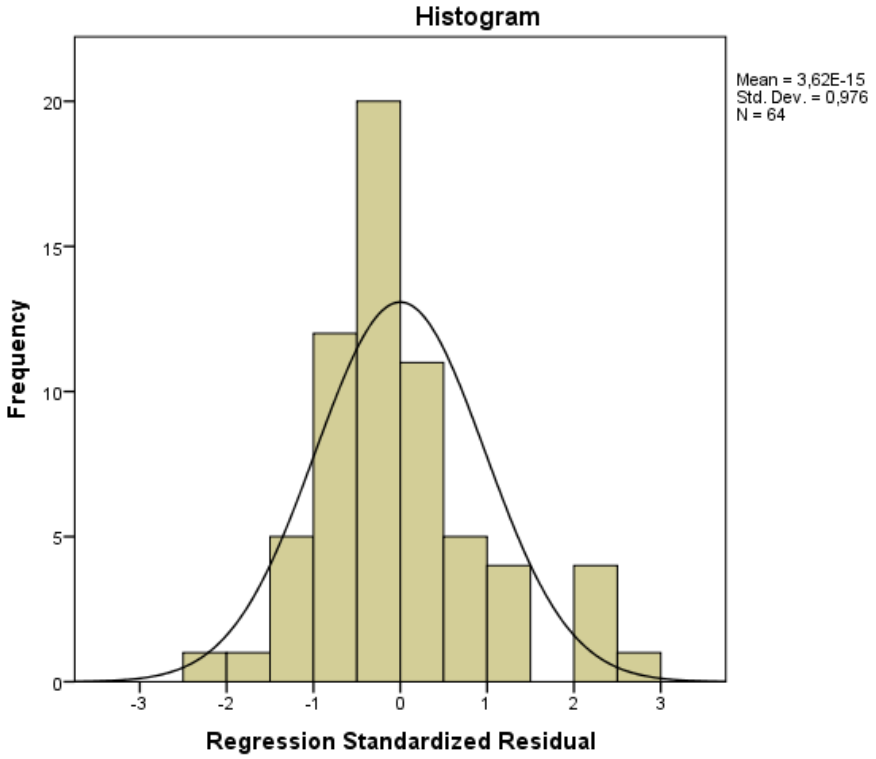

Figure 3: Histogram does show a satisfying normal distribution. Dependent variable is the ln cells/mm2.

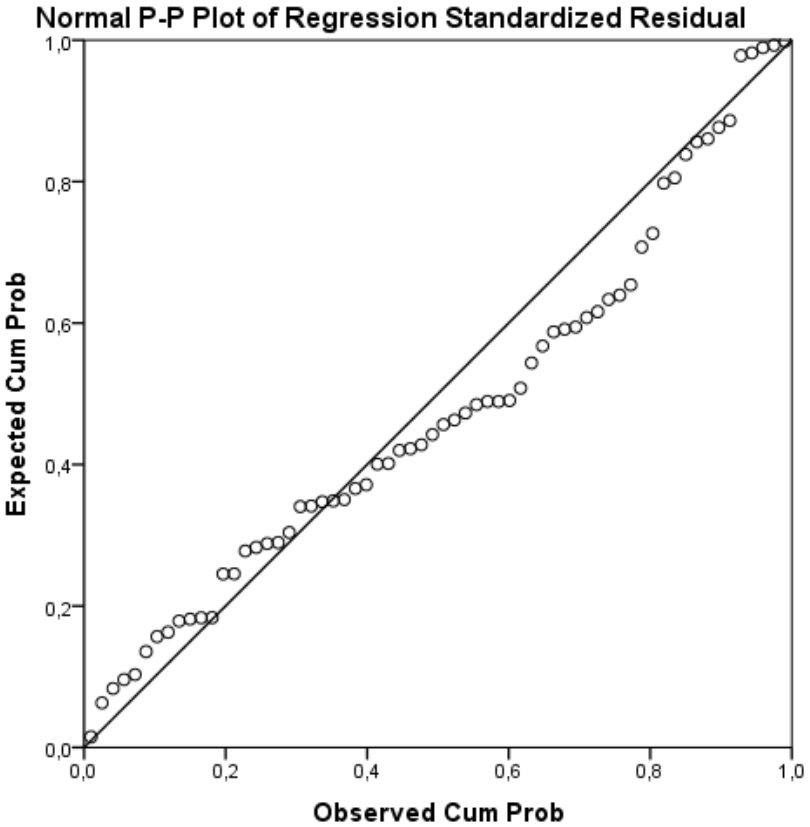

Figure 4: Normal P-P Plot of regression Standardized Residual with Ln cells/mm2 as the dependent variable. The observed values are more in line with the expected value's.

PROTOCOL

Deparaffinization of tissue sections

Before proceeding with the staining protocol, the slides must be deparaffinized and rehydrated. Incomplete removal of paraffin can cause poor staining of the section.

Materials and reagents

- Xylene
- 100% ethanol
- 96% ethanol
- 70% ethanol
- 50% ethanol
- Aquadest

Method

Place the slides in a rack, and perform the following washes:

- 4 min xyleen
- 4 min xyleen
- 2 min 100% alc
- 2 min 96% alc
- 2 min 70% alc
- 2 min 50% alc
- Aquadest (at least 1 minute)

Keep the slides in the Aquadest until ready to perform staining. At no time from this point onwards should the slides be allowed to dry.

PROTOCOL

EDTA-oplossing voor decalcificeren botweefsel

0.34M EDTA pH 8.0

Chemicaliën

EDTA ethyl-di-amine-tetra-acetic acid, disodium salt dihydrate (Acros Organics # 147850010)
$C_{10}H_{14}N_2Na_2O_8 \bullet H_2O$
FW=372.23 g/mol

Natroloog Sodium hydroxide pellets (Merck # 1064981000)
NaOH
FW=40.00 g/mol
VOORZICHTIG: irriterend voor de huid + corrosief! Werk met handschoenen!

Procedure (voor 1 liter EDTA 0.34M, pH 8.0)

- Weeg 125 g EDTA af in grote fles
- Voeg 800 ml demi-H_2O toe
- Schud met roervlo en meet pH (de oplossing is nu wit en troebel)
- Weeg +/- 20g NaOH pellets af
- Voeg geleidelijk aan de helft van de NaOH pellets toe (de oplossing kan warm worden!)
- Na +/- 5 minuten wordt de oplossing minder troebel
- Voeg geleidelijk aan meer NaOH pellets toe totdat een pH van 8.0 bereikt is
- Als alle deeltjes opgelost zijn, vul aan met demi-H_20 tot een volume van 1000 ml
- Controleer of de pH 8.0 is en stel eventueel bij
- De oplossing is nu klaar voor gebruik

Opmerkingen:

- Een oplossing van 1M = 1 mol/liter
- Als EDTA een molecuulgewicht (FW) heeft van 372.23 g/mol, moet er 125 g gebruikt worden in 1 liter om een oplossing van 0.34M EDTA te krijgen

HAEMALUIN-EOSINEKLEURING

KLEURING:
- 4 min in haemaluin.
- minimaal 10 min spoelen en laten blauwen in water.
- 3 min in eosine.
- 30 sec in alcohol 70%.
- 1 min in alcohol 96 %.
- 1 min in alcohol 100 %.
- 1 min in alcohol 100 %.
- 1 min xyleen.
- 1 min xyleen en insluiten.

<u>Zure haemaluin vlgs. P. Mayer:</u>
- 1 gram haematoxyline (Merck CI No. 75290) oplossen in 1000 ml aqua dest.
- dan gelijktijdig toevoegen:
  0,2 gram ~~jodium~~ natrium jodat p.a. NaJO3
  50 gram kaliumaluminiumsulfaat p.a. KAl (SO4)2.12 H2O
- goed mengen waarbij de oplossing een blauwviolette kleur aanneemt.
- daarna toevoegen:
  50 gram chloralhydraat
  1 gram citroenzuur

Na mengen slaat de kleur om in roodviolet. In goed gesloten bruine flessen is de kleurstof lang houdbaar. Voor gebruik filtreren.

<u>Eosine:</u>
- 10 gram eosine (gelblich, Merck CI No.45380) oplossen in 500 ml aq.dest.
- na oplossen 500 ml alcohol 96 % toevoegen.
- minstens 24 uur laten staan en voor gebruik filtreren.

RESULTAAT:
Kernen, kalk, kraakbeen en bacterien blauw.
Protoplasma en spierweefsel roserood.

PICRO-SIRIUS RED POLARISATIE KLEURING

KLEURING:

vrij coupes
- 60 min aceton
- 5 min picro-formaline fixatief
- 10 min stromend leidingwater
- 60 min picro-sirius red kleurstof
- 5 min 0,01 M HCL
- 1 min aq.dest
- 3x 1 min alcohol 100 %
- 2x 3 min xyleen

De eerste drie stappen worden alleen op cryostaat coupes uitgevoerd.

Picro-formaline fixatief:
- 10 ml 40 % formaldehyde
- 90 ml 95 % ethanol verzadigd met picrinezuur

Picro-sirius red kleurstof:
0,1 gram sirius red F3BA (CI No. 35780) in 100 ml verzadigde waterige picrinezuur oplossing verhitten, totdat de kleurstof is opgelost. Laten afkoelen. Er moet een overmaat picrinezuur kristallen aanwezig zijn. 24 uur voor gebruik laten staan. Indien er geen overmaat kristallen aanwezig is, dan extra picrinezuur toevoegen en het verhittings en afkoelingsproces herhalen.

RESULTAAT:

	helderveld microscopie	polarisatie microscopie
rauw collageen	rood	versterkte dubbelbreking heldere polarisatie kleuren: oranje, groen, goud
verhit collageen	rood	versterkte dubbelbreking polarisatie kleuren: helder oranje en rood tot vaal rood
gelatine	helder roze	geen duidelijke dubbel-breking
spierweefsel	geel	geen dubbelbreking
elastine	geel	onveranderde dubbel-breking
andere eiwitten	geel	geen dubbelbreking