MASTER THESIS

The role of blood-brain barrier disruption in spontaneous intracerebral haemorrhage and small vessel disease

a systematic review of imaging and pathology studies

Whitney M. Freeze

On behalf of Master programme Neuroscience&Cognition, Utrecht University
Supervisor: Dr. C.J.M. Klijn
Second reviewer: Prof. dr. G.J. Biessels
Setting: Neurology department, University Medical Center Utrecht

Abstract

Spontaneous intracerebral haemorrhage (ICH) is a detrimental type of stroke leading to high disability and mortality rates. Despite many attempts at unraveling its etiology the exact pathogenesis remains elusive. Interestingly, emerging evidence suggests that blood-brain barrier (BBB) disruption may be an important trigger in the vessel rupture cascade that characterizes spontaneous ICH. In order to clarify the possible pathogenic role of BBB damage in ICH, this systematic review lines out current evidence on BBB disruption in spontaneous ICH and its two main underlying small vessel disease processes, cerebral amyloid angiopathy (CAA) and hypertensive vasculopathy (HV). 59 human and animal studies were identified, including six studies that investigated BBB integrity in ICH, 12 studies that assessed this in CAA, and 41 studies investigating this in HV. Based on the literature it can be concluded that BBB disruption is apparent in spontaneous ICH and originates in associated small vessel disorders. Limited evidence suggests that heterogeneous mechanisms may underlie BBB alterations in relation to amyloid angiopathy and hypertension. Mediating factors may affect BBB integrity including genetic predispositions, dietary influences, and aging. Also, a universal relationship between BBB disruption and neuro-inflammation seems to be apparent. Future research should emphasize reliable classification of patients according to type of vasculopathy and make use of translational research approaches to unravel possible distinct mechanisms leading to HV- and CAA-related ICH.

Introduction

Spontaneous intracerebral haemorrhage (ICH) results from rupture of small vessels in the brain. It is not only the most disabling form of stroke (Qureshi et al., 2009), but also the deadliest one, with an overall case fatality of approximately 40% at 1 month, and 55% at 1 year (van Asch et al., 2010). In general, two distinct types of cerebral small vessel disease (CSVD) are thought to be responsible, namely hypertensive vasculopathy (HV) and cerebral amyloid angiopathy (CAA). In hypertensive vasculopathy, plasma protein leakage into the vessel wall, vascular fibrosis, and accumulation of lipid-containing macrophages affect the small deep penetrating vessels in the brain (Grinberg and Thal., 2010). This type of small vessel disease is usually associated with haemorrhage located in deep brain structures, including the basal ganglia and thalamus (Gregroire et al., 2011). CAA is characterized by progressive amyloid-β (Aβ) protein deposition in the walls of capillaries and small to medium sized vessels of the cerebral cortex (Vinters, 1987), and is an important cause of lobar haemorrhage (Charidimou et al., 2012). However, the dichotomous classification HV and CAA as a cause for deep and lobar ICH respectively is rather insufficient, as many patients with deep ICH do not have hypertension and lobar ICH is attributable to CAA in up to 15 percent of cases (Mehndiratta et al., 2012). Despite the high disability and mortality rates of ICH, outcome has not improved over the last 30 years (van Asch et al., 2010). This is likely the consequence of missing knowledge on different mechanisms in ICH and a resulting lack of treatment and prevention strategies. Further insights in the heterogeneous pathophysiological processes underlying ICH may lead to identification of individuals at risk for ICH, improved classification of ICH patients, and more specific treatment strategies.

During the past decades several studies have stressed an important role of a disrupted blood-brain barrier (BBB) in both small and large vessel disease. The BBB is a complex structure located along the continuous cerebrovascular endothelium, which is selectively permeable to blood constituents and thereby protects the brain parenchyma from harmful substances. Malfunction of this barrier can lead to enhanced permeability, which subsequently may cause damage to the vessel wall and surrounding brain tissue. BBB damage has been hypothesized to be the primary initiating factor of hypertension-related small vessel disease (Wardlaw, 2010). Interestingly, accumulating evidence also suggests a pivotal role of BBB disruption in CAA-related vessel pathology (Carrano et al., 2012). Since both of these small vessel disorders are associated with ICH, BBB disruption may consequently play a role in its development. Consistent with this hypothesis, there is evidence that suggests a role for BBB disruption in the pathogenesis of spontaneous ICH (Lee et al., 2007). However, to date, the exact pathophysiological link between BBB disruption in small vessel disease and spontaneous ICH remains poorly understood. The aim of this systematic review is to provide an overview on the currently available information on BBB disruption in spontaneous ICH and its two main underlying disease processes, hypertensive vasculopathy and cerebral amyloid angiopathy.

Materials and methods

Literature search strategy

Studies were identified by a systematic search on MEDLINE and EMBASE (1966 to 25 November 2013). The terms 'intracerebral haemorrhage', 'hypertension', or 'amyloid angiopathy', were implemented in combination with the term 'blood-brain barrier' (for search string see supplementary table 1).

Inclusion/exclusion criteria

Relevant articles were selected by screening of title and abstract against inclusion and exclusion criteria. Inclusion criteria were primary patient or animal studies on the relation between blood-brain barrier integrity and 1) spontaneous intracerebral haemorrhage, 2) hypertensive vasculopathy, and 3) cerebral amyloid angiopathy. Reports on traumatic ICH or haemorrhagic transformation of infarction, secondary ICH (due to rupture of an arteriovenous malformation, dural arteriovenous fistula, cavernoma, and others), ICH related to a tumor, and studies primarily investigating acute hypertension were excluded. Also, articles on artificially induced ICH in animal models were excluded because the focus of this review is on the possible pathogenic role of BBB disruption in ICH (for a review on the role of BBB disruption following ICH the reader is referred to Keep et al., 2008). Studies testing possible treatment strategies, and articles focusing on ischemic stroke and other (neurological) diseases or conditions such as multiple sclerosis, eclampsia or epilepsy, were not considered in this review. Exceptions to this latter criterion are lacunar stroke, as this is a feature of small vessel disease, and dementia, as this disease spectrum is highly correlated with both CAA and HV (Grinberg and Thal., 2010). Moreover, articles in languages other than English, conference reports, case reports, letters, notes, reviews and surveys were excluded from this analysis.

Data extraction

The following data were extracted from included articles: (1) Study type: human *in vivo/*post-mortem*/in vitro* or animal and design: retro/prospective, (2) main research methods, (3) marker of BBB disruption, (4) possible bias, and (5) studied sample (size), control group, and main findings (see table 1 and table 2). The data are grouped according to type of vascular pathology (ICH, CAA, capillary CAA (capCAA) or HV).

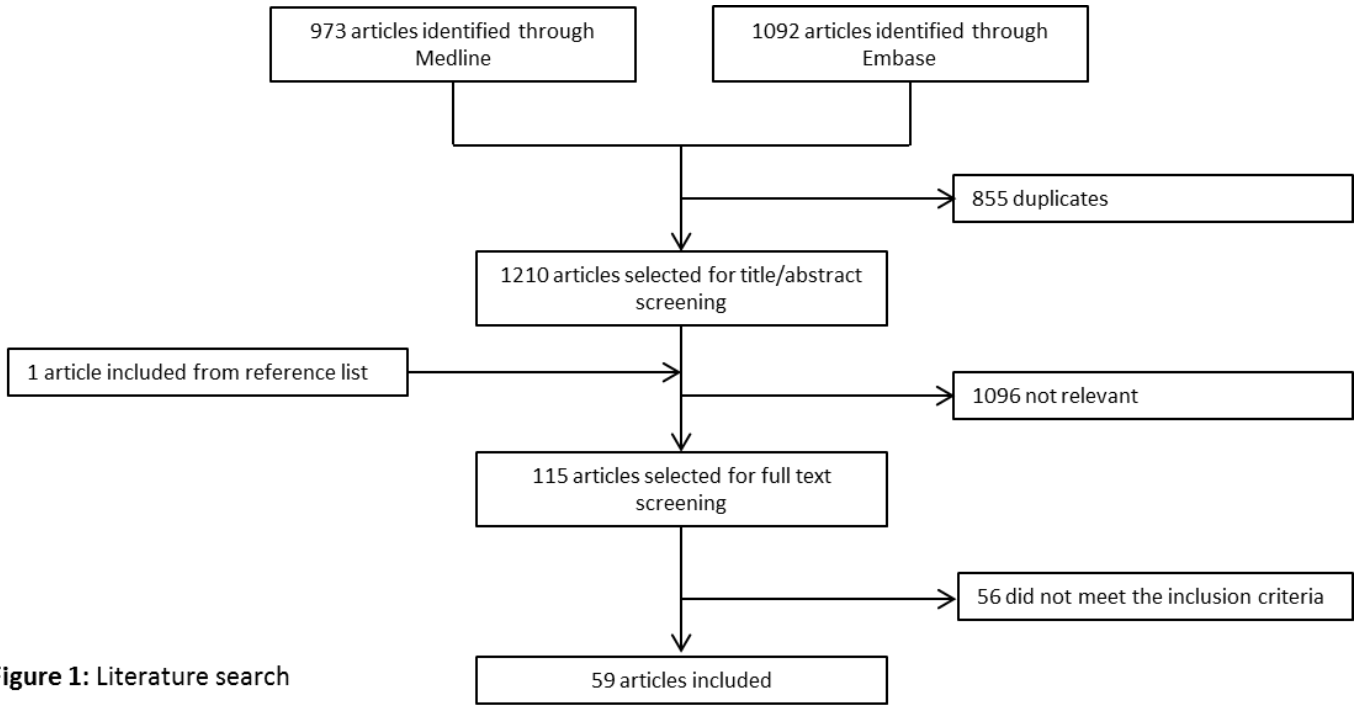

Figure 1: Literature search

Results

Data selection and characteristics

1210 unique articles were found in MEDLINE and EMBASE. Of these, 1152 articles were excluded for the following reasons: Reports on other conditions than (models of) ICH, CAA or HV(n=411), conference reports (n=219), reviews (n=159), reports not on BBB disruption (n=149), language other than English (n=86), reports on treatment strategies (n=83), letters/comments (n=17), surveys (n=8), or case reports (n=7). 13 studies could not be subjected to full text screening because they were not accessible via the Utrecht University online library system[1]. One article, not initially captured by the systematic search, was included from a reference list as this study preceded a follow-up study that was included via systematic search (Wardlaw et al., 2009; Wardlaw et al., 2013). Among the included studies (n=59), six addressed the role of BBB disruption in ICH, 12 studies investigated this in CAA, and 41 studies reported on BBB disruption and HV. From the selected articles, 12 studies used human *in vivo* data. Four studies assessed human postmortem material and one study used human *in vitro* methods. Two studies used a mix of human *in vivo,* human post-mortem or human *in vitro* data. 40 reports derived data from animal studies, including data from *in vivo*, postmortem, and *in vitro* techniques. See table 1 for an overview of study characteristics.

Critical appraisal of studies

As different population samples are studied and many different techniques and markers for BBB disruption are used, there is a large variety in robustness of evidence provided by the included studies. Therefore, the accuracy of measurements and study designs is discussed in paragraphs on BBB disruption in ICH, CAA and HV separately. Table 1 describes study type, design and methods, and possible bias, and table 2 provides an overview of the studied sample.

Blood brain barrier disruption in spontaneous ICH

Six studies were included of which four were human *in vivo* studies, one study used both a human *in vivo* and post-mortem approach, and one study was done in animals.

Human *in* vivo and post-mortem studies

Among the four human *in vivo* studies were 2 studies investigating BBB disruption by means of plasma analysis with enzyme-linked immunosorbent assay (ELISA) (Abilleira et al., 2003; Alvarez-Sabin et al., 2004), and 2 studies used dynamic contrast-enhanced magnetic resonance imaging (DCE-MRI) or single-photon emission computed tomography with use of diethylenetriaminepentraacetic acid (DTPA-SPECT) imaging (Aksoy et al., 2013; Lampl et al., 2005). In addition, one study used both an *in vivo* and human postmortem approach by applying ELISA and immunohistochemistry (Hernandez-Guillamon et al., 2012).

Abilleira et al. (2003) assessed matrix metalloproteinase (MMP) and metallopeptidase (TIMP) levels in plasma of 57 spontaneous ICH patients and compared these levels with those in healthy controls (n=38-62). Moreover, a distinction was made between lobar (n=19) and deep (n=38) ICH and these subtypes were also compared with one another. MMPs are a family of enzymes that contribute

[1] **The student (author) realizes the shortcoming in this. However, as this writing is restricted to a few weeks' time frame, requesting the concerning articles is beyond the scope of this thesis.**

to reorganization of the extracellular matrix and induce BBB disruption by degrading tight junction proteins (Rosenberg et al., 1988; Yang et al., 2007; Florczak-Rzepka et al., 2012). As such, high MMP levels can be regarded as a measure for BBB disruption. TIMPs are natural inhibitors of MMPs and their presence attenuates BBB disruption. In the total ICH sample the authors reported increased MMP-9 and TIMP-1 plasma levels compared with control subjects. Interestingly, when a distinction between ICH subtypes was made, MMP-9 levels were associated with perihematoma (PH) edema volume (e.g. r=0.53) and predicted the development of neurological worsening in the acute stage in cases with deep ICH. These associations were not observed in lobar ICH patients. Additionally, no correlation between TIMP-1 and MMP-9 levels was found in deep ICH patients, which made the authors speculate that greater amounts of noninhibited MMP-9 might account for the larger PH edema volumes in this group. Alvarez-Sabin et al. (2004) also studied plasma MMP in spontaneous ICH patients (n=21) and confirmed that acute MMP-9 levels are associated with PH edema volume (r=0.67), although no distinction between deep and lobar ICH was made here. This association slightly increased when PH edema volume was correlated with the MMP-9/TIMP-1 ratio (r=0.73), supporting the previous speculation of an interplay between MMP-9 and TIMP-1. These findings were extended by demonstration of a temporal profile in blood concentration of some MMPs and TIMPs. MMP-2 and TIMP-2 levels peaked shortly after ICH occurrence, whereas highest levels for MMP-9 and TIMP-1 were found at 24 hours, and for MMP-3 between 24 and 48 hours post ICH. In contrast with the previous study, no variables predicted neurological worsening. However, MMP-3 levels on admission independently predicted mortality, and both MMP-3 at 24 hours (r=0.86) and MMP-9 levels on admission (r=0.69) correlated with residual cavity volume at 3 months.

One study examined BBB permeability following spontaneous ICH (n=25) with contrast agent imaging (Aksoy et al., 2013). BBB permeability was increased in PH brain tissue compared with a corresponding contralateral mirror region of interest (ROI) in the same patient, which served as a control ROI. Large hematomas showed evidence for more BBB leakage compared with small hematomas, and more leakiness was associated with larger edema volumes (r=0.62). Interestingly, BBB permeability measurements around lobar ICH (n=12) were elevated compared with measurements around deep ICH (n=8), independent of hematoma size. No leakage was observed in the hematoma itself, with the exception of one case with haemorrhagic transformation of an ischemic stroke which exhibited BBB leakage throughout the entire area of infarction. Interestingly, in approximately half of the patients a very small increase in BBB leakage was observed in the control region, which might be due to a global BBB disruption related to small vessel disease processes. Alternative explanations for this finding are scanner noise or distant effects of the hematoma on BBB functioning. Another imaging study sought to assess the relation between BBB disruption and functional outcome in 27 spontaneous ICH patients (Lampl et al., 2005). The authors concluded that BBB disruption correlates with functional outcome up to 6 months after ICH (r=0.43-0.56), but not to early neurological deficits. In contrast with Aksoy et al. (2013), this study found no correlation between the degree of BBB damage and hematoma volume. However, this study did not make any distinction between lobar and deep ICH.

Hernandez-Guillamon et al. (2012) assessed MMP-2 and MMP-9 expression *in vivo* in human plasma of CAA-related acute (n=33) and chronic (n=15) ICH patients and healthy controls (n=21), and in postmortem tissue of patients who died from CAA-related ICH (n=6). In contrast with earlier studies (Abilleira et al., 2003; Alvarez-Sabin et al., 2004), comparison between groups revealed no differences in plasma levels of neither MMP, although trends for elevated MMP-9 and decreased

MMP-2 levels in acute ICH patients were noted. In post-mortem tissue of CAA-related spontaneous ICH patients (n=6), both MMP-2 and MMP-9 levels were increased in brain tissue surrounding the hematoma in patients compared with corresponding contralateral areas and compared with control tissue (n=6). Additionally, elevated MMP-2 expression was found in Aβ laden vessels away from the acute ICH and in chronic microbleeds. Upon further vessel examination, MMP-2 was found to be strongly expressed in reactive astrocytes around Aβ-affected vessels and in infiltrated tissue macrophages in the most severely Aβ-comprised vessels, whereas MMP-9 expression was only evident in some inflammatory blood cells around affected vessels. These findings led the authors to conclude that MMP-2 expression within and in the vicinity of Aβ-laden vessels may contribute to ICH pathogenesis.

Animal studies

One animal study inspected BBB disruption in a rat model of hypertensive ICH by means of DCE-MR imaging (Lee et al., 2007). Interestingly, the majority of rats that developed ICH (5 out of 7) showed focal elevations in BBB permeability at the location of the eventual bleeding, up to two weeks before ICH occurrence. The rats that didn't show enhanced BBB permeability had relatively small haemorrhages. This finding strongly suggests a role for BBB disruption in the pathogenesis of hypertension- related spontaneous ICH.

Quality of the evidence and potential pitfalls

Some drawbacks of the abovementioned studies are small sample sizes, the retrospective nature of the human *in vivo* studies, and a lack of pathological confirmation of vasculopathy (Hernandez-Guillamon et al., 2012). Moreover, the control group in some studies may not have been adequately age-matched (Abilleira et al., 2003; Alvarez-Sabin et al., 2004) or controlled for presence of concomitant Alzheimer's disease (AD) (Hernandez-Guillamon et al., 2012). In addition, one study included ICH patients with an underlying presumed cause other than small vessel disease (Aksoy et al., 2013).

Blood-brain barrier disruption in CAA

BBB disruption in CAA was investigated in 12 studies, including two human *in vivo* studies, four human post-mortem studies, one study using both a human post-mortem and an *in* vitro approach, four animal studies, and one human *in vitro* study.

Human *in vivo* studies

CAA is highly prevalent in the AD population, and with its strongest clinical risk factor being aging it is found in 80-90% of AD cases at autopsy, as compared with 20-40% in non-demented individuals. (Charidimou et al., 2012; Greenberg et al., 2004). Goos et al. (2012) assessed BBB disruption in the form of CSF/plasma albumin ratios in Alzheimer's disease (AD) patients with (n=26) and without (n=26) possible CAA, and in supposedly healthy individuals with subjective cognitive complaints (n=22). Albumin ratios in CAA-AD patients were not elevated compared with control individuals. In addition, no increased albumin ratios were found in AD patients with possible CAA compared with those without CAA. The absence of a specific association between CAA and BBB disruption in AD was confirmed by another study that found no evidence for additional BBB disruption in the form of P-glycoprotein (Pgp) dysfunction in AD patients with possible CAA (n=6) compared with AD patients without possible CAA (n=12), as measured by means of positron emission tomography (PET) imaging (van Assema et al., 2012).

Human post-mortem studies

4 human postmortem studies all used immunohistochemistry (Bonda et al, 2007; Carrano et al., 2011; Carrano et al., 2012, Clifford et al., 2011) and one study additionally used ELISA (Zipser et al., 2006) to investigate BBB disruption in CAA. Bonda et al. (2007) demonstrated elevated immunoglobulin G (IgG) leakage in both AD cases with(n=3) and without(n=11) severe CAA, as compared with non-demented controls (n=7). This study found only slight co-localization of IgG subunits and vessel Aβ deposition and subsequently speculated that CAA might be a result rather than a cause of BBB disruption in that disruption seems to precede Aβ accumulation. Clifford et al. (2008) showed decreased viability of vascular smooth muscle cells (VSMCs) and leakage of plasma components through the vessel wall in AD-CAA patients (n=24) as compared with healthy control individuals (n=8). Another study reported no differences in BBB disruption between AD patients with and without CAA, operationalized by plasma protein prothrombin leakage through the vessel wall (Zipser et al., 2006). Taken together, these studies find converging evidence for increased disruption in AD patients with CAA compared with healthy control individuals, although leakage seems also apparent in AD patients without concomitant CAA.

Two human post-mortem studies did pose a role for BBB dysfunction in capillary CAA, a condition different from classical CAA in that Aβ not only accumulates in large vessels but also in capillaries (Carrano et al., 2011; Thal et al., 2002). Carrano et al. (2011) examined tight junction (TJ) protein expression in capillary CAA, and indicated BBB disruption as decreased TJ protein expression patterns in Aβ laden capillaries from capCAA patients (n=6) compared with non-affected capillaries in these patients and control tissue (n=2). As with a follow-up study that investigated 23 capCAA patients (Carrano et al., 2012), it was hypothesized that Aβ may lead to BBB dysfunction by causing a neuro-inflammatory response with reactive oxygen species (ROS) production leading to a loss of TJ protein expression in brain vessels with Aβ deposits.

Animal studies

Four animal studies were included, including two studies that used transgenic mice models and western blotting or immunohistochemistry (Hartz et al., 2012; del Valle et al., 2011), one study used immunohistochemistry in scrapie-infected mice (Vorbrodt et al., 1997), and one study used a transgenic mice model which was investigated with western blotting, immunohistochemistry, Tryphan Blue labeling, microdialysis and immunofluorescence (Merlini et al., 2011).

Hartz et al. (2012) assessed TJ protein and MMP expression in cerebral microvessels from transgenic CAA mice and found BBB alterations in the form of decreased TJ protein expression and increased MMP expression compared with wild type (WT) mice (Hartz et al., 2012). This study additionally investigated isolated rat brain microvessels treated with Aβ, and confirmed downregulation of TJ proteins and elevation of MMP-2 and MMP-9 levels. In contrast, del Valle et al. (2011) showed IgG leakage in both Aβ-affected vessels and non-affected vessels in CAA-mice and in control mice, and suggested that BBB disruption might play a pathogenic role in CAA. A third animal study found similar amounts of BBB leakage in scrapie infected mice with and without plaque forming in hippocampal and cortical regions, and found only weak evidence for a direct relationship between Aβ and BBB function by showing increased BBB permeability in plaque forming mice in the cerebellum compared with non-plaque forming mice, which was paralleled by Aβ deposits in vessel

walls. Merlini et al. (2011) assessed BBB integrity in transgenic CAA-mice and showed attenuated glucose brain uptake, decreased expression of the glucose transporter GLUT-1, swelling of astrocytes and retraction of their endfeet, loss of VSMCs and increased BBB permeability to albumin in transgenic mice as compared with WT controls. This study concluded that in this transgenic CAA mice model BBB alterations precede the formation of Aβ deposits.

In vitro studies

1 human *in vitro* study applied immunohistochemistry and trans-endothelial electric resistance (TEER) (Gonzales-Velasquez et al., 2008), and 1 study assessed human *in vitro* material by means of PCR and live/dead assay (Carrano et al., 2011). Gonzales-Velasquez et al. (2008) investigated the effect of Aβ on human cerebral ECs and found increased permeability of EC monolayers with an underlying mechanism of TJ protein displacement and decreased TEER (Gonzales-Velasquez et al., 2008). This study concluded that excess Aβ leads to increased BBB permeability. This was in agreement with findings from Carrano et al. (2011), who also treated human EC culture with Aβ and showed decreased TJ protein mRNA expression and decreased EC viability.

Quality of the evidence and potential pitfalls

As with the ICH studies, limitations in CAA studies are retrospective study designs, small sample sizes, a lack of adequate control groups (Bonda et al., 2007; Carrano et al., 2011; Clifford et al., 2008; Goos et al., 2012), and lack of pathological confirmation of vasculopathy in human *in vivo* studies (Goos et al., 2012; van Assema et al., 2012). Moreover, interpretation of results is difficult because of insufficient definition of control specimens (Carrano et al., 2012) and/or the absence of quantification of measurements (Carrano et al., 2012; Clifford et al., 2008). The wide range of different techniques restricts the comparability of results between studies and the quality of the evidence variable.

Table 1: Characteristics of the included studies

Study	*Design*		*Technique*	*Marker of BBB disruption*	*Possible bias and/or notes*
Spontaneous ICH					
Abilleira et al., 2003	Human *in vivo*	R	ELISA	MMP-3/9 plasma levels and TIMP-1 plasma levels	Control group likely younger than study sample
Aksoy et al., 2013	Human *in vivo*	R	DCE-MRI	Gadolinium leakage	In 10 patients presumed cause other than HV or CAA
Alvarez-Sabin et al., 2004	Human *in vivo*	R	ELISA	MMP-2/3/9 and TIMP-1/2 plasma levels	Same control and possibly patient group as Abilleira et al., 2003
Hernandez-Guillamon et al., 2012	Human *in vivo*	R	ELISA	MMP-2/9 plasma levels	Lack of pathological confirmation of vasculopathy
	Human postmortem		Immunohistochemisrty	MMP-2/9 expression	No AD control group
Lampl et al., 2005	Human *in vivo*	R	DTPA-SPECT	DTPA-SPECT ratio haemorrhage ROI/control ROI	
Lee et al., 2007	Animal	P	DCE-MRI	Gadolinium leakage	
CAA					
Bonda et al., 2007	Human postmortem	R	Immunohistochemistry	IgG leakage	AD brains were not checked for concomitant CAA
Clifford et al., 2008	Human postmortem	R	Immunohistochemisrty	Plasma protein leakage/VSMC viability	No AD control group, no quantification of measurements
del Valle et al., 2011	Animal	P	Immunohistochemistry	IgG leakage	
Goos et al., 2012	Human *in vivo*	R	CSF/plasma analysis	CSF/plasma albumin ratio	Lack of pathological confirmation of vasculopathy, no healthy control group
Gonzales-Velasquez et al., 2008	Human *in vitro*	P	Immunohistochemistry,TEER	TJ protein expression/transendothelial albumin transport/TEER	
Hartz et al., 2012*	Animal	P	western blotting, zymography, Texas red efflux	TJ protein and MMP expression/Texas red efflux rate	
Merlini et al., 2011	Animal	P	Immunohistochemistry, western blotting, immunofluorescence, microdialysis, Trypan Blue labeling	Glucose transporter (GLUT-1) expression and blood to brain transfer, VSMC and astrocyte viability, albumin leakage	

Table 1: Characteristics of the included studies (continued)

Study	*Design*		*Technique*	*Marker of BBB disruption*	*Possible bias and/or notes*
van Assema et al., 2012	Human *in vivo*	R	imaging(PET)	BBB Pgp functioning	Lack of pathological confirmation of vasculopathy
Vorbrodt et al., 1997	Animal	P	Immunocytochemistry	Albumin leakage	
Zipser et al., 2007	Human postmortem	R	immunohistochemistry, ELISA	Prothrombin leakage	No control for vascular risk factors except atherosclerosis
CapCAA					
Carrano et al., 2011	Human postmortem	R	Immunohistochemistry	TJ protein expression	No AD control group
	Human *in vitro*	P	PCR, live/dead assay	TJ protein mRNA expression/EC viability	
Carrano et al., 2012	Human postmortem	R	Immunohistochemistry	TJ protein expression, fibrinogen leakage	No clear definition of control vessels, magnitude of correlations not specified
HV					
Al-Awadi et al., 2006	Animal	P	High performance liquid chromatography (HPLC), Evans blue labeling	GABA blood-brain exchange, H-mannitol and albumin leakage	
Al-Saraff et al., 2003	Animal	P	Radioactive labeling	Sucrose leakage	
Bailey et al., 2011	Animal	P	Immunohistochemistry	TJ protein and MMP-9 expression	Only male rats were included
Bergerat et al., 2011	Animal	P	Spectometry, immunohistochemistry	Cerebral microvascular protein expression	
Braun et al., 2012	Animal	P	Immunohistochemistry	IgG leakage	
Candelario-Jalil et al., 2011	Human *in vivo*	R	Zymography, fluorescent assay	MMP-2/3/9 and albumin plasma and CSF levels	Dementia included in study sample, lack of pathological confirmation of vasculopathy, control group possibly younger, hypertension present only in about 50% of study sample and history of hypertension not known
Fredriksson et al., 1985	Animal	P	Immunohistochemistry, Evan's blue labeling	Fibrinogen and albumin leakage	No quantification of measurements
Fredriksson et al., 1987	Animal	P	Immunohistochemistry, Evan's blue labeling	Fibrinogen and albumin leakage	No quantification of measurements

Table 1: Characteristics of the included studies (continued)

Study	*Design*		*Technique*	*Marker of BBB disruption*	*Possible bias and/or notes*
Fredriksson et al., 1988a	Animal	P	Immunohistochemistry, Evan's blue labeling, light and electron microscopy	Fibrinogen and albumin leakage	Only male rats were included, no quantification of measurements
Fredriksson et al., 1988b	Animal	P	Immunohistochemistry, Evan's blue labeling, electron microscopy	Fibrinogen and albumin leakage	No quantification of measurements
Fredriksson et al., 1988c	Animal	P	Immunohistochemistry, Evan's blue labeling	Fibrinogen and albumin leakage	No quantification of measurements
Gentile et al., 2009	Animal	P	FITC labeling, immunohistochemistry	Albumin leakage	
Hassan et al., 2003	Human *in vivo*	R	ELISA	Plasma markers of endothelial inflammation	66% of control subjects suffered from hypertension, history of hypertension not known
Hatzinikolaou et al., 1981	Animal	P	Radioactive labeling	Tyrosine leakage	Only male rats were included, no surgical sham procedure performed on control rats
Ishida et al., 2006	Animal	P	Immunohistochemistry, western blotting, RT-P CR	Glucose-transport (GLUT-1) and astrocyte (AQP4) protein expression	Only male rats were included
Iwanaga et al., 2008	Animal	P	Microarray, RT-PCR, Western blotting, immunohistochemistry	Horseradish peroxidase leakage	Only male rats were included
Kang et al., 1990	Animal	P	Brain microdialysis, Radioactive labeling	Choline, glucose and phenylalanine transport across BBB, sucrose leakage	
Kemper et al., 2001	Animal	P	Immunohistochemistry	Fibrinogen leakage	Only male animals were included, hypertensive animals received postoperative pharmaceutics while control animals did not, no quantification of measurements, BBB disruption only measured in 4 animals
Knox et al., 1980	Animal	P	Light and electron microscopy	Horseradish peroxidase leakage	

Table 1: Characteristics of the included studies (continued)

Study	*Design*		*Technique*	*Marker of BBB disruption*	*Possible bias and/or notes*
Lightman et al., 1987	Animal	P	Radioactive labeling, electron microscopy	Sucrose leakage	
Lippoldt et al., 2000	Animal	P	Electron microscopy, immunocytochemistry	TJ protein expression, lanthanum nitrate leakage	
Mayhan et al., 1987	Animal	P	Fluorescent microscopy	Dextran leakage	Only male rats were included
Mueller et al., 1980	Animal	P	Radioactive labeling	Albumin RISA	
Nag., 1996	Animal	P	Immunohistochemistry	Plasma protein leakage and extracellular matrix protein expression	Only female rats were included
Rodrigues et al., 2012*	Animal	P	Evan's blue labeling	Albumin leakage	Only male mice were included
Rodrigues et al., 2013	Animal	P	Evan's blue labeling	Albumin leakage	Only male mice were included
Rouhl et al., 2012	Human *in vivo*	R	ELISA	Plasma markers of adhesion molecules and activated monocytes/macrophages	Only about half of the lacunar stroke patients suffered from current hypertension
Schreiber et al., 2012	Animal	P	Immunohistochemistry	IgG leakage	Only male rats were included
Sironi et al., 2004	Animal	P	Contrast-MRI, immunohistochemistry	Gadolinium and fibrinogen leakage	Only male rats were included
Tagami et al., 1987	Animal	P	Electron microscopy	fibrinogen leakage, VSMC viability, subendothelial monocyte accumulation	No normotensive control group, measurements not quantified and no comparison between groups
Takemori et al., 2000*	Animal	P	RT-PCR	Glucose-transporter protein (GLUT-1) and EC adhesion molecule expression	Only male rats were included
Takemori et al., 2013	Animal	P	RT-PCR	Glucose-transporter (GLUT-1), astrocyte (AQP4) protein and adhesion molecule (ICAM-1) expression	Only male rats were included
Tang et al., 1993	Animal	P	Radioactive labeling	Amino acid (tryptophan and glutamic acid) brain uptake	
Topakian et al., 2010	Human *in vivo*	R	DCE-MRI	Gadolinium leakage	

Table 1: Characteristics of the included studies (continued)

Study	*Design*		*Technique*	*Marker of BBB disruption*	*Possible bias and/or notes*
Toth et al., 2013	Animal	P	Immunofluorescence and confocal microscopy, western blotting	IgG leakage, TJ protein expression, fluorescein leakage	Only male mice were included
Ueno et al., 2004	Animal	P	Light microscopy, histochemical labeling	Horseradish peroxidase leakage	Only male rats were included
Wardlaw et al., 2009	Human *in vivo*	R	DCE-MRI	Gadolinium leakage	Hypertension present in approximately 50% of both patient groups
Wardlaw et al., 2013	Human *in vivo*	P	DCE-MRI	Gadolinium leakage	Hypertension present in approximately 50% of patient group. Study population is not strictly CSVD. Follow-up from 2009 study
Werber et al., 1988	Animal	P	Radioactive labeling	Albumin RISA	Only male rats were included
Yamagata et al., 1997	Animal	P	TEER, electron microscopy	TEER, horseradish peroxidase leakage	
Zhang et al., 2010	Animal	P	Evan's blue labeling, microscopy	Albumin leakage	Only male mice were included

ICH, intracerebral hemorrhage; CAA, cerebral amyloid angiopathy; HV, hypertensive vasculopathy; ELISA, enzyme-linked immunosorbent assay; DCE-MRI; dynamic contrast enhanced magnetic resonance imaging; SPECT, single-photon emission computed tomography; PET, positron emission tomography; TEER, transendothelial electric resistance; RT-PCR, real-time polymerase chain reaction; CSF, cerebrospinal fluid; IgG, immunoglobulin, VSMC, vascular smooth muscle cell; TJ, tight junction; RISA, radioiodinated serum albumin; EC, endothelial cell; PgP, p-glycoprotein; MMP, matrix metalloproteinase; TIMP, metallopeptidase; ROI, region of interest; AD, Alzheimer's disease; CSVD, cerebral small vessel disease; BBB, blood-brain barrier

*Only parts of the study that were eligible for inclusion were considered in this review

Blood-brain barrier disruption in hypertensive vasculopathy

BBB disruption in relation to hypertensive vasculopathy was investigated by 41 studies, including six human *in vivo* studies. The remaining 35 HV studies were carried out in animal models mimicking hypertensive small vessel disease.

Human *in vivo* studies

Three studies applied DCE-MR imaging to assess contrast agent leakage (Topakian et al., 2010; Wardlaw et al., 2009; Wardlaw et al., 2013). Topakian et al. (2010) found evidence for BBB disruption in HV by indicating increased leakage of gadolinium in regions of normal appearing white matter in CSVD patients (n=24) as compared with healthy controls (n=15). Supplementary evidence for BBB leakiness in CSVD patients comes from a study that demonstrated increased BBB permeability in lacunar stroke patients (n=51) (Wardlaw et al., 2009). Their control group was composed of patients with cortical ischemic stroke (n=46), and as such the authors concluded that an association between BBB disruption and vasculopathy may be typically inherent to small vessel disease and not to ischemic stroke in general. In a follow-up study, increased basal ganglia BBB permeability was found to predict functional outcome at three years (Wardlaw et al., 2013). However, since this analysis was performed on both lacunar and cortical stroke patients together (n=70) this may not reflect unique CSVD processes. Together these imaging studies support the presence of a relationship between BBB disruption and HV in humans.

Other human *in vivo* studies practiced ELISA (Hassan et al., 2003; Rouhl et al., 2012), or zymography and fluorescent assay (Candelario-Jalil et al., 2011) to examine blood markers of BBB disruption in CSVD patients. Hassan et al. (2003) identified increased serum levels of intercellular adhesion molecule 1 (ICAM-1) in CSVD patients with lacunar infarction with and without concomitant white matter lesions (n=110) as compared with healthy controls (n=50). These increased ICAM-1 serum levels are thought to relate to an inflammatory response at the BBB level by allowing activated leukocytes access to the central nervous system (Dietrich, 2002). In addition, thrombomodulin (TM) and tissue factor (TF) plasma concentrations, also assumed to reflect BBB alterations in relation to inflammation, were elevated in the CSVD group. However, none of these plasma markers were associated with current hypertension. Possible explanations for the absence of a relationship with hypertension may be that blood marker changes only become apparent at more advanced stages of HV or relate to (vascular) risk factors other than hypertension. Another study investigating plasma markers of BBB disruption in relation to inflammation, including ICAM-1, vascular cellular adhesion molecule-I (VCAM-1) and neopterin, also found these markers to be higher in patients exhibiting CSVD imaging markers, including lacunar stroke (n=117) and/or white matter lesions (n=48-81) compared with individuals without such markers (n=196-229) (Rouhl et al., 2012). In addition, neopterin levels were independently associated with enlarged Virchow Robin spaces, which have been suggested as a marker for BBB damage (Wardlaw et al., 2010). Hence, Rouhl et al. suggested that inflammatory processes may play a role in BBB disruption in CSVD. Candelario-Jalil et al. (2011) studied the index of CSF and plasma MMP expression in relation to CSF and plasma albumin as markers for BBB disruption in vascular cognitively impaired (VCI) patients including individuals with CSVD (n=19), mixed AD (n=6), patients with multiple strokes (n=9), and white matter lesions (n=8). Interestingly, CSVD patients could be distinguished from controls (n=20) by the ratio of increased MMP-3 activity and decreased MMP-2 index, and in this group a negative correlation (magnitude not specified) between MMP-2 and albumin index was apparent. A possible explanation given for the

reduced MMP-2 index in CSVD patients is that astrocytes may be damaged in this group as a result of gliosis, and the increased MMP-3 activity may be attributed to increased macrophage and pericyte expression. However, further studies are required to confirm this. Taken together, these studies find indirect hints for a relationship between inflammatory processes and BBB disruption in blood samples of CSVD patients.

Animal studies on vessel leakage

The remaining 35 HV studies were carried out in animal models mimicking hypertensive small vessel disease. Rat models were most frequently used, with 16 studies using the stroke-prone spontaneously hypertensive rat (SHRsp) model, five studies using the spontaneously hypertensive rat (SHR) model, and four studies including both of these models. In addition, two studies artificially induced hypertension in Wistar Kyoto (WKY) rats, one study used stroke-susceptible Dahl-S rats, and one study used different models including SHR, Dahl salt-sensitive rats fed a high salt diet, Hypertensive two-kidney 1 clip Goldblatt rats and deoxycorticosterone acetate (DOCA) salt treated rats (see table 2 for an overview). Five studies artificially induced hypertension in C57B1/6 mice (Gentile et al., 2009; Rodrigues et al., 2012; Rodrigues et al., 2013; Toth et al., 2013; Zhang et al., 2010), and one study artificially implemented hypertension in rhesus monkeys (Kemper et al., 2001). Commonly used methods in the animal studies are Evan's blue and radioactive labeling of plasma proteins, immunohistochemical staining and microscopy. More sporadically applied methods are western blotting, high performance liquid chromatography (HPLC), spectrometry, zymography, fluorescent assay, microarray, real-time polymerase chain reaction (RT-PCR), immunocytochemistry, immunofluorescence, contrast MRI and TEER. Table 1 provides an overview of the specific methods used in each study.

The most commonly used marker of BBB integrity in animal models of HV was extravasation of blood constituents which cannot pass the BBB when it is intact. Several studies investigated the relationship between BBB disruption in the form of vessel leakage and (neuro-) pathology in and around blood vessels in hypertensive animals. An early study on this was performed by Knox et al. (1980), who compared leakage of exogenously administered horseradish peroxidase (HRP) and vessel changes between SHR and normotensive rats. HRP leaked into the vessel wall and in perivascular macrophages and pericytes in SHR, an observation which was rarely present in normotensive control rats. SHR also exhibited more extensive vessel changes such as damaged VSMCs and vessel wall thickening, but further HRP leakage into the brain parenchyma was not observed in this study. In contrast, a series of studies in the SHRsp model, Fredriksson et al. (1985) did find leakage sites of plasma proteins albumin and IgG within the cerebral cortex, white matter and deep gray matter in approximately 25-50% of animals. The location of this leakage coincided with the spatial pattern of neuropathology (Fredriksson et al., 1985). Upon further microscopy inspection alterations in neurons and astrocytes in the form of intracellular edema were observed within sites of BBB leakage (Fredriksson et al., 1988a). Microscopy examination also revealed formation of cystic spaces around sites of BBB leakage, which were marked by watery expansion of endothelial cells and ruptured cellular elements. In the acute stage swollen astrocytes were found in these cysts, whereas at a more chronic stage reactive gliosis became apparent (Fredriksson et al., 1988b). More recent studies in SHRsp indicated relatively early BBB alterations where plasma protein IgG leaked into the vessel wall, but only with advancing age these blood constituents entered the brain parenchyma, although the vessel wall looked morphologically still intact at this stage (Schreiber et al., 2012). Several weeks

after these initial disturbances vessel rupture and thus microbleeds occurred, and the authors speculated that vessel wall fragility, marked by IgG leakage, gives rise to these lesions. Interestingly, in this and a follow-up study another possible marker for early BBB disruption was pointed out, namely intravasal erythrocyte accumulations which were referred to as stases. IgG leakage into the vessel wall occurred in vessels that were marked by these stases, after which microbleeds followed (Braun et al., 2012).

Others investigating plasma component leakage in hypertensive animals found a relationship with microvascular inflammation. Zhang et al., (2010) induced hypertension in mice via angiotensin II infusion. In this model they found albumin leakage and increased leukocyte adhesion associated with chronic hypertension as early as 4 days after hypertension induction. Earlier studies found increased monocyte accumulation and loss of VSMCs in SHRsp with increased vessel permeability of fibrinogen (Tagami et al., 1987), and fibrinogen and gadolinium leakage in SHRsp was associated with macrophage and lymphocyte accumulation (Sironi et al., 2004). Furthermore, Iwagana et al. (2008) observed increased osteopontin expression in glial cells surrounding HRP leaking vessels in SHRsp, which indicates inflammatory processes along vessels with BBB disruption. One other study examined leaking vessels in hypertensive rhesus monkeys and found clustering of reactive microglia and presence of reactive astrocytes in these regions, also indicating neuro-inflammation in relation to BBB disruption (Kemper et al., 2001).

As opposed to the abovementioned studies, others have failed to demonstrate elevated plasma protein leakage in hypertensive animals. Rodrigues et al., 2012 assessed BBB permeability in normotensive and hypertensive DOCA salt treated mice and could not indicate any differences in albumin extravasation between these groups. Three other studies failed to show sucrose leakage in SHR (Kang et al., 1990; Lightman et al., 1987; Al-saraff et al., 2003), and one study using lanthanum-nitrate as a marker for BBB disruption could not indicate leakage in both SHR and SHRsp (Lippoldt et al., 2000). Ueno et al. (2004) could only indicate HRP leakage around vessels in the hypothalamus of SHR and SHRsp but not in other brain regions. Possible explanations for the absence of a relationship between HV and BBB disruption in these studies are small sample sizes (n=5-9) (Lightman et al., 1987; Lippoldt et al., 2000; Rodrigues et al., 2012; Ueno et al., 2004) and/or insensitivity of sucrose leakage as a measurement for BBB leakage.

In consensus with the studies in the previous paragraph, three other studies found no increased BBB disruption in hypertensive animals. But, interestingly, they found an effect of acute blood pressure elevation on BBB disruption, which was larger in normotensive as compared with hypertensive rats. In one study, acute blood pressure elevation led to an altered albumin blood/brain ratio, which was larger in normotensive rats as compared with SHR (Mueller et al., 1980). Werber et al. (1988) expanded these findings by assessing the effect of acute hypertension on BBB disruption in four different rat models of hypertension including SHR, two-kidney, 1 clip Goldblatt rats (2K1C), rats treated with DOCA salt and Dahl salt-sensitive rats fed a high salt diet. In addition two normotensive control groups were studied, including WKY rats and Dahl salt-sensitive rats fed a low salt diet. Under neutral conditions no differences in albumin blood/brain ratio could be traced between any of the groups. But, induction of acute hypertension resulted in higher BBB disruption in both normotensive groups and the chronic hypertensive 2K1C group as compared with the other three chronic hypertension models. This elevation in BBB disruption following acute hypertension was also higher

in the normotensive Dahl salt-sensitive low salt diet model as compared with the WKY model. These findings led the authors to conclude that chronic hypertension reduces the susceptibility of the BBB to acute hypertension disruption, and that this phenomenon is not present in rats suffering from renal hypertension. It was also proposed that a genetic or dietary influence may predispose rats to increased susceptibility to BBB disruption following acute hypertension. A third study confirmed this reduced susceptibility of chronic hypertensive animals to acute arteriolar hypertension in SHRsp (Mayhan et al., 1987). However, venous blood pressure elevation resulted in similar amount of dextran leakage in both hypertensive and normotensive rats.

Variability exists in incidence and severity of BBB disruption between HV animal studies. Of course differences in study design and study samples play a major role in this. In this paragraph studies that point out possible influencers on blood constituent leakage in chronically hypertensive animals are outlined. Fredriksson et al., (1987) studied SHRsp and found that a high salt diet was related to an elevated mean arterial blood pressure and increased incidence of BBB leakage from 25% to 72%. Unfortunately it remains unclear whether this change in odds was due to the high salt diet, higher blood pressure or both. Some studies suggest that increased BBB permeability in hypertensive WKY and SHRsp rats develops particularly at ultra-high maximum systolic blood pressures that excess 210-220 mm Hg (Fredriksson et al., 1988c; Nag., 1996). Rodrigues et al., 2013 indicated increased BBB permeability of albumin in chronic hypertensive Ang II infused mice as compared with chronic hypertensive DOCA salt mice and normotensive controls. This indicates differences in proneness to BBB disruption between these HV mice models. Interestingly, a cholesterol diet attenuated this alteration, and may as such protect BBB integrity. Toth et al., 2013 induced chronic hypertension in young (3 months) and aged (24 months) mice by Ang II infusion and showed increased IgG and fluorescein leakage, altered TJ expression and concomitant neuro-inflammation in the aged animals. The authors attributed this exacerbated BBB disruption to impaired autoregulatory mechanisms in these older mice. Another study revealed a relationship between BBB leakage of albumin and Aβ vessel deposition in hypertensive mice (Gentile et al., 2009), indicating a possible interplay between BBB disruption and amyloid related pathological processes in these animals (see Burgmans et al., 2013 for a recent review on this topic). Together these studies illustrate the complexity of mediating factors in HV related BBB disruption.

Animal studies on other markers of BBB disruption

The BBB is a complex structure and several studies have emphasized other markers than plasma constituent leakage for BBB damage in HV. For example, Tang et al. (1993) showed increased brain uptake of amino acids glutamic acid and tryptophan in SHR, and in another study hypertensive WKY rats displayed elevated brain uptake of amino acid tyrosine (Hatzinikolaou et al., 1981). Homeostatic brain uptake of amino acids is regulated by transport proteins expressed by microvascular endothelial cells, and alterations in amino acid brain uptake may reflect dysfunction of these transport systems. Similarly, specialized transporters regulate the exchange of GABA molecules between brain and blood. Al Awadi et al. (2006) assessed GABA exchange between brain and blood and found increased GABA brain uptake and efflux in SHR as compared with WKY rats. However, GABA homeostasis seemed not to be affected as its brain content did not differ between both groups of rats.

Other studies assessed expression of BBB-related molecules as a marker for BBB integrity. Takemori et al. (2000) investigated the expression of glucose-transporter protein (GLUT-1), which regulates glucose transport across the BBB, and ICAM-1 molecule expression in endothelial cells. The expression of ICAM-1 was elevated in SHRsp compared with WKY rats, and accompanied by increased leukocyte expression of Mac-1, suggesting presence of inflammatory processes in these rats. On the contrary, GLUT-1 expression did not differ between groups, pointing towards intact glucose transport functioning. More than a decade later a follow-up study assessed the same markers (GLUT-1, ICAM-1 and Mac-1) plus expression of aquaporin-4 (AQP-4), a molecule that is expressed by astrocytes and regulates edema formation (Takemori et al., 2013). Elevated ICAM-1 and Mac-1 expression in SHRsp were confirmed by this study, and in contrast with the previous findings this study did show upregulation of GLUT-1 expression with increasing age of the animals. Additionally, AQP-4 expression levels increased with age in SHRsp. The authors addressed the elevated expressions in SHRrp to plasma and cerebral oxidative stress. A similar study mixed these findings by indicating decreased GLUT-1 expression and increased AQP-4 expression in SHRsp with advancing age (Ishida et al., 2006). Additionally, degraded mRNA expression of both markers was shown, and this study concluded that AQP-4 may play a more important role in BBB functioning than GLUT-1 under conditions of hypertension. Another recent study did a proteomic analysis in Dahl salt sensitive hypertensive rats with different degrees of stroke susceptibility, and indicated changes in the expression of BBB related proteins including AQP-4, and protein changes that link to ischemia and angiogenesis in animals with increased stroke susceptibility (Bergerat et al., 2011). More evidence for BBB alterations in HV was collected by Bailey et al. (2011), who showed reduced tight junction protein expression in SHRsp compared with normotensive WKY. Interestingly, a high salt diet reduced TJ protein expression and increased MMP-9 expression in both groups, contributing evidence to the previously mentioned hypothesis that salt diet mediates BBB disruption. Together these studies on expression of molecules along the endothelium hint towards altered expressions in hypertensive rats as compared with normotensive controls. Further studies are needed to clarify these phenomena.

Finally, one *in vitro* study found evidence for BBB alterations in HV by showing that astrocytes isolated from SHRsp induced altered BBB abilities in endothelial cells compared with astrocytes isolated from normotensive WKY rats (Yamagata et al., 1997). Consistent with some abovementioned studies, the authors hypothesized that genetic factors likely play a role in BBB disruption in these hypertensive animals.

Quality of the evidence and potential pitfalls

The majority of studies was carried out in male animals which restricts generalizability of the results, several studies included small sample sizes, and most human studies had a retrospective nature. Some studies did not include an adequate control group (Candelario-Jalil et al., 2011; Hatzinikolaou et al., 1981; Kemper et al., 2001; Tagami et al., 2001; Wardlaw et al., 2013), or did not quantify measurements (Fredriksson et al., 1985; Fredriksson et al., 1987; Fredriksson et al., 1988a; Fredriksson et al., 1988b; Fredriksson et al., 1988c; Kemper et al., 2001; Tagami et al., 1987). Different means of operationalizing BBB integrity makes comparison of studies difficult and secondary vascular risk factors may have influenced results in some human studies.

Table 2: Study population and main findings

Study	*Study sample(n)*	*Control group(n)*	*Main Findings*
ICH			
Abilleira et al., 2003	Spontaneous ICH(57); deep(38) and lobar(19)	Healthy controls(38-62)	MMP-9 increased after ICH, relates to PH edema and outcome in deep ICH
Aksoy et al., 2013	ICH(25); deep(8), lobar(12), both(1), Cerebellar(4)	Same sample, non-affected hemisphere	More severe BBB leakage around larger hematomas and in lobar ICH
Alvarez-Sabin et al., 2004	Spontaneous ICH(21)	Healthy controls(38-62)	MMP-9 associated with PH edema
Hernandez-Guillamon et al., 2012	CAA-related acute(33) and chronic(15) ICH	Healthy controls(21)	MMP-9 increased in PH brain tissue and MMP-2 also in Aβ-affected vessels but not in plasma levels
	CAA-related ICH(6)	Healthy controls(6)	
Lampl et al., 2005	Spontaneous ICH(27); deep(21) and lobar(6)	Same sample, non-affected hemisphere	BBB disruption associated with functional outcome
Lee et al., 2007	SHRsp(10)	None	BBB disruption preceded ICH both spatially and temporally
CAA			
Bonda et al., 2007	AD-Severe CAA(3)	AD (11), non-demented controls(7)	IgG leakage in CAA and non-CAA AD
Clifford et al., 2008	AD-CAA(24)	Healthy controls(8)	Decreased VSMC viability and leaking of plasma components in CAA
Del Valle et al., 2011	SAMP8 mice(24)	ICR-CD1 control mice(24)	BBB disruption associated with but not restricted to Aβ-affected vessels
Goos et al., 2012	AD with MB(26)	AD without MB(26), VaD(11) and cognitively normal subjective complainers(22)	No increased albumin ratio in CAA
Gonzales-velasquez et al., 2008	Aβ-treated human cerebral EC culture	Negative- and positive-treated human cerebral EC culture	Aβ treatment causes dose-dependent BBB permeability
Hartz et al., 2012*	hAPP mice(20)	WT mice(20)	Aβ reduces MMP- and TJ protein expression and increases efflux rate
	Aβ-treated rat cerebral microvessels	untreated rat cerebral microvessels	
Merlini et al., 2011	hAPP mice(n/s), Astrocytes isolated from hAPP mice	Non-transgenic mice(n/s), Astrocytes isolated from non-transgenic mice	Decreased GLUT-1 expression and glucose transport. Damaged astrocytes, BBB leakage and loss of VSMCs precede Aβ plaque formation in transgenic animals
van Assema et al., 2012	AD with MB(6)	AD without MB(12)	No additional Pgp dysfunction in CAA

Table 2: Study population and main findings (continued)

Study	*Study sample(n)*	*Control group(n)*	*Main findings*
Vorbrodt et al., 1997	Plaque forming scrapie-infected mice(6)	Non-plaque forming scrapie infected mice(3)	BBB disruption not directly related to Aβ vessels
Zipser et al., 2007	AD-CAA(20)	AD-no CAA(63) and HC(10)	No elevated prothrombin in CAA
Capillary CAA			
Carrano et al., 2011	AD-capCAA(6)	Non-demented controls(2)	Aβ is toxic to cerebral ECs by inducing ROS production, which is associated with disruption of TJs
	Aβ-treated human cerebral EC culture	Negative-treated human cerebral EC culture	
Carrano et al., 2012	AD-capCAA(23), affected vessels	Same sample, non-affected vessels	Aβ-related BBB disruption, associated with neuro-inflammation
HV			
Al-Awadi et al., 2006	SHR(n/s)	Normotensive WKY rats(n/s)	GABA transport (influx and efflux) is greater in hypertensive rats, but its homeostasis is not altered.No increased leakage in hypertensive animals
Al-Saraff et al., 2003	SHR(n/s)	Normotensive WKY rats(n/s)	Disrupted TJ in hypertension, salt diet affects neurovascular unit in all animals
Bailey et al., 2011	SHRsp(20)	Normotensive WKY rats(20)	Stroke susceptibility related to protein changes that link to ischemia, angiogenesis and BBB integrity
Bergerat et al., 2011	Stroke susceptible Dahl-S rats(11)	Non stroke susceptible Dahl-S rats(15)	BBB disruption associated with erythrocyte accumulations
Braun et al., 2012	SHRsp(94)	Normotensive WKY rats(37)	
Candelario-Jalil et al., 2011	VCI patients(45)	Control subjects(20)	Decreased MMP-2 index and increased MMP-3 activity in CSVD patients. MMP-2 associated with BBB leakage
Fredriksson et al., 1985	SHRspR(18)	Normotensive WKY(3) and Sprague-Dawley rats(2)	Plasma protein leakage in some hypertensive animals, accompanied by neuropathology
Fredriksson et al., 1987	SHRsp(42)	Normotensive WKY rats(15)	BBB disruption increased by high-salt diet and associated with brain edema
Fredriksson et al., 1988a	SHR(5), SHRsp(22)	Normotensive WKY rats(6), Sprague-Dawley rats(4)	BBB damage and not ischemia is the primary pathogenic mechanism underlying hypertension related neural damage
Fredriksson et al., 1988b	SHRsp(28)	Normotensive WKY rats(9)	Acute BBB damage marked by, enlarged astrocytes and gliosis occurs at more chronic stage

Table 2: Study population and main findings (continued)

Study	*Study sample(n)*	*Control group(n)*	*Main findings*
Fredriksson et al., 1988c	SHR(5), SHRsp(18)	Normotensive WKY rats(9)	BBB damage in rats with abnormally high blood pressure, surrounded by enlarged perivascular spaces
Gentile et al., 2009	Hypertensive (TAC) C57B1/6 mice(40)	Normotensive C57B1/6(20)	Chronic hypertension related to BBB damage with co-localized Aβ brain deposition
Hassan et al., 2003	CSVD patients(110)	Control subjects(50)	Higher plasma marker levels compared with controls.NB independent of hypertension
Hatzinikolaou et al., 1981	Hypertensive WKY rats(21)	Normotensive WKY rats(11)	Moderate correlation between tyrosine leakage and blood pressure
Ishida et al., 2006	SHRsp(20)	Normotensive WKY rats(20)	Altered protein expression and decreased mRNA expressions related to hypertension
Iwanaga et al., 2008	Isolated cerebral microvessels from SHRsp(11)	Isolated cerebral microvessels from Normotensive WKY rats(11)	Increased osteopontin expression in glial cells associated with hypertension-related BBB damage
Kang et al., 1990	SHRsp(55)	Normotensive WKY rats(54)	Hypertension associated with dysfunction in choline transport, no increased sucrose leakage
Kemper et al., 2001	Hypertensive rhesus monkeys(12)	Normotensive rhesus monkeys(9)	Fibrinogen leakage apparent in hypertensive animals, associated with glial accumulation
Knox et al., 1980	SHR(14)	Normotensive WKY(15) and Sprague-Dawley rats(14)	Leakage restricted to the vessel wall and perivascular cells
Lightman et al., 1987	SHR(6)	Normotensive WKY rats(6)	BBB in chronic hypertensive animals appears intact
Lippoldt et al., 2000	SHRsp(9)	SHR(9), Normotensive WKY rats(9)	No clear BBB damage but subtle alterations in hypertensive animals
Mayhan et al., 1987	SHRsp(17)	Normotensive WKY rats(14)	Attenuated effect of acute blood pressure elevation in venules of chronic hypertensive animals
Mueller et al., 1980	SHR(13)	Normotensive WKY(12)	No BBB disruption associated with chronic hypertension, less susceptibility to disruption following acute blood pressure elevation compared with controls
Nag., 1996	Hypertensive WKY rats(18)	Normotensive WKY(9)	BBB alterations associated with hypertension, BBB leakage only in animals with abnormally high hypertension
Rodrigues et al., 2012*	Hypertensive (DOCA salt) C57B1/6 mice(5)	Normotensive C57B1/6 mice(5)	No BBB leakage in hypertensive animals
Rodrigues et al., 2013	Hypertensive (DOCA salt) C57B1/6 mice(9), hypertensive Ang II C57BL/6 mice(24)	(all C57B1/6 and normotensive) intact mice(18), uniphrectomized mice(13)	BBB leakage only in particular model of hypertension, effect blunted by high cholesterol diet
Rouhl et al., 2012	Lacunar stroke patients(163), hypertensive patients(183)	Control subjects(43)	Alterations in BBB in form of higher plasma marker levels associated with HV manifestations

Table 2: Study population and main findings (continued)

Study	*Study sample(n)*	*Control group(n)*	*Main findings*
Schreiber et al., 2012	SHRsp(51)	Normotensive WKY rats(12)	BBB disruption precedes HV manifestations, increases with age
Sironi et al., 2004	SHRsp(41)	SHR(45), Normotensive WKY rats(45)	BBB disruption in HV, associated with macrophage and lymphocyte accumulation
Tagami et al., 1987	SHRsp with stroke symptoms(24)	Asymptomatic SHRsp(60)	BBB disruption in HV in form of plasma protein leakage,monocyte accumulation and VSMC loss
Takemori et al., 2000*	SHRsp(21)	Normotensive WKY rats(7)	Higher EC adhesion molecule (ICAM-1) and leucocyte molecule (Mac-1) expression in hypertensive animals
Takemori et al., 2013	SHRsp(30)	Normotensive WKY rats(30)	Increased expression of BBB-related molecules in HV, associated with elevated oxidative stress
Tang et al., 1993	SHR(13)	Normotensive Sprague-Dawley rats(14)	Elevated brain uptake of amino acids associated with hypertension
Topakian et al., 2010	CSVD patients(24)	Control subjects(15)	Increased BBB permeability in SVD patients, also in normal appearing brain tissue
Toth et al., 2013	Hypertensive (ANG-II infused) C57/BL6 mice(80)	Normotensive C57/BL6 mice(80)	Aging exacerbates hypertension related BBB disruption
Ueno et al., 2004	SHRsp(5), SHR(5)	Normotesive WKY rats(5)	BBB disruption in the hypothalamus associated with hypertension
Wardlaw et al., 2009	Lacunar stroke patients(51)	Cortical stroke patients(46)	Altered BBB integrity in CSVD compared with large vessel disease (cortical stroke) patients
Wardlaw et al., 2013	Lacunar and cortical stroke patients(70)	None	Local BBB disruption relates to poor functional outcome
Werber et al., 1988	SHR(10), hypertensive two-kidney 1 clip Goldblatt rats(10), DOCA and NaCl treated rats(7), Dahl salt-sensitive rats fed high salt diet(8)	Normotensive WKY rats(10) and Dahl salt-sensitive rats fed low salt diet(10)	No BBB damage associated with chronic hypertension, less susceptibility to leakage following acute blood pressure elevation compared with controls depending on animal model
Yamagata et al., 1997	Astrocytes isolated from SHRsp co-cultured with endothelial cells	Astrocytes isolated from normotensive WKY rats co-cultured with endothelial cells	Astrocytes isolated from HV animals induce altered BBB abilities
Zhang et al., 2010	Hypertensive (ANG-II infused) C57/BL6 mice(6)	Normotensive C57/BL6 mice(6)	BBB disruption and increased leukocyte adhesion in chronic hypertension

ICH, intracerebral haemorrhage; CAA, cerebral amyloid angiopathy; HV, hypertensive vasculopathy; AD, Alzheimer's disease; MB, microbleeds; SHR, spontaneously hypertensive rats; SHRsp, stroke-prone spontaneously hypertensive rats; WKY, Wistar Kyoto; CSVD, cerebral small vessel disease; VCI, vascular cognitive impairment; ANG-II, angiotensin-II; DOCA, deoxycorticosterone acetate; Aβ, amyloid-beta; hAPP, human amyloid precursor protein

*Only parts of the study that were eligible for inclusion were considered in this review

Discussion

This systematic analysis includes 59 papers concerning the role of BBB disruption in spontaneous ICH and its main underlying disease processes, CAA and HV. The literature in this review provides evidence that supports a role for BBB disruption in the etiology of spontaneous ICH. This disruption likely already develops in small vessel diseases that are responsible for the eventual vessel rupture, since the majority of CAA and HV studies indicate alterations in BBB integrity in these small vessel disorders.

Data on BBB disruption in ICH is scarce as this is a challenging field of studies. Although the retrospective nature of many human studies makes studying the contribution of a disrupted BBB in pathological events leading to a bleeding difficult, all studies in this review support a role for BBB damage in spontaneous ICH. The one prospective animal study found rather strong evidence for a role of BBB disruption in the etiology of HV-related ICH as BBB alterations showed a clear temporal and spatial relationship with ICH occurrence (Lee et al., 2007). Interestingly, the discovery of altered MMP expression in Aβ-affected vessels distant from the acute ICH also suggests a possible pathogenic role for BBB disruption in CAA-related ICH (Hernandez-Guillamon et al., 2012). Moreover, slight BBB leakage in the intact hemisphere of ICH patients suggests that a global BBB disruption related to CSVD processes may be apparent (Aksoy et al., 2013). The etiology of BBB-associated vessel fragility may differ for HV- and CAA- related ICH. Several hints for such distinct mechanisms were found by studies showing different manifestations of BBB disruption in lobar and deep ICH, including elevated BBB permeability around lobar compared with nonlobar ICH, and an association between MMP-9 and perihematoma edema volume in nonlobar, but not in lobar ICH (Abilleira et al., 2003; Aksoy et al., 2013). Unfortunately it remains unknown whether these differences can be explained by location or vasculopathy related heterogeneities as these *in vivo* human studies did not pathologically confirm small vessel disease.

Most studies do indicate an association between CAA and BBB disruption. However, a prominent problem in CAA research is the current absence of direct means to reliably assess CAA in living humans. *In vivo* studies in this review address the number of lobar MBs as a measure reflecting underlying CAA. However, as CAA is not systematically associated with MBs and increasingly prevalent with advancing age, it is difficult to establish a valid control group for this. Resulting insufficient classification of CAA may account for the absence of a specific relationship between BBB alterations and CAA in the two human *in vivo* studies in this review (Goos et al., 2012; van Assema et al., 2012). An even more general difficulty that applies to almost all CAA studies is the high correlation between CAA and AD pathology. Both CAA and AD have similar pathology which likely develops many years before the onset of clinical symptoms, and therefore it is very difficult to set apart the distinct correlates of these disease processes. As a result, many studies lack an adequate control group to measure the 'pure' effects of CAA (Bonda et al., 2007; Carrano et al., 2011; Clifford et al., 2008; Vorbrodt et al., 1997).

An interesting question that arises from the literature is whether CAA pathology is a cause or a consequence of BBB alterations. Both of these hypotheses were raised by the included studies. Three studies stated that excess Aβ leads to increased BBB permeability (Carrano et al., 2011; Carrano et al., 2012; Gonzales-Velasquez et al., 2008). In contrast, three other studies favor the hypothesis which states that BBB disruption leads to vessel Aβ deposition instead of the other way

around (Bonda et al., 2007; del Valle et al., 2008; Merlini et al., 2012). As these speculations are predominantly based on retrospective or *in vitro* approaches, the evidence for causality in both hypotheses is not convincing, and as such the exact source that induces CAA-related BBB disruption remains to be discovered. A candidate for future research in this is the apolipoprotein E (APOE) genotype, which is an important risk factor for CAA and lobar ICH (Charidimou et al., 2012; Martini et al., 2012). The APOE genotype is also implicated in AD and this may explain the absence of differences in BBB integrity between CAA with and without concomitant AD in some studies (Bonda et al., 2007; Goos et al., 2012; van Assema et al., 2012; Zipser et al., 2007).

The evidence for BBB disruption in HV converges towards the conclusion that a relationship between HV and BBB disruption is clearly apparent, since most human and animal studies indicate a relationship between HV and BBB integrity. Because a broad range of study samples and techniques was used, direct comparison of studies is difficult. On the other hand, the broad character of the evidence indicates a universal relationship between HV and BBB disruption across different species and on different measurement levels, from alterations in mRNA expression towards leakage of large proteins through tight junctions, the gatekeepers of the BBB. An important advantage in the HV animal studies is the availability of hypertensive animal models. This is reflected by the large number of animal studies in HV as compared with CAA or ICH studies. The prospective nature of the HV animal studies determines a causal relationship between hypertension and BBB disruption. Several studies suggest that impaired autoregulatory mechanisms resulting from chronic hypertension may play a role in this disruption (Schreiber et al., 2012; Toth et al., 2013). Some difficulties in HV research present in human studies, which are often retrospective with unknown history of hypertension and/or history of other vascular risk factors. These studies thereby disregard the possible influence of mediating factors. This may induce bias as the results may not represent the primary effects of hypertension. Interestingly, animal studies pointed out several factors that exacerbate BBB disruption in chronic hypertension, including aging, genetic risk factors, high salt diet, and ultra-high systolic blood pressures. Another factor found to attenuate BBB disruption was a high cholesterol diet. This protective effect of hypercholesterolemia in HV-related ICH was also indicated by a recent review on differences in risk factors between lobar and non-lobar ICH (Martini et al., 2012).Taking a closer look at hypertension history and risk factors for BBB damage is an important consideration for future research and may be useful in pointing out individuals particularly at risk for ICH.

Both studies on amyloid angiopathy and hypertension indicate a relationship between BBB disruption and inflammation. In CAA studies the evidence for this was limited to two studies that suggested that excess Aβ in microvessels causes a neuro-inflammatory response which leads to BBB disruption (Carrano et al., 2011; Carrano et al., 2012), and one other study that described swelling of astrocytes and retraction of their endfeet in transgenic CAA-mice (Merlini et al., 2012). HV studies on the other hand found more elaborate evidence for inflammation in relation to BBB leakage by indicating plasma markers of inflammation (Candelario-Jalil et al., 2011; Hassan et al., 2003; Rouhl et al., 2012). Moreover, increased accumulation of leukocytes (Zhang et al., 2010), monocytes (Tagami et al., 1987), and macrophages and lymphocytes (Sironi et al., 2004) was shown in HV animal models as well as presence of reactive astrocytes and microglia in leaking regions (Kemper et al., 2001). Interestingly, three HV animal studies found increased expression of AQP-4 molecules by astrocytes, which are thought to regulate edema formation (Bergerat et al., 2011; Ishida et al., 2006; Takemori et al., 2013). This might be worth exploring further as perivascular formation of edema may contribute to vessel damage and eventual rupture. Although comparison of CAA and HV studies is

difficult due to differences in methodology, one interesting parallel finding is that decreased MMP-2 plasma levels were characteristic to CSVD patients (Candelario-Jalil et al., 2011), while a similar trend for low MMP-2 plasma levels was found in CAA-related ICH patients (Hernandez-Guillamon et al., 2012). However, as approximately half of the CAA-ICH group exhibited hypertension it is unknown whether these plasma markers are related to BBB disruption in general or typically inherent to HV.

Since BBB disruption has been indicated to relate to neuronal loss, it may not be surprising that it was found to match patterns of cognitive decline (Kemper et al., 2001). Since cognitive decline also characteristic to HV and CAA (Charidimou et al., 2012; Wardlaw et al., 2010), a relevant question for future research would be to what extent BBB disruption contributes to cognitive decline in CSVD. Similarly, this question can be extended to dementias, including Alzheimer's disease as a parallel for advanced CAA, and vascular dementia as parallel for advanced HV, as several hints for BBB disruption in these types of dementia have been found (Farrall et al., 2009). Apart from its impact on cognition, the significance of BBB is further underlined by several studies that point out its predictive value on future patient outcome. Studies in this writing indicate that BBB disruption predicts neurological worsening and mortality in the acute stage following ICH (Alvarez-Sabin et al., 2004; Abilleira et al., 2003), functional outcome at 6 months post ICH (Lampl et al., 2005), as well as functional outcome in lacunar and cortical stroke after 3 years. The clinical relevance of integrity of the BBB structure should not be overlooked and deserves more attention.

This paper provides a comprehensive overview on BBB disruption in ICH, CAA and HV based on consideration of a large quantity of studies on human and animal study samples with *in vivo,* post-mortem, and *in* vitro approaches. However, there are some limitations. Small sample sizes restrict statistical power, and the retrospective design of many human studies prevents distinguishing cause from consequence. Moreover, HV and CAA probably often co-occur and may be difficult to distinguish, especially in human *in vivo* studies, due to the inability to confirm small vessel vasculopathy. Because it is difficult to measure BBB disruption in humans *in vivo* this type of study design is scarce, and it should be noted that results yielded by human post-mortem, human *in vitro*, and animal studies may not be directly generalizable to a human *in vivo* situation. Furthermore, selected studies were restricted to those in English, and the terms 'endothelial' and 'bleeding' were not included in the search, thus some relevant papers may have been skipped. Publication bias may be present as studies with negative results may be under-reported.

Overall, despite the emergence of some interesting clues, the challenge of unraveling the mechanisms underlying ICH in relation to BBB disruption and different vasculopathies seems far from completed. Further prospective research, preferably in humans, with the use of adequate control groups and assessment of possible mediating influences is needed in order to clarify the role of BBB disruption in CSVD processes and spontaneous ICH. Plasma marker techniques are a rather indirect measure for BBB disruption and imaging techniques such as DCE-MRI are therefore preferred because the leakage sites can be spatially localized. In addition, another key feature for future studies is the use of translational research. Combining prospective studies in animals with human post-mortem and prospective *in vivo* studies may yield important insights that cannot currently be achieved in each study type separately. Future studies should establish study designs with comparable study groups of sufficiently large size and apply equal methods to all groups to assess whether there are any differences apparent in CAA- and HV- related BBB disruption.

References

Abilleira S, Montaner J, Molina CA, Monasterio J, Castillo J, Alvarez-Sabin J. Matrix metalloproteinase-9 concentration after spontaneous intracerebral hemorrhage. Journal of Neurosurgery 2003;99:65-70.

Aksoy D, Bammer R, Mlynash M, Venkatasubramanian CV, Eyngorn I, Snider RW et al. Magnetic resonance imaging profile of blood-brain barrier injury in patients with acute intracerebral hemorrhage. Journal of the American Heart Association 2013;2(3):e000161.

Al-Awadi M, Pavlik A and Al-Sarraf H. Increased brain uptake and blood to blood efflux transport of ^{14}C-GABA in spontaneously hypertensive rats. Life Sciences 2004;79:847-853.

Al-Sarraf H and Philip L. Effect of hypertension on the integrity of blood brain and blood CSF barriers, cerebral blood flow and CSF secretion in the rat. Brain Research 2003;975:179-188.

Alvarez-Sabin J, Delgado P, Abilleira S, Molina CA, Arenillas J, Ribo M et al. Temporal profile of matrix metalloproteinases and their inhibitors after spontaneous intracerebral hemorrhage: Relationship to clinical and radiological outcome. Stroke 2004;35:1316-1322.

Bailey EL, Wardlaw JM, Graham D, Dominiczak AF, Sudlow CLM and Smith C. Cerebral small vessel endothelial structural changes predate hypertension in stroke-prone spontaneously hypertensive rats: a blinded, controlled immunohistochemical study of 5- to 21-week-old rats. Neuropathology and Applied Neurobiology 2011;37:711-726.

Bergerat A, Decano J, Wu CJ, Choi H, Nesvizhskii AI, Moran AM et al. Prestroke proteomic changes in cerebral microvessels in stroke-prone, Transgenic(hCETP)-Hyperlipidemic, Dahl salt-sensitive hypertensive rats. Molecular Medicine 2011;17(7-8):588-598.

Bonda DJ, Webber KM, Siedlak SL, Perry G, Friedland RP and Smith MA. The pathology of Alzheimer Disease elicits an in vivo immunological response. American Journal of Immunology 2007;3(1):10-14.

Braun H, Bueche CZ, Garz C, Oldag A, Heinze HJ, Goertler M et al. Stases are associated with blood-brain barrier damage and a restricted activation of coagulation in SHRSP. Journal of the Neurological Sciences 2012;322:71-76.

Candelario-Jalil E, Thompson J, Taheri S, Grossete M, Adair JC, Edmonds E et al. Matrix metalloproteinases are associated with increased blood-brain barrier opening in vascular cognitive impairment. Stroke 2011;42:1345-1350.

Carrano A, Hoozemans JJM, van der Vies SM, van Horssen J, de Vries HE and Rozemuller AJM. Neuroinflammation and blood-brain barrier changes in capillary amyloid angiopathy. Neurodegenerative Dis 2012;10:329-331.

Carrano A, Hoozemans JJM, van der Vies SM, Rozemuller AJM, van Horssen J and de Vries HE. Amyloid beta induces oxidative stress-mediated blood-brain barrier changes in capillary amyloid angiopathy. Antioxidants & Redox Signaling 2011;15(5):1167-1178.

Charidimou A, Gang Q, WErring DJ. Sporadic cerebral amyloid angiopathy revised: recent insights into pathophysiology and clinical spectrum. J NEurol Neuosurg Psychiatry 2012;83:124-37.

Clifford PM, Siu G, Kosciuk M, Levin EC, Venkataraman V, D'Andrea MR et al. A7 nicotinic acetylcholine receptor expression by vascular smooth muscle cells facilitates the deposition of Aβ peptides and promotes cerebrovascular amyloid angiopathy. Brain Research 2008;1234:158-171.

Del Valle J, Duran-Vilaregut JD, Manich G, Pallas M, Camins A, Vilaplana J et al. Cerebral amyloid angiopathy, blood-brain barrier disruption and amyloid accumulation in SAMP8 mice. Neurodegenerative Diseases 2011;8:421-429.

Dietrich, 2002. The adhesion molecule ICAM-1 and its regulation in relation with the blood-brain barrier. J Neuroimmunol 2002;128(1-2):58-68.

Farrall AJ, Wardlaw JM. Blood-brain barrier: Ageing and microvascular disease-systematic review and meta-analysis. Neurobiology of Aging 2009;30:337-352.

Florczak-Rzepka M, Grond-Ginsbach C, Montaner J And Steiner T. Matrix metalloproteinases in human spontaneous intracerebral hemorrhage: An update. Cerebrovascular Diseases 2012;34:249-262.

Fredriksson K, Auer RN, Kalimo H, Nordborg C, Olsson Y and Johansson BB. Cerebrovascular lesions in stroke-prone spontaneously hypertensive rats. Acta Neuropathologica 1985;68:284-294.

Fredriksson K, Kalimo H, Nordborg C, Johansson BB and Olsson Y. Nerve cell injury in the brain of stroke-prone spontaneously hypertensive rats. Acta Neuropathologica 1988(a);76:277-237.

Fredriksson K, Kalimo H, Nordborg C, Olsson Y and Johansson BB. Cyst formation and glial response in the brain lesions of stroke-prone spontaneously hypertensive rats. Acta Neuropathologica 1988(b);76:441-450.

Fredriksson K, Kalimo H, Westergren I, Kahrström J and Johansson BB. Blood-brain barrier leakage and brain edema in stroke-prone spontaneously hypertensive rats; Effect of chronic sympathectomy and low protein/high salt diet. Acta Neuropathologica 1987;74:259-268.

Fredriksson K, Nordborg C, Kalimo H, Olsson Y and Johansson BB. Cerebral microangiopathy in stroke-prone spontaneously hypertensive rats; An immunohistochemical and ultrastructural study. Acta Neuropathologica 1988;75:241-252.

Gentile MT, Poulet R, Di Pardo A, Cifelli G, Maffei A, Vecchione C et al. β-Amyloid deposition in brain is enhanced in mouse models of arterial hypertension. Neurobiology of Aging 2009;30:222-228.

Gonzalez-Velasquez FJ, Kotarek JA and Moss MA. Soluble aggregates of the amyloid-β protein selectively stimulate permeability in human brain microvascular endothelial monolayers. Journal of Neurochemistry 2008;107:466-477.

Goos JDC, Teunissen CE, Veerhuis R, Verwey NA, Barkhof , Blankenstein MA et al. Microbleeds relate to altered amyloid-beta metabolism in Alzheimer's disease. Neurobiology of Aging 2012;33:1011.e1-1011.e9.

Greenberg SM, Gurol ME, Rosand J and Smith EE. Amyloid angiopathy-related vascular cognitive impairment. Stroke 2004;35(11Suppl1);2616-9.

Gregoire SM, Charidimou A, Gadapa N, Dolan E, Antoun N, Peeters A et al. Acute ischaemic brain lesions in intracerebral haemorrhage: multicenter cross-sectional magnetic resonance imaging study. Brain 2011;134:2376-2386.

Grinberg LT and Thal DR. Vascular pathology in the aged human brain. Acta Neuropathol 2010;119:277-290.

Hartz AMS, Bauer B, Soldner ELB, Wolf A, Boy S, Backhaus R et al. Amyloid-β contributes to blood-brain barrier leakage in transgenic human amyloid precursor protein mice and in humans with cerebral amyloid angiopathy. Stroke 2012;43:514-523.

Hassan A, Hunt BJ, O'Sullivan M, Parmar K, Bamford JM, Briley D et al. Markers of endothelial dysfunction in lacunar infarction and ischaemic leukoaraiosis. Brain 2003;126:424-432.

Hatzinikolaou P, Brecher P and Gavras H. Chronic hypertension increases tyrosine transport across the blood-brain barrier in the rat. Life Sciences 1981;29:1657-1660.

Hernandez-Guillamon M, Martinez-Saez E, Delgado P, Dominguies-Montanari S, Boada C, Penalba A et al. MMP-2/MMP-9 plasma level and brain expression in cerebral amyloid angiopathy-associated hemorrhagic stroke. Brain Pathology 2012;22:133-141.

Ishida Hm Takemori K, Dote K and Ito H. Expression of glucose transporter-1 and aquaporin-4 in the cerebral cortex of stroke-prone spontaneously hypertensive rats in relation to the blood-brain barrier function. American Journal of Hypertension 2006;19:33-39.

Iwanaga Y, Uenot M, Ueki M, Huang CL, Tomita S, Okamoto Y et al. The expression of osteopontin is increased in vessels with blood-brain barrier impairment. Neuropathology and Applied Neurobiology 2008;34:145-154.

Kang YS, Terasaki T and Tsuji A. Dysfunction of choline transport system through blood-brain barrier in stroke-prone spontaneously hypertensive rats. J. Pharmacobio-Dyn 1990;13:10-19.

Kemper TL, Blatt GJ, Killiany RJ and Moss MB. Neuropathology of progressive cognitive decline inchronically hypertensive rhesus monkeys. Acta Neuropathologica 2001;101:145-153.

Knox CA, Yates RD, Chen II and Klara PM. Effects of aging on the structural and permeability characteristics of cerebrovasculature in normotensive and hypertensive strains of rats. Acta Neuropathologica 1980;51:1-13.

Lampl Y, Shmuilovich O, Lockman J, Sadeh M and Lorberboym M. Prognostic significance of blood brain barrier permeability in acute hemorrhagic stroke. Cerebrovascular Diseases 2005;20:433-437.

Lee JM, Zhai G, Liu Q, Gonzales ER, Yin K, Yan P et al. Vascular permeability precedes spontaneous intracerebral hemorrhage in stroke-prone spontaneously hypertensive rats. Stroke 2007;38:3289-3291.

Lightman S, Rechthand E, Latker C, Palestine A and Rapoport S. Assessment of the permeability of the blood-retinal barrier in hypertensive rats. Hypertension 1987;10:390-395.

Lippoldt A, Kniesel U, Liebner S, Kalbacher H, Kirsch T, Wolburg H et al. Structural alterations of tight junctions are associated with losso f polarity in stroke-prone spontaneously hypertensive rat blood-brain barrier endothelial cells. Brain Research 2000;85:251-261.

Martini SR, Flaherty ML, Brown WM, Haverbusch M, Comeau ME, Sauerbeck LR et al. Risk factors for intracerebral hemorrhage differ according to hemorrhage location. Neurology 2012;79:2275-2282.

Mayhan WG, Faraci FM and Heistad DD. Mechanisms of protection of the blood-brain barrier during acute hypertension in chronically hypertensive rats. Hypertension 1987;9(6):1985-1990.

Mehndiratta P, Manjila S, Ostergard T, Eisele S, Cohen ML, Sila C and Selman WR. Cerebral amyloid angiopathy-associated intracerebral hemorrhage: pathology and management. Neurosurg Focus 2012;32(4);E7.

Merlini M, Meyer EP, Ulmann-Schuler A and Nitsch RM. Vascular β-amyloid and early astrocyte alterations impair cerebrovascular function and cerebral metabolism in transgenic arcAβ mice. Acta Neuropathologica 2011;122:293-311.

Mueller SM and Heistad DD. Effect of chronic hypertension on the blood-brain barrier. Hypertension 1980;2:809-812.

Nag S. Immunohistochemical localization of extracellular matrix proteins in cerebral vesels in chronic hypertension. Journal of Neuropathology and Experimental Neurology 1996;55(3):381-388.

Pelisch N, Hosomi N, Ueno M, Nakano D, Hitomi H, Mogi M et al. Blockade of AT1 receptors protects the blood-brain barier and improves cognition in Dahl Salt-Sensive hypertensive rats. American Journal of Hypertension 2011;24(3):362-368.

Qureshi AI, Mendelow AD and Hanley DF. Intracerebral haemorrhage. Lancet 2009;373(9675):1632-1644.

Rodrigues SF and Granger DN. Cerebral microvascular inflammation in DOCA salt-induced hypertension: role of angiotensin II and mitochondrial superoxide. Journao of Cerebral Blood Flow and Metabolism 2012;32:368-375.

Rodrigues SF, Vital SA and Granger DN. Mild hypercholesterolemia blunts the proinflammatory and prothrombotic effects of hypertension on the cerebral microcirculation. Journal of Cerebral Blood Flow and Metabolism 2013;33:483-489.

Rosenberg GA, Estrada E, Dencoff JE. Matrix metalloproteinases and TIMPs are associated with blood-brain barrier opening after reperfusion in rat brain. Stroke 1998;29:2189-2195.

Rouhl RPW, Damoiseauz JGMC, Lodder J, Theunissen ROMFIH, Knottnerus ILH, Staals J et al. Vascular inflammation in cerebral small vessel disease. Neurobiology of Aging 2012;33:1800-1806.

Schreiber S, Bueche CZ, Garz C, Kropf S, Angenstein F, Goldschmidt J et al. The pathologic cascade of cerebrovascular lesions in SHRSP: is erythrocyte accumulation an early phase? Journal of Cerebral Blood Flow and Metabolism 2012;32:278-290.

Sironi L, Guerrini U, Tremoli E, Miller I, Gelosa P, Lascialfari A et al. Analysis of pathological events at the onset of brain damage in stroke-prone rats: A proteomics and magnetic resonance imaging approach. Journal of Neuroscience Research 2004;78:115-122.

Tagami M, Nara Ym Kubota A, Sunaga T, Maezawa H, Fujino H and Yamori Y. Ultrastructural characteristics of occluded perforating arteries in stroke-prone spontaneously hypertensive rats. Stroke 1987;18:733-740.

Tagemori K, Ito H and Suzuki T. Effects of the AT1 receptor antagonist on adhesion molecule expression in leukocytes and brain microvessels of stroke-prone spontaneously hypertensive rats. American Journal of Hypertension 2000;13:1233-1241.

Takemori K, Murakami T, Kometani T and Ito H. Possible involvement of oxidative stress as a causative factor in blood-brain barrier dysfunction in stroke-prone spontaneously hypertensive rats. Microvascular Research 2013;90:167-172.

Tang JP, Xu ZQ, Douglas FL, Rakhit A and Melethil S. Increased blood-brain barrier permeability of amino acids in chronic hypertension. Life Sciences 1993;53:417-420.

Thal DR, Ghebremedhin E, Yamaguchi H, Del Tredici K and Braak H. Two types of sporadic cerebral amyloid angiopathy. Journal of Neuropathology and Experimental Neurology 2002;61:282-293.

Topakian R, Barrick TR, Howe FA and Markus HS. Blood-brain barrier permeability is increased in normal-appearing white matter in patients with lacunar stroke and leucoaraiosis. J Neurol Neurosurg Psychiatry 2010;81:192-197.

Toth P, Tucsek Z, Sosnowska D, Gautam T, Mitschelen M, Tarantini S et al. Age-related autoregulatory dysfunction and cerebromicrovascular injury in mice with angiotensin II-induced hypertension. Journal of Cerebral Blood Flow and Metabolism 2013;33:1732-1742.

Ueno M, Sakamoto H, Liao YJ, Onodera M, Huang CL, Miyanaka H et al. Blood-brain barrier disruption in the hypothalamus of young adult spontaneously hypertensive rats. Histochem Cell Biol 2004;122:131-137.

Van Asch CJJ, Luitse MA, Rinkel GJE, van der Tweel I, Algra A, Klijn CJM. Incidence, case fatality, and functional outcome of intracerebral haemorrhage over time, according to age, sex, and ethnic origin: a systematic review and meta-analysis. Lancet Neurology 2010;9:167-76.

Van Assema DME, Goos JDC, van der Flier WM, Lubberink M, Boellaard R, Windhorst AD et al. No evidence for additional blood-brain barrier P-glycoprotein dysfunction in Alzeimer's disease patients with microbleeds. Journal of Cerebral Blood Flow and Metabolism 2012;32:1468-1471.

Vinters HV. Cerebral amyloid angiopathy. A critical review. Stroke 1987;18:311-24.

Vorbrodt AW, Dobrogowska DH, Tarnawski M, Meeker HC and Carp RI. Immunocytochemical evaluation of blood-brain barrier to endogenous albumin in scrapie-infected mice. Acta Neuropathologica 1997;93:341-348.

Wardlaw JM. Blood-brain barrier and cerebral small vessel disease. Journal of the Neurological Sciences 2010;299:66-71.

Wardlaw JM, Doubal F, Armitage P, Chappell F, Carpenter T, Maniega SM et al. Lacunar stroke is associated with diffuse blood-brain barrier dysfunction. Annals of Neurology 2009;65:194-202.

Wardlaw JM, Doubal FN, Valdes-Hernandez M, Wang X, Chappell FM, Shuler K et al. Blood-brain barrier permeability and long-term clinical and imaging outcomes in cerebral small vessel disease. Stroke 2013;44:525-527.

Werber AH and Fitch-Burke MC. Effect of chronic hypertension on acute hypertensive disruption of the bloo-brain barrier in rats. Hypertension 1988;12:549-555.

Yamagata K, Tagami M, Nara Y, Fujino H, Kubota A, Numano F et al. Faulty induction of blood-brain barrier functions by astrocytes isolated from stroke-prone spontaneously hypertensive rats. Clinical and Experimental Pharmacology and Physiology 1997;24:686-691.

Yang Y, Estrada EY, Thompson JF, Liu W and Rosenberg GA. Matrix metalloproteinase-mediated disruption of tight junction proteins in cerebral vessels is reversed by synthetic matrix metalloproteinase inhibitor in focal ischemia in rat. Journal of Cerebral Blood Flow and Metabolism 2007;27:697-709.

Zhang M, Mao Y, Ramirez SH, Tuma RF and Chabrashvili T. Angiotensin II induced cerebral microvascular inflammation and increased blood-brain barrier permeability via oxidative stress. Neuroscience 2010;171:852-858.

Zipser BD, Johanson CE, Gonzalez L, Berzin TM, Tavares R, Hulette CM et al. Microvascular injury and blood-brain barrier leakage in Alzheimer's disease. Neurobiology of Aging 2007;28:977-986.

Supplementary table 1

Pubmed search string

(("intracerebral hemorrhage"[tiab] OR "intracerebral hematoma"[tiab]) AND "blood-brain barrier"[tiab]) OR ((hypertension[tiab] OR hypertensive[tiab] OR "small vessel disease"[tiab]) AND “blood-brain barrier”[tiab]) OR ("amyloid angiopathy"[tiab] AND "blood-brain barrier"[tiab])

Embase search string

'intracerebral hemorrhage':ab,ti OR 'intracerebral hematoma':ab,ti AND 'blood brain barrier':ab,ti OR (hypertension:ab,ti OR hypertensive:ab,ti OR 'small vessel disease':ab,ti AND 'blood-brain barrier':ab,ti) OR ('amyloid angiopathy':ab,ti AND 'blood brain barrier':ab,ti)

Dankwoord
Het schrijven van deze scriptie was een interessante en leerzame ervaring, waardoor ik in relatief korte tijd een stuk wijzer ben geworden. Ik verheug me erop om dat wat ik geleerd heb mee te nemen in mijn toekomstig promotieonderzoek.
Ik wil dr. Karin Klijn hartelijk bedanken voor het bieden van de kans om dit project uit te voeren onder haar begeleiding. Haar efficiënte feedback heeft me goed geholpen bij het inhoudelijk uitwerken en het structureren van de scriptie. Ook gaat mijn dank uit naar prof. dr. Geert Jan Biessels, voor het beoordelen van dit laatste onderdeel van mijn masterprogramma, evenals voor zijn begeleiding in de andere grote studieprojecten die ik met veel plezier heb uitgevoerd de afgelopen 2 jaar.

-