Pathological findings in stranded Common seals (*Phoca vitulina*) and Grey seals (*Halichoerus grypus*) in North-Holland including Texel, during 2009-2012.

Name: Stephanie Wigman

Student number: 3260275

June 4, 2012

September 21, 2012

Supervisor: Jooske IJzer, DVM, PhD, Veterinary Pathologist. Utrecht University, Faculty of Veterinary Medicine, Dept. Pathobiology.

Universiteit Utrecht

centrum
voor wadden en Noordzee
Texel

Inhoud

Summary

From 2009 till the first quarter of 2012, 150 seals (133 *Phoca vitulina* and 17 *Halichoerus grypus*) stranded in the province North Holland included Texel. These seals were found dead or died/euthanized at the rehabilitation center Ecomare. Necropsy was performed conform a protocol at the University Utrecht, Faculty of Veterinary Medicine. Dept. Pathobiology. Macroscopic, microscopic, immunohistochemical, microbiological and parasitological examinations were performed, to get information about the health status of the Dutch seal population.

The respiratory and alimentary systems were most commonly affected by pathological changes. Also trauma was seen on the seal carcasses, 56 seals had signs of blunt trauma but also in lesser extent sharp trauma and fractures were seen.

The respiratory tract: Pathological changes that were most commonly seen were nematodiasis (46.7%), pneumonia (36%) chiefly a bronchopneumonia and pulmonary edema (43.3%). Other important pathological findings were: pulmonary emphysema, pulmonary hyperemia and foam and/or fluid in the airways. The causes of pneumonia were lungworms (21.3%), bacteria (1.3%), unknown causes (7.3%) or both bacteria and lungworm (6%). Bacteria that were cultured out of the lungs were: *Streptococcus* species, *Escherichia coli*, *Clostridium*, *Gemella* species and mixed cultures.

The alimentary tract: Parasites were macroscopically found in the esophagus (13.3%), stomach (42.7%), intestines (26%), and liver (1.3%). The presence of parasites in the stomach was associated with hyperemic mucosa, ulceration of the stomach wall, thickened stomach wall and mucous, hemorrhagic or pica contents.
Pathological changes were commonly found on the liver, these changes were inflammatory (9.3%) by the bacteria *Streptococcus*, *Brucellosis*, *Escherichia coli* and mixed cultures, hepatomegaly (8%), and liver necrosis (8%).

Trauma: Blunt trauma (37.3%) was associated with haemorrhage and/or edema in the sub-cutis, blubber or muscles. Locations of blunt trauma were the chest (18%), head (14%), shoulders (10%) and neck (8.7%). Sharp trauma located mostly on the flippers (front 2.6%, back 1.3%). Skin lesions were found in 30 seals but this would probably be more, but due to scavenging no differentiation could be made. Also bone fractures (8.6%) were seen, mostly on the skull (4.7%).

The causes of death were euthanasia (26%), infectious cause (22.7%), unknown (19.3%), emaciation (13.3%), trauma (8.7%), by catch (4%) and other causes (6%).
In total 36.6% of the seals (mostly neonates and juveniles) died because of respiratory problems. 32 of these seals (21.3%) were euthanized in Ecomare. The other seals that died without human interference, died because of inflammation of only the lungs (11.3%) or inflammation of lungs and other organs (4%).

Keywords: Phoca vitulina, *Halichoerus grypus*, stranding, diseases, mortality, necropsy, pathology, North Holland and Texel.

Introduction

The health status of the free ranging seals is hard to obtain. Pathological investigation of stranded seals provides insight in the general health status and is a good opportunity to monitor diseases affecting the seal population.

In the Netherlands live two species of seals the *Phoca vitulina*, commonly known as the common seal, and *Halichoerus grypus*, also known as the grey seal**.**
In the Wadden sea there were 7821 common and 1445 grey seals in 2011, see Figure 1[1].
This represents a 13 percent growth of the common seal population compared to the previous year[2].
In that same year 2388 common seals were born in June and July and 322 gray seal pups were born between September and December[1].

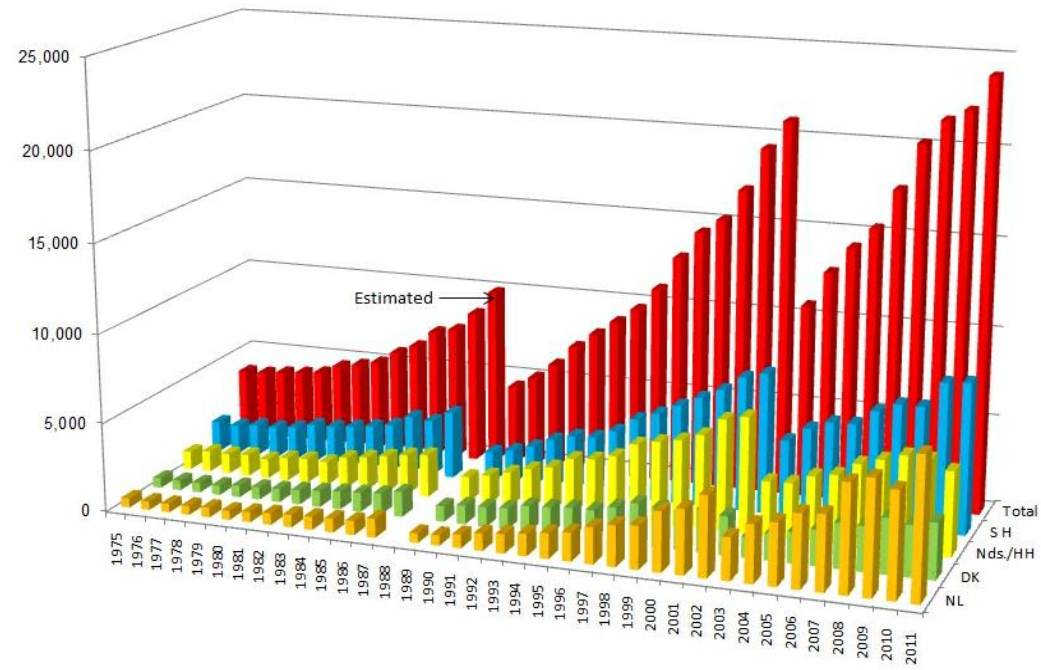

Figure 1: Number of counted common seals in the Wadden Sea per year since 1975 in the Netherlands (NL), Lower Saxony and Hamburg (Nds/HH) and Schleswig-Holstein (SH)[2]

The amount of seals can decrease because of migration, increased predation, interspecific competition, disturbance in the environment and diseases under the seals[3].

Migration

The common seal is not only found in the Dutch Wadden sea, this seal species can also be found in the Wadden sea of Germany and Denmark, and along the coast of England, Belgium and France[4]. There is little migration from seals from the Wadden sea to the south coast of the Netherlands and to the English east coast[5]. Because of the little migration a low estimated average of heterozygosity is found, particularly in the Wadden sea. Thus an increase in homozygosity and a loss of genetic variation is seen. This results in a significant decrease in fitness (inbreeding depression, such as a decreased in adaptive potential) and consequently to an elevated risk of extinction[6].

The grey seal commonly lives around the Scottish coast, along the east coast of England and in Cornwall. Since the nineties the grey seal is also seen in the Wadden sea, and its population grows every year. The biggest population of grey seals is seen in the west of the Dutch island Terschelling[4]. The grey seal shows a significantly higher genetic variation in the Wadden sea when compared with the common seal[7].

Predation

The only threats for the seals in the Dutch Wadden sea are humans. Since 1965 is it forbidden to hunt seals in the Netherlands. However, humans are still a threat for the seals. The seals can be injured or even killed by fishing nets, propellers of boats, etcetera[4].

Competition

Seals eat fish which are living at the bottom of the Wadden sea. They find them with their whiskers. The diet of seals usually consists of mackerel, cod, whiting and flatfish[4]. The daily food intake is between 3 and 6 percent of their bodyweight[5], which represents 6 kg of fish per day. Fishermen think that seals will eat all their earnings, but the average damage is between 1 and 4 percent of their total income[4].

Disturbance of the environment

A lot of waste products end up in the sea. These products can be harmful to the seal population. An example of a toxin is polychlorinated biphenyls (PCB's). This substance has a negative influence on the reproduction and immune system of the seals[5].
Another increasing threat for the seals is the increase in tourism. Seals are seasonal mono-oestrus breeders. After a gestation period of 9-11 month common seals deliver their pups in June and July. The grey seals deliver their pups between September and December after a gestation period of 11 months[8].The mother seals feed their pups on sandbanks for 4-6 weeks for common seals and 17-21 days for grey seals [8]. When mother seals are disturbed by humans, they will flee into the sea and the pups may not receive sufficient milk. The pups are left alone on the sandbanks, and can die of emaciation or hopefully end up in a seal rehabilitating center[4]
Phocid seals enter their estrus close to the end of lactation[8]. In the lactation and reproduction period females loss a lot of weight which leads to delayed implantation (diapauses). The females need to regain body mass for implantation[9]. The diapause lasts 1.5-3.5 months in common seals and lasts 3.5 months in grey seals[8].

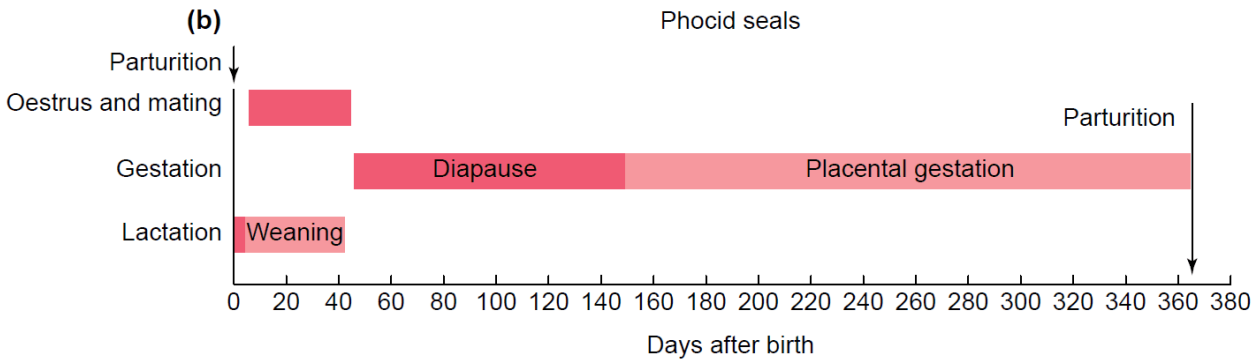

Figure 2: Reproductive event by the phocide seals[8].

Frequently occurring diseases

With this big population of seals, there is a need for a seal rehabilitation center, to take care of the individual stranded seals. In 2011 alone there were three to four hundred stranded seals rehabilitated in seal centers in the Netherlands[10]. In the past few years an increase in seal rehabilitation is seen.
In Denmark and Germany there is already a restriction of the amount of rehabilitating seals in seal centers[11]. In order to decrease the amount of rehabilitated seals in the Netherlands, the Dutch ministry of agriculture, nature management and fishery issued a guidance for rehabilitation of the common and grey seals in 2003. It states that while rehabilitating seals is not necessary for the seal population, due to public support it is allowed to rehabilitee helpless found seals[11].

Most of the rehabilitated common seals were diagnosed with lungworms what causes a bronchopneumonia[12].
There are two kinds of lungworms: *Parafilaroides gymnurus*, also known as the small lungworm, which resides in the lumen of bronchioles and in de pulmonary alveoli. The other most frequently seen lungworm is *Otostrongylus circumlitus*, also known as the big lungworm, which resides in the bronchi and bronchioles, but also can be found in the pulmonary artery and in the right ventricle of the hart[13].

An example of a big decrease of the seal population in the Wadden sea in the Netherlands was caused by a Phocine distemper epidemic in 1988. This morbilli virus infection killed 17000–20000 seals in northwestern Europe in 8 months[14]. In 2002 there was another outbreak, this virus was 97 percent homologous to that strain of 1988[15]. And killed again 30000 common and grey seals. The origin of this second outbreak remains unknown. Phocine distemper virus may have jumped into terrestrial carnivores, particularly mink, and re-infected seals, but this hypothesis remains unproven [14].

The Veterinary Pathology Diagnostic Centre of the Faculty of Veterinary Medicine at Utrecht University started an investigation on dead stranded seals and seals that died/euthanized in rehabilitation centre “Ecomare”. Those seals stranded between 2009 and the first quarter of 2012. The aim of this report is to investigate the pathological findings and the causes of death of those seals.

Material and methods

Collection of animals

From 2009 stranded seals in North Holland and Texel were collected by seal rehabilitating center Ecomare, Ruijslaan 92, De Koog on Texel. Dead animals were stored within 24 hours at minus 20 ^{o}C in a freezer at Ecomare or at the Institute for Marine Resources and Ecosystem Studies, Landsdiep 4, 't Horntje on Texel (Imares).
Stranded animals that were still alive were moved to the rehabilitation centre. Animals which were euthanized or died spontaneously at Ecomare were also frozen as described above and were included in this study. Data collection included stranding location, stranding date, species, age and gender of the seal. Medical records of rehabilitated seals (n=53) were available at Ecomare.
133 common and 17 grey seals were submitted for necropsy to Utrecht University, Faculty of Veterinary Medicine, Dept. Pathobiology in Utrecht, The Netherlands.

Necropsy and samples

Every carcass received 2 identification numbers: PV (for *Phoca vitulina*) or HG (for *Halichoerus grypus*) and an internal secretarial (so called "glims") number.
Carcasses were defrosted in a fridge at 3 to 4 ^{o}C. The required amount of time depended on the weight and length of the carcass. Small seals were defrosted in 2-3 days, big seals up to one week.

Seals were weighed with a mechanical scale, checked for microchips and photographs were taken of the seal, from the whole body (both sides), head (with snout and eyes), oral cavity (with teeth), urogenital region and tag number.
Four external sizes were measured:

- Total length (TL), this is the distance between snout and hind fin.
- Standard length (SL), this is the distance between the snout and the tail.
- Reduced length (RL), this is the distance between front side fin (axilla) and the tail.
- Axillary girth (AG), this is the length around the thorax.

Based on body length and gender animals were divided in three age categories: neonate, juvenile and adult. Common neonate seals with an age less than one year have a body length under the 103-107 cm. Common female adult seals with an age above 3.75 years have a body length above 129 cm. Male adult seals with an age above 4.7 years have a body length above 142 cm. Between neonate and adult is the age category juvenile[3, 5, 12].
For further size and age estimation see Table 1.

Gender	Sex	categories	Age (years)	Body length (cm)
Phoca vitulina	Male	Neonate	Age ≤ 1	Length ≤ 107
		Juvenile	1 < age ≤ 4.7	107 < length ≤142
		Adult	Age > 4,7	Length > 142
	female	Neonate	Age ≤ 1	Length ≤ 103
		Juvenile	1 < age ≤ 3.7	103 < length ≤ 129
		Adult	Age > 3.75	Length > 129
Halichoerus grypus	Male	Neonate	Age ≤ 1	Length ≤ 134
		Juvenile	1 < age ≤ 4.9	134 < length ≤ 174
		Adult	Age > 4.9	Length > 174
	Female	Neonate	Age ≤ 1	Length ≤ 126
		Juvenile	1 < age ≤ 4.0	126 < length ≤ 158
		Adult	Age > 4.0	Length > 158

Table 1: Used age categories of *Phoca vitulina* and *Halichoerus grypus* [12].

The blubber thickness was measured in the neck and breast.
A seal mean blubber thickness was interpreted as follow:

- Above a blubber thickness 15 mm, the seal is well fed
- A blubber thickness between 11 and 15 mm, means the seal is ill fed
- A blubber thickness under 11 mm, means that the seal is underfed (emaciation).

One has to keep in mind that the blubber thickness in seals varies so this classification is a rough estimation[16].

The nutritive condition code is a general impression of the nutritive state and can be divided in 6 stages (Table 2).

Nutritive condition code (NCC)	
NCC1	A very good nutritive condition, very well nourished, abundant blubber, significant other subcutaneous fat present in the dorsal neck and sometimes on the lateral thorax, longuisimus dorsi and neck are convex. The whole animal makes a "round, barrel-like" body shape.
NCC 2	A good nutritive condition, well nourished, abundant blubber, some subcutaneous fat, longuisimus dorsi and neck are straight or slightly convex.
NCC 3	A normal nutritive condition, the blubber thickness is normal, no subcutaneous fat present, neck and longuisimus dorsi are straight, on movement of the animal sometimes slightly convex.
NCC 4	A bad nutritive condition, the blubber thickness is on the thin side, skin thickness can be increased, neck and longuisimus dorsi are visibly concave.
NCC 5	A very bad nutritive condition, the blubber thickness is thin, skin thickness most often increased, longuisimus dorsi and neck are clearly concave.
NCC 6	An extremely bad nutritive condition, severely emaciated, the blubber thickness is very thin, neck and longuisimus dorsi are severely concave, the contour of the scapula (especially the spina scapulae) may be visible.

Table 2: Nutritive condition code explanation [17].

Depending on the state of the carcass, samples and histology were taken as described in the additional seal dissection protocol. The decomposition condition code is a general impression of the external and internal decomposition state of the carcass and can be divided in 5 stages. The higher the decomposition condition code score, the lesser amount of samples were taken and fewer evaluations could be performed (Table 3).

Decomposition condition code (DCC)	**State**	**Evaluations / Samples**
DCC1	Very fresh carcass, less than 24 hours.	Macroscopic evaluation, histological evaluation, bacteriology, virology, toxicology, ceacum contents, stomach contents and mandibula
DCC2	Fresh carcass, but first signs of decomposition are visible.	Macroscopic evaluation, histological evaluation, bacteriology, virology, toxicology,

		ceacum contents, stomach contents and mandibula
DCC3	Putrefies carcass, clear signs of decomposition (changes in color and consistency) of skin and organs.	Macroscopic evaluation, virology, ceacum contents, stomach contents and mandibula
DCC4	Very putrefied carcass	Macroscopic evaluation, ceacum contents, stomach contents and mandibula
DCC5	Remains of a carcass, this is completely useless for pathological examination	Macroscopic evaluation, ceacum contents, stomach contents and mandibula

Table 3: Decomposition condition code[17] and evaluations.

Macroscopic evaluations included: skin, blubber, muscle, urogenital tract, gonads, lymph nodes, urinary bladder, stomach, pancreas, spleen, liver, kidney, adrenals, lungs, heart, thymus (when present), thyroid, eyes, teeth, cerebellum, cerebrum and the intestines. The macroscopic evaluation was performed over time by the pathologists: Rebekha Fleis, Andrea Gröene, Jooske IJzer and Marja Kik. Macroscopic results were available from 150 seals, 133 common and 17 grey seals.
Histological samples were fixed in 10% neutral buffered formalin, routinely embedded in paraffin wax, sectioned (3 µm) and stained with haematoxylin and eosin (HE). When necessary additional staining were performed like a Ziehl-Neelsen (for finding acid-fast rods with Mycobacterium species) or Periodic acid Schiff (PAS, red coloration of carbohydrate, for parasites and fungi's) staining. The histology samples were evaluated by pathologists: Rebekha Fleis, Andrea Gröene and Jooske IJzer. Microscopic results were available from 55 seals, 50 common and 5 grey seals.
Bacteriology samples were taken in a sealed plastic bag, these were stored in a fridge (-20°C). For a simultaneous project faeces from the intestine (ceacum) was collected and brought for bacteriological culture to the Central Veterinary Institute (CVI) in Lelystad.
Samples for virology were taken from assigned organs and stored in plastic cups at minus 80 ^{o}C.
Blubber, muscle, liver and skin were packed in tinfoil and in little plastic seal bags, and sent to Imares for later **toxicology** investigation.

The mandible and the stomach content will be brought to research centre Imares. The age of the animal will be estimated by counting the cementum annuli[18]. At the moment of writing, these data are not available.
Stomach contents are used to investigate diet composition in fish species and fish length. This is based upon the evaluation of the remains the osseous part of the external acoustic meatus from different kind of fish. These data are beyond the scope of the presented project.

For future DNA research a little piece of the skin (epidermis) in the neck of the seals collected. The skin was stored in a plastic cup in 70% alcohol.

Parasitology

Macroscopically detected parasites (n= 60) on any location were preserved in a plastic container with alcohol 70% and glycerine (9:1).
Additionally, in 7 seals all intestinal parasites were collected from the contents of one meter jejunum on two third of the total intestinal length. The jejunum was cut open, the contents were rinsed out with water and collected in a plastic bucket. Contents and water were filtered with a 150µm sieve. Parasitologist Dr. Herman Cremers identified with a binocular the parasite species. Roundworms of the intestine were determined by using chlorine lactophenol.

Bacteriology

From selected cases a sample of the affected organ was taken and sent to the Veterinary Microbiologic Diagnostic Center (VMDC) of Utrecht University (n=19). The VMDC determined which bacterium causes the inflammation. VMDC sampled the organs on two blood agar plates (anaerobe and aerobe stored), one macconkey plate and the lungs and brains on a chocolate plate.
To determine the diagnose *Brucella* spp, samples of liver, lungs, lungworm and genital organs (n=3) were sent to central veterinary institute (CVI) in Lelystad. The CVI performed a serology Elisa test called SVANOVA[19] and a PCR test (based on the IS711 element).

Virology

To detect Morbilli virus (Phocine distemper) in the seals a Carre staining can be preformed (n=5). In this staining the viral antigen may be demonstrated by avidin- biotin Immunohistochemistry methode.
Tissue samples (n=18): lung, lymph nodes, spleen, liver and brain were sent to Erasmus University in Rotterdam. 15 common and 3 grey seals were tested on:

1. Phocine distemper, with a reverse transcriptase PCR that detect a phosphoprotein gene fragment of the morbilli virus.
2. Virus influenza, this antigen is diagnosed by Matrix Taqman RT-PCR, this test detect all Influenza A and B subtypes[20,21].
3. Phocid herpesvirus, with a PCR test.

Statistical analyses

For testing the stranding information in this research, the one sample Z-test (test 6) was used. For comparison of the causes of death betweens different studies a confidence interval was calculated[22].
The two formulas that were used, whereby p= sample proportion, n= number of individuals and π_1= estimated population proportion :

$$Test_6 = \frac{|p - \pi_1| - \frac{1}{2n}}{\sqrt{\frac{\pi_1(1-\pi_1)}{n}}}$$

$$p \pm 1.96\sqrt{p(1-p)/n}$$

All the macroscopic, microscopic, immunohistochemical, microbiological and parasitological information was stored.
The information that was used from the stranded seals for this research where:

- Stranding date and location of the seal in the province North Holland.
- Description of the seals: Species, age categories and gender.
- General impression of the seals: Nutrition condition and decomposition code.
- Clinical signs of the living seals
- Organs which were affected in the seals
- Evaluation in causes of death: trauma, nutritional status, etc.

The correlations will be investigate between these variables, and the consequences of these findings for the local wild seal population are discussed.

Results

Description of the stranded seals

Species

In total 133 common and 17 grey seals were included in this study.

Age classification

Table 4 shows how many dead (n=97) seals were stranded, how many seals stranded alive (n=53) and died or were euthanized in Ecomare. The head of one seal carcass was missing so the total body length was not determined. This seal cannot be categories in a age category, and can only by found in the total table row.

	Found dead			Found dead in rehabilitation center.			Euthanized in rehabilitation center			Total		
	Total	PV	HG	Total	PV	HG	Total	PV	HG	Total	PV	HG
Neonate	32	24	8	8	8	0	28	26	2	68	58	10
Juvenile	38	32	6	5	5	0	10	10	0	53	47	6
Adult	26	25	1	1	1	0	1	1	0	28	27	1
Total	97	82	15	14	14	0	39	37	2	150	133	17

Table 4: Total number of seals submitted for necropsy. The number of seals found dead on the beach, are euthanized or found dead in the rehabilitating center. PV = *Phoca vitulina*, HG = *Halichoerus grypus*

Totally there stranded 150 seals on the coast of the province North Holland in 2009 till the first quarter of 2012. 97 seals stranded dead, 14 seals where found dead in the rehabilitation center and 39 seals were euthanized. In total there were 68 neonate seals (45.6 % of all seals), 53 juvenile seals (35.6 %, with a confidence interval of 0.28 to 0.43) and 28 adult seals (18.8 %, with a confidence interval of 0.13 to 0.25). The most stranded seals were classified as neonate (chi-squared test (test 6): z= 3.10 ; P=0.002, with a confidence interval of 0.38 to 0.54).

Gender and age per species

Phoca vitulina

There were in total 71 common seal females (54%), 17 females were adults, 27 juveniles, 26 neonates and one unknown.
There were in total 60 common seal males (46%), 10 adults, 20 juveniles and 31 neonates.
More females stranded than males, this was not significant (chi-squared test (test 6): z= 0.83;P=0.41, with confidence interval 0.45 to 0.63).
Due to severe scavenging in 2 seals the gender remained unknown.
5 female seals were pregnant so there were 5 fetuses.

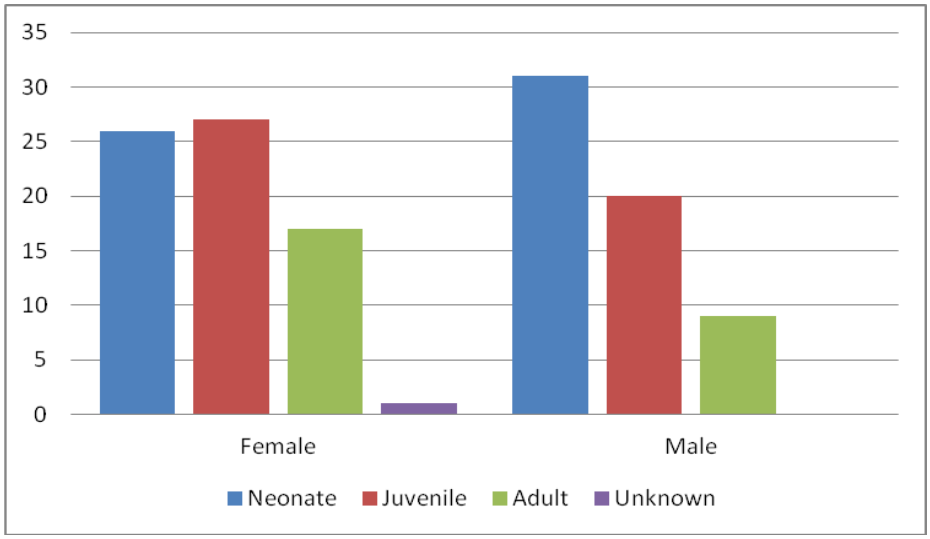

Figure 3: Total number of female and male common seals divided in age category.

Halichoerus grypus

There were in total 6 females (38%), 1 adult, 2 juveniles and 3 neonates.
There were in total 10 males (62%), 4 juveniles and 6 neonates.
One neonate seal had an unknown gender because of scavenging.
More males stranded than females, this was not significant (chi-squared test (test 6): z=0.75; P=0.45, with a confidence interval of 0.39 to 0.86)

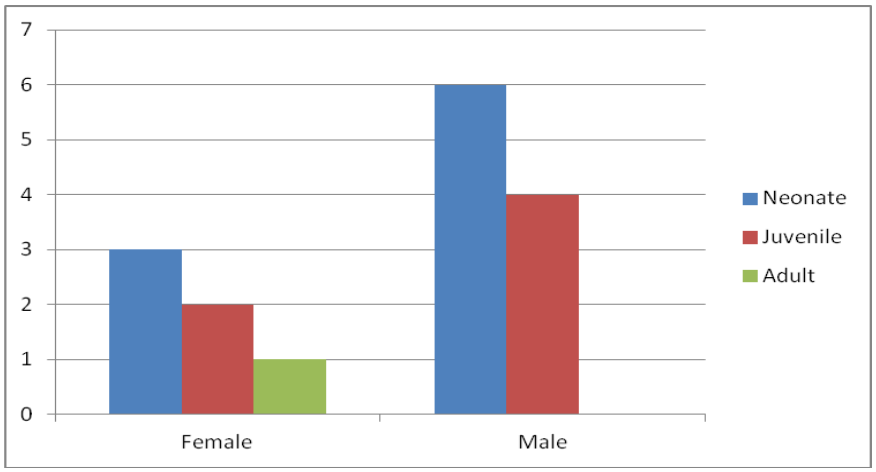

Figure 4: Total number of female and male grey seals divided in age categories.

Stranding dates - Phoca vitulina

Figure 5 and 6 shows in which year and month the 131 common seals stranded. The stranding dates of 2 seals were unknown.

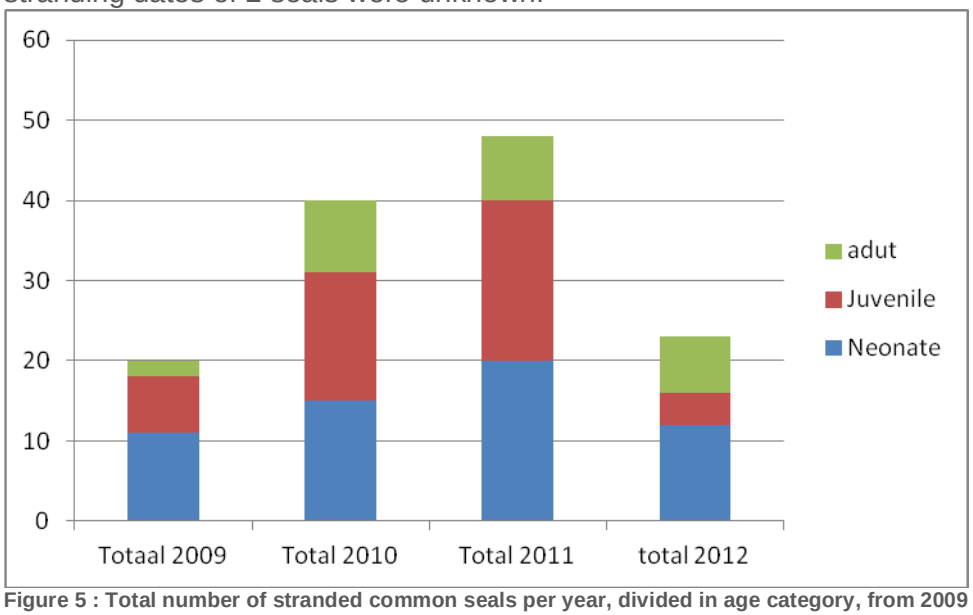

Figure 5 : Total number of stranded common seals per year, divided in age category, from 2009 till the first quarter of 2012 (n=131).

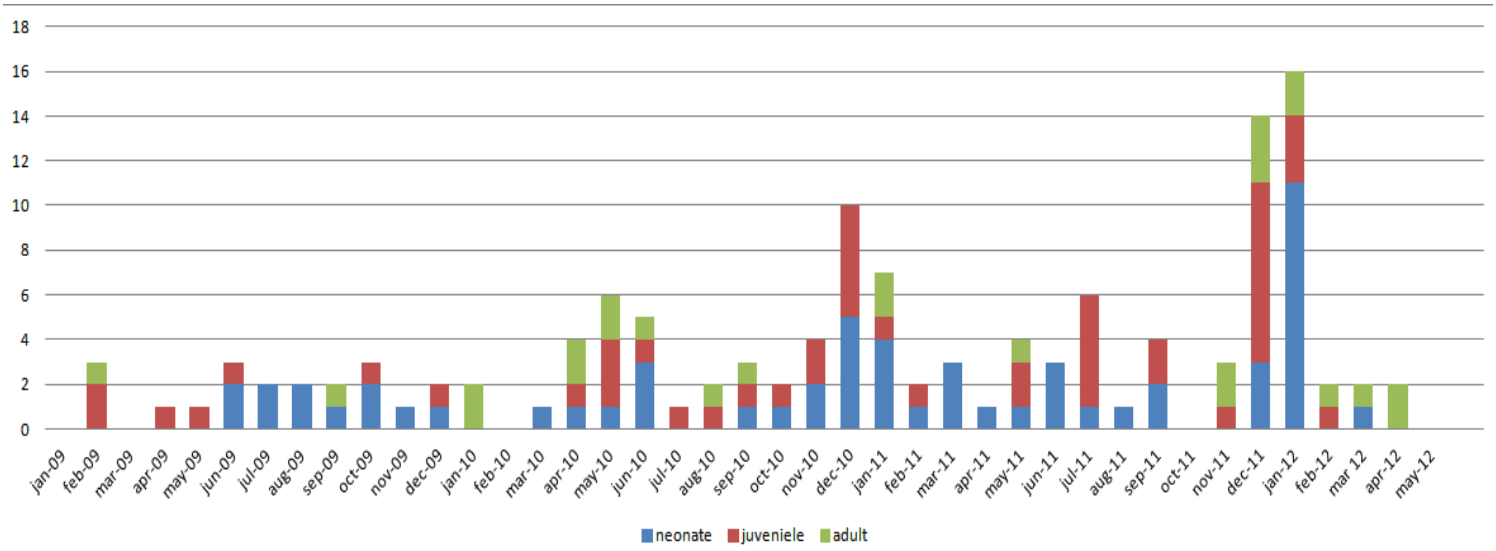

Figure 6: Total number of stranded common seals per month, divided in age category, from 2009 till the first quarter of 2012 (n=131).

In 2009 20 common seals were stranded (15.3%). Most seals stranded that year in the months February, June and October (n=3 ; 15%). 11 neonates (55%) stranded since June in that year.
In 2010 40 common seals stranded (30.5%). Most seals in December (n=10 ; 25%). 16 juveniles (40%) and 15 neonates (37.5%) stranded.
In 2011 49 common seals stranded (37.4%). Most seals in December (n=14 ; 28.6%). 20 neonates and 20 juveniles stranded (40.8%).
In the first quarter of 2012 21 common seals stranded (16.8%). Most seals in January (n=16 ; 76.2%).

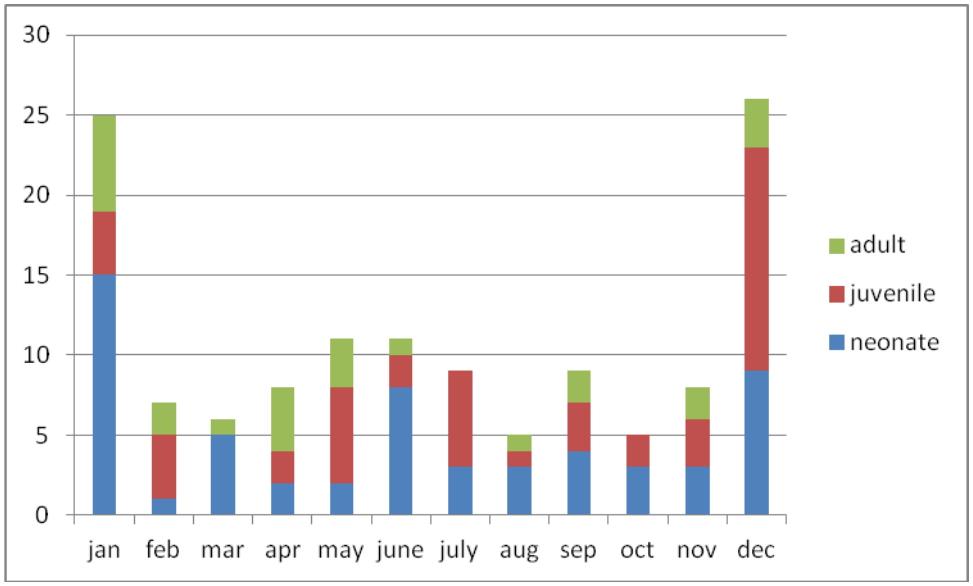

Figure 7: Total number of stranded common seals divided in age category and in months (n=131).

In total the most strandings took place in December (n=26 ; 19.8%) (chi-squared test (test 6): *z*= 4.59;P<0.05, with confidence interval 0.13 to 0.27), followed by January (n=25 ; 19.1%) (chi-squared test (test 6): *z*=4.30;P<0.05, with confidence interval 0.12 to 0.26).
The increase of strandings in December was mainly caused by the stranding of 16 juvenile seals (53.8%) (chi-squared test (test 6): *z*= 2.01;P=0.0444, with confidence interval 0.52 to 0.56).
The increase of strandings in January was mainly caused by the stranding of 15 neonate seals (60%) (chi-squared test (test 6): *z*= 2.62;P=0.0088, with confidence interval 0.41 to 0.79).
There was also an increase number of strandings of neonates in June (n=8;13.8%) (chi-squared test (test 6): *z*= 1.27;P= 0.2077, with confidence interval 0.05 to 0.23).

Stranding dates - Halichoerus Grypus

Figure 8 and 9 shows in which year and month the 16 grey seals stranded. The stranding date of one seal was unknown.

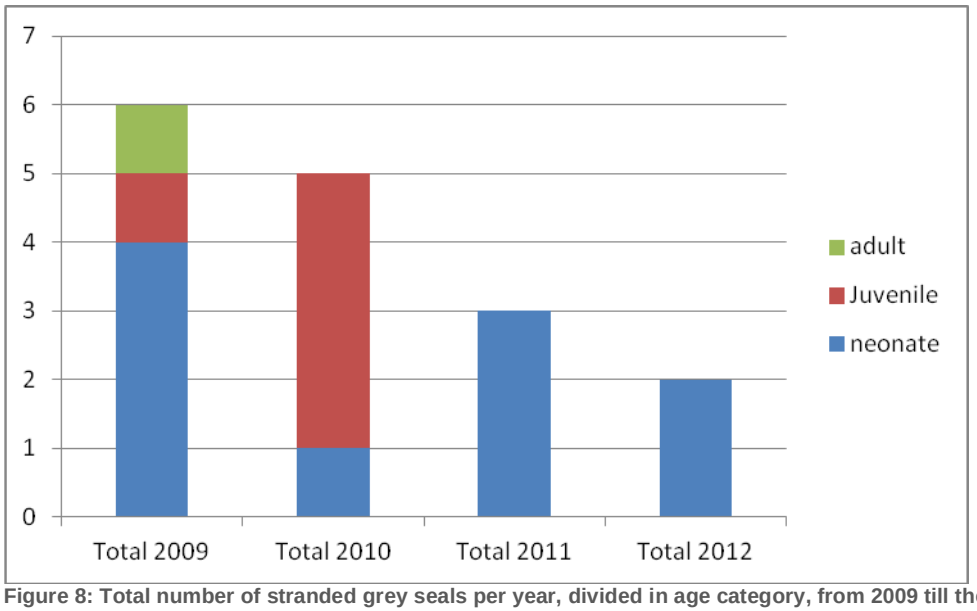

Figure 8: Total number of stranded grey seals per year, divided in age category, from 2009 till the first quarter of 2012(n=16).

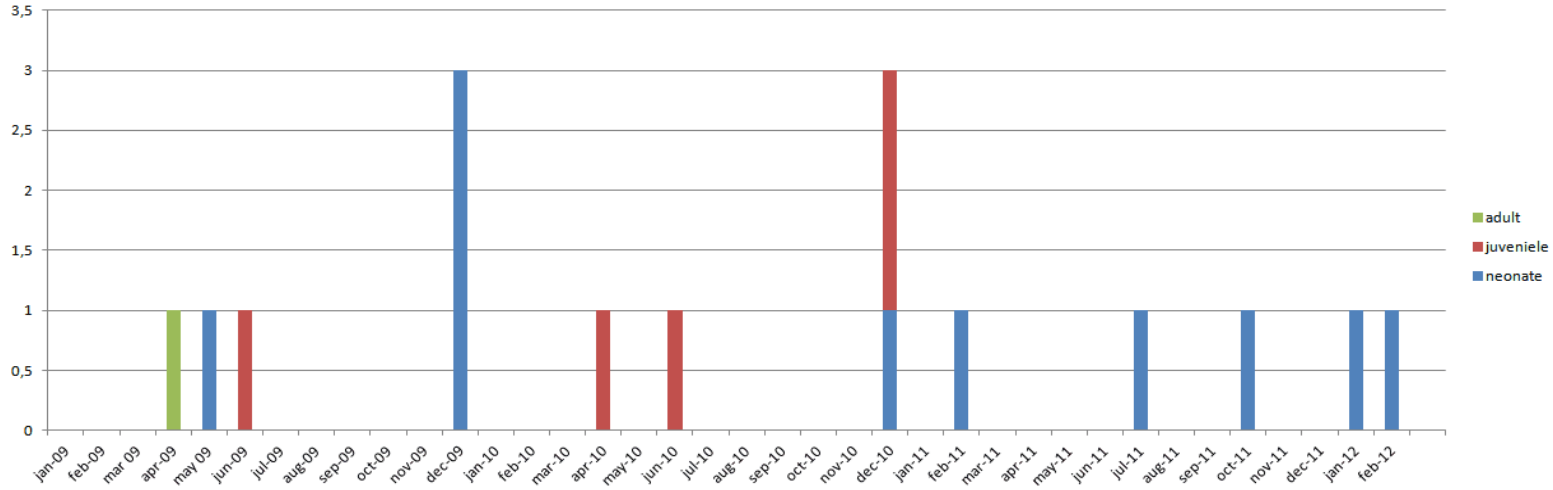

Figure 9: Total number of stranded grey seals per month, divided in age category, from 2009 till the first quarter of 2012 (n=16).

In 2009 6 grey seals were stranded (37.5%). 4 of them were neonates (66,7%). These neonates stranded mostly in December (n=3 ; 50%).
In 2010 5 grey seals were stranded (31.3%). Most of them were juveniles (n =4 ; 80%). 3 seals stranded that year in the month December (60%).
In 2011 3 grey neonate seals (18.7%) were stranded in the months February, July and October.
In 2012 2 grey neonate seals (12.5%) were stranded in January and February.

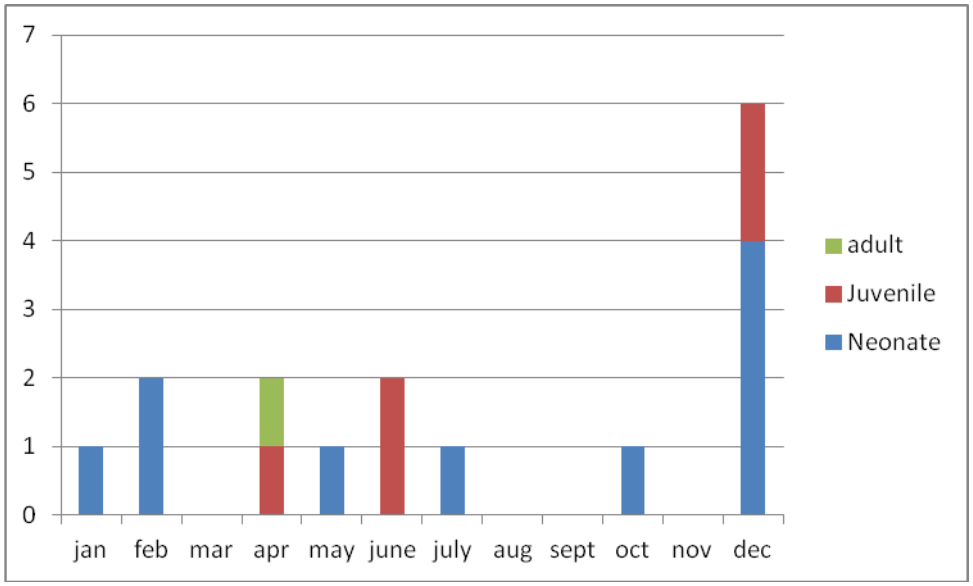

Figure 10: Total number of stranded *Halichoerus grypus* seals divided in age category and in months (n=16).

In total the most strandings took place in the month December (n=6 ; 37.5%)(chi-squared test (test 6): *z*= 3.77;P=0.00014, with confidence interval 0.14 to 0.61).

Stranding locations

Figure 11 shows the places where Imares and Ecomare found the stranded seals. The stranding locations of six seals were unknown.

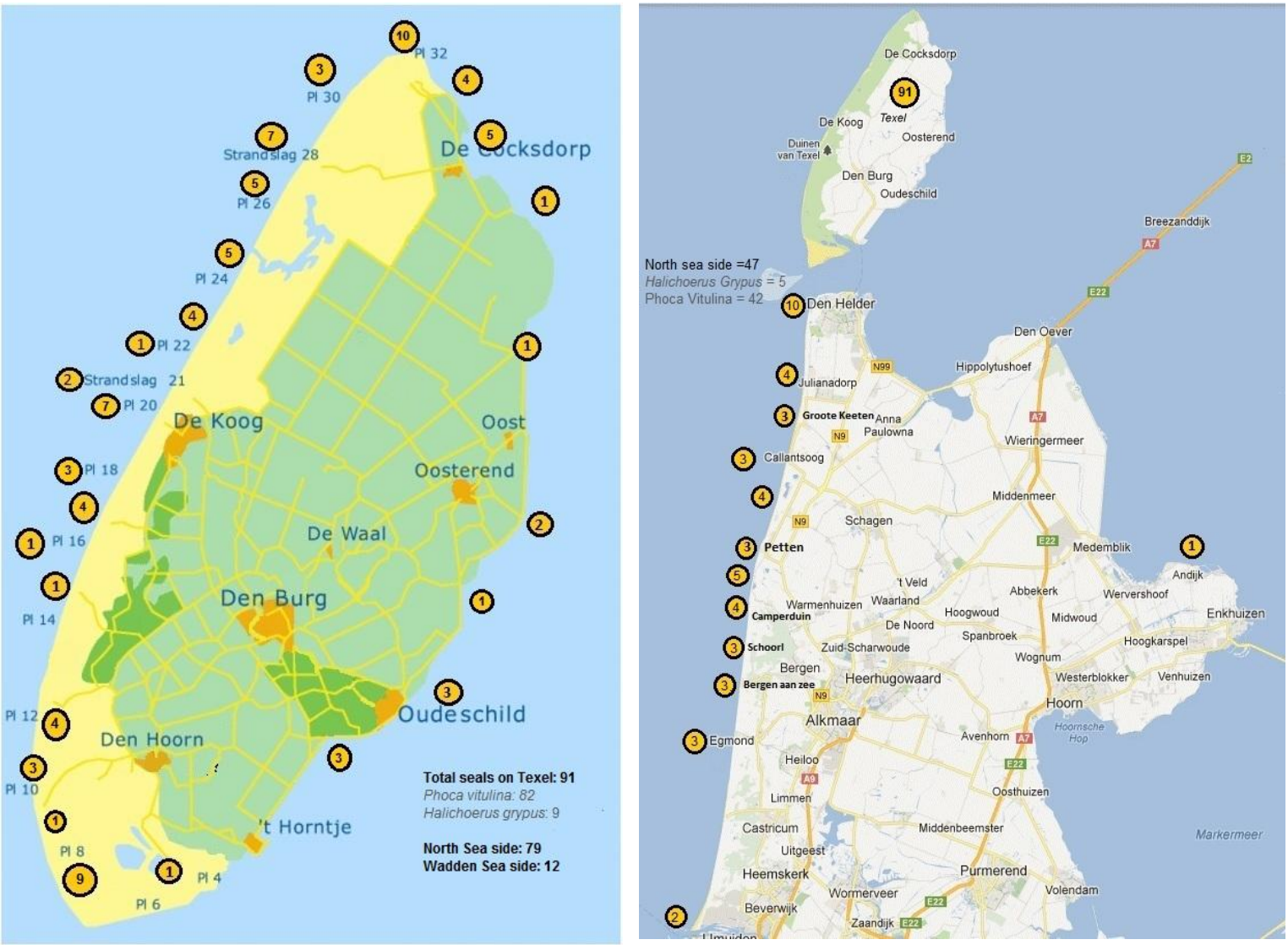

Figure 11: Geographical distribution of stranded common and grey seals in the province North Holland (including Texel) (n = 144)

Most of the strandings took place on Texel, namely 9 grey and 82 common seals. They were mostly found along the North Sea coast (n=79). The most common stranding locations on Texel were the north and east side of the island (north n=10 and east n=9).

47 seals stranded on the North Sea side of the North Holland, most of them in Den Helder (n=10).

Other locations of strandings of the common seals were Andijk (n=1), Dollard (n=1), Emmeloord (n=1) and Vliehors (n=1).Other places of grey seals were the Maasvlakte (n=1) and Togen (n=1). The stranding location of the remaining 6 seals was unknown.

General impression

Blubber thickness

Figure 12 shows the blubber thickness measurements (n=147). The blubber thickness of 3 seals was not determined and therefore unknown.

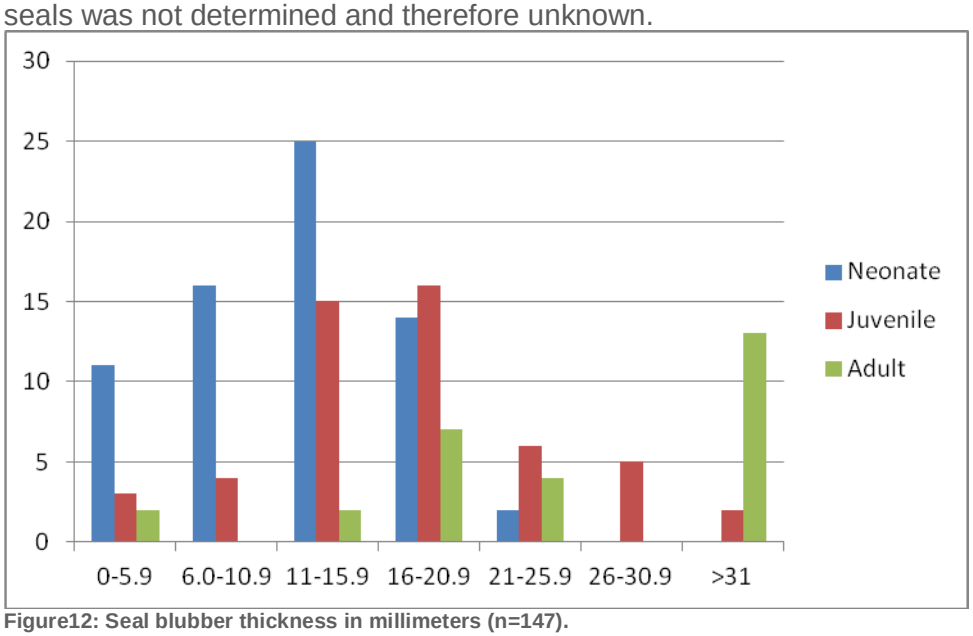

Figure12: Seal blubber thickness in millimeters (n=147).

The modal class of neonates of the blubber thickness was 11-15.9 mm (n=25 ; 36.8%). Neonates had a mean blubber thickness of 12.0 mm (common seals) and 11 mm (grey seals).
The modal class of juveniles of the blubber thickness was 16-20.9 mm (n= 16 ; 31.4%). Juveniles had a mean blubber thickness of 16.4 mm (common seals) and 24.8 mm (grey seals).
The modal class of adults of the blubber thickness was above 31 mm (n= 13 ; 48.1%). Adults had a mean blubber thickness of 27 mm (common seals).
The maximum blubber thickness was 44 mm in an adult seal, and the thinnest 0.3 mm in a neonate.

A seal blubber thickness of above 15 mm is well fed, a blubber thickness between 11-15 mm is ill fed, and a blubber thickness under 11 mm is underfed[16].
So of the 150 seals 36 seals were underfed: 27 neonates, 7 juveniles and 2 adults.
42 seals were ill fed: 25 neonates, 15 juveniles and 2 adults.
69 seals were well fed: 16 neonates, 29 juveniles and 24 adults.

Bodyweight and bodyweight / total length ratio

Figure 13 shows the total number of seals per body weight class and age category. The bodyweight of 3 seals was not measured, and therefore unknown.

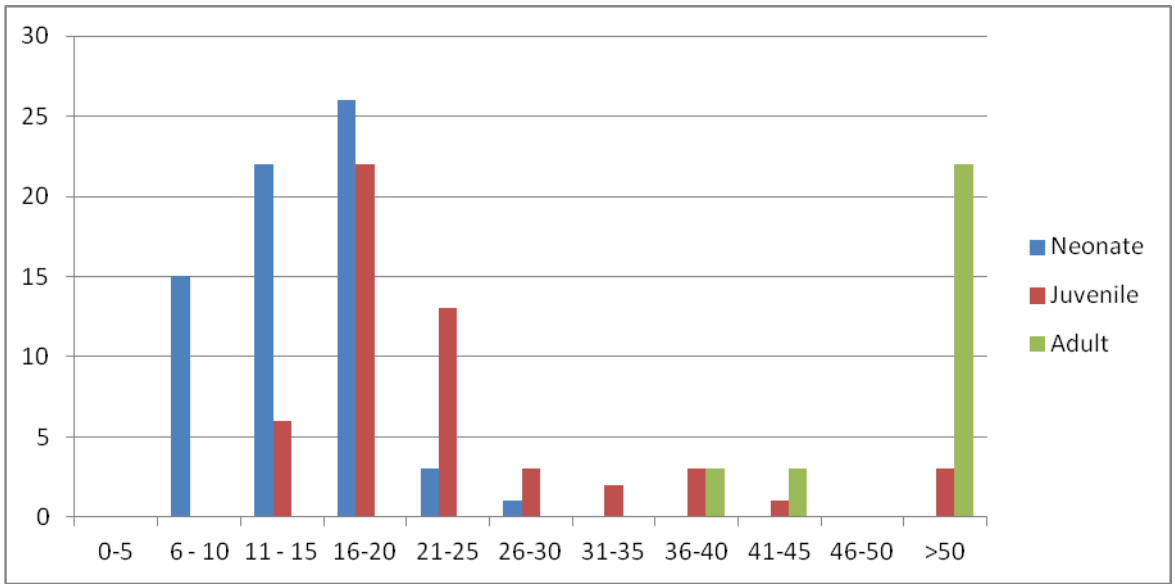

Figure 13: Body weight in kilogram of the stranded seals (n=147) per body weight class and age category.

The modal class of neonates and juveniles were both in 16-20 kilograms bodyweight. The mean bodyweight of neonate seals was 14.2 kg (common seals) and 17.3 kg (grey seals). With juveniles the mean body weight was 41.3 kg (common seals) and 47.9 kg (grey seals). The lightest neonate seal was 5.7 kg. The lightest juvenile seal was 13 kg. The modal class of adult was above 50 kilograms bodyweight. Adult mean body weight was 61.3 kg by common seals. The lightest adult weighted 37.4 kg.

The bodyweight in kg/total body length in cm ratio is calculated to estimate the degree of emaciation. Seal pups with a bodyweight/total body length ratio fewer than 0.075 for males and fewer than 0.073 for females were emaciated[23]. Figure 14 shows the total number of seals in the bodyweight / total length ratio classes. Bodyweight was in kilograms and total length in centimeters.

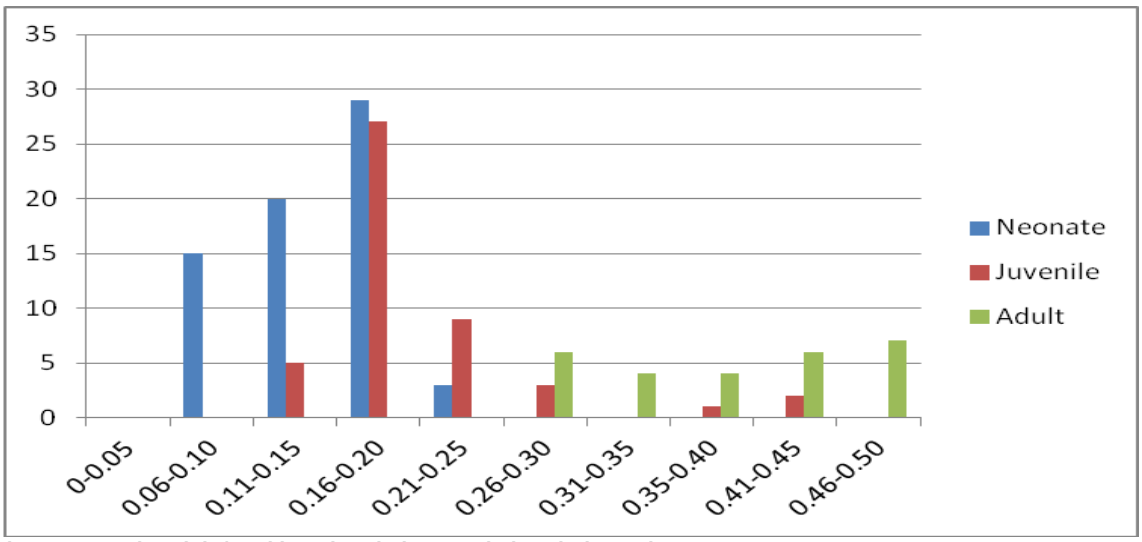

Figure 14: Bodyweight/total length ratio in stranded seals (n=141).

The bodyweight / total length ratio was as expected lowest in neonates, and highest by adult seals.
The mean bodyweight / total length ratio of common seal neonate was 0.146, by juvenile 0.189, and the adult 0.385. The lowest bodyweight / total length value was 0.0712 and the highest bodyweight / total length ratio was 0.50.
The mean bodyweight / total length ratio was higher in grey seals. In neonates was the ratio 0.154, juveniles 0.336 and adults 0.46.
The modal class of neonates and juvenile were both 0.16-0.20 (neonates n=29 ; 43.3% and juvenile n=27 ; 57.4%). The modal class of adults was 0.46-0.50 (n=7 ; 25.9%).
Only one seal had a bodyweight/total body length ratio lesser than 0.073 or 0.075, namely 0.071.

The nutritive condition code

The nutritive condition code (NCC) is a general impression of the nutritive state of the seals[17]. Figure 15 shows the distribution of the stranded seals over these NCC classes. The NCC of 5 seals was unknown.

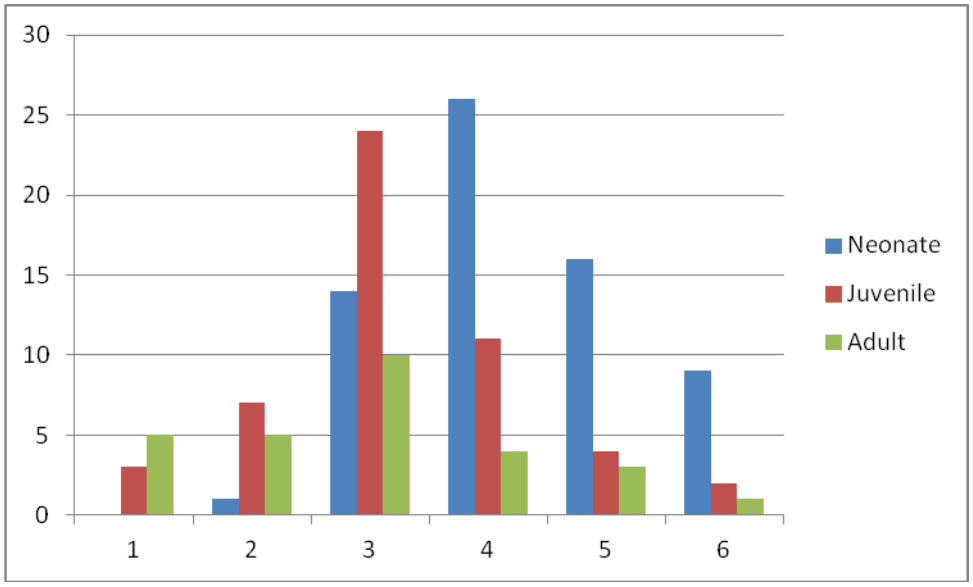

Figure 15: Nutritional condition code distribution of the stranded seals (n=145).

The modal class of neonates was NCC 4, this category means a bad nutritive condition. Juveniles and adults were in modal class of NCC 3, this category means a normal body condition. Emaciation (NCC 5 + 6) was present in 25 neonates, 6 juveniles and 4 adults.

The decomposition condition code

The decomposition condition code is a general impression of the external and internal decomposition state of the carcass[17]. Figure 16 shows the distribution of the stranded seals over these DCC classes.

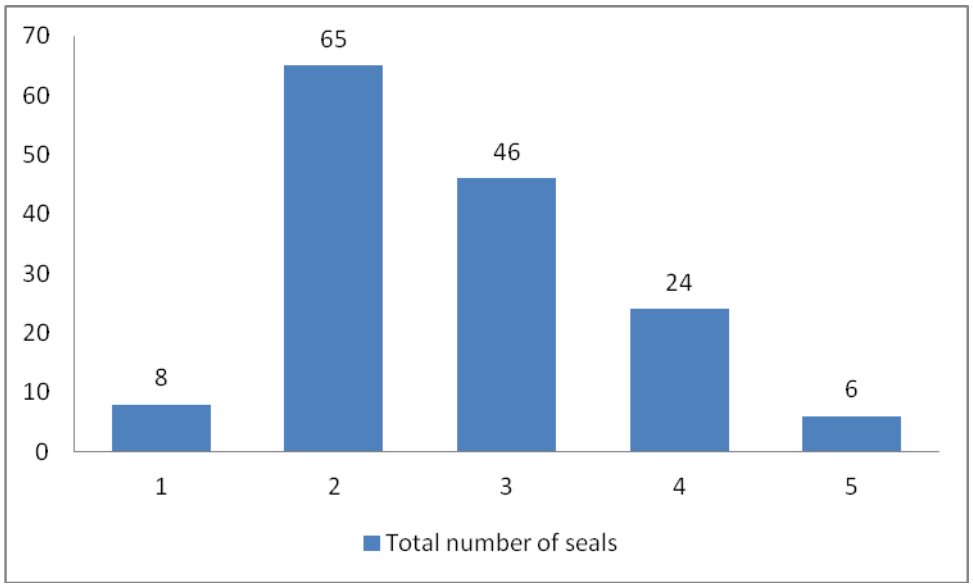

Figure 16: Decomposition code distribution of the stranded seals (n=149).

The modal class of the seals was DCC 2 (43,6%).

Clinical signs of the living seals

53 seals were alive when they stranded, but died or were euthanized later on in Ecomare. Figure 17 shows what kind of clinical sings these seals showed.

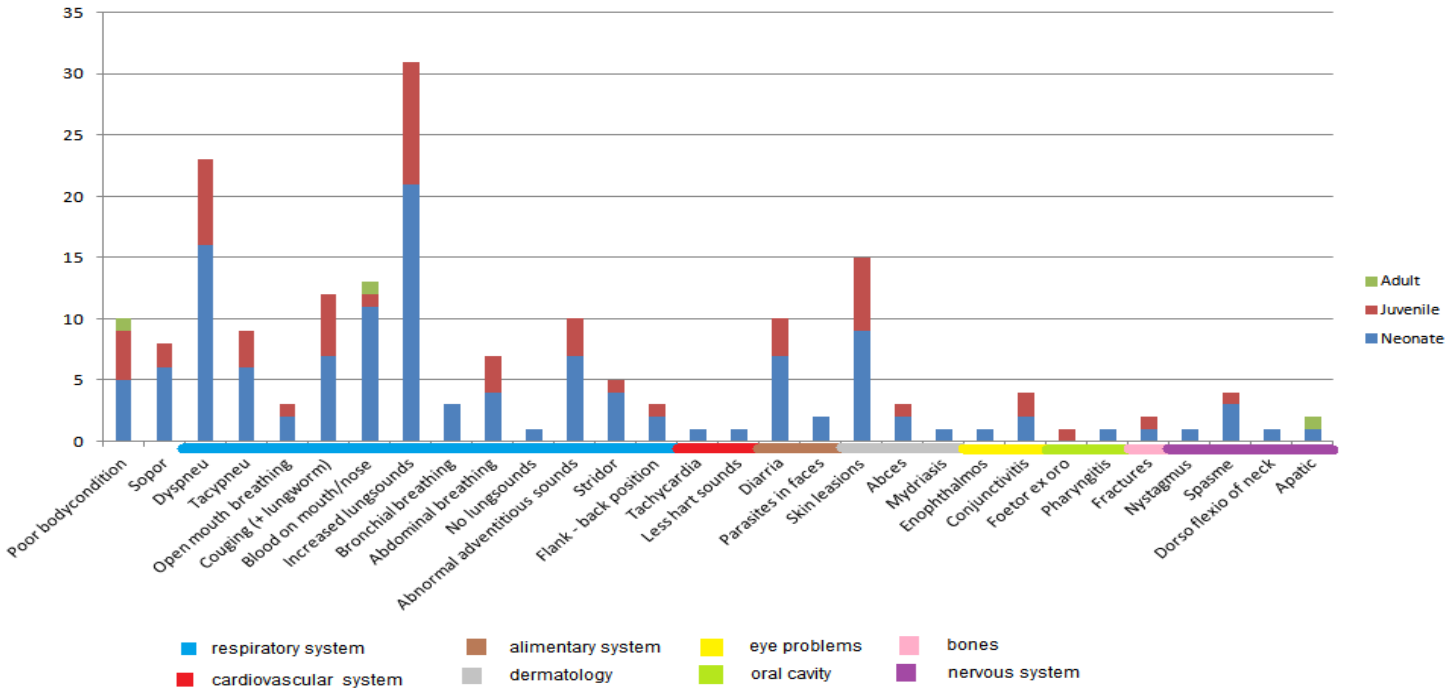

Figure 17: Clinical signs (n=50) of the living seals in the rehabilitating center Ecomare.

A lot of seals showed respiratory signs. The most common clinical sign was increased lung sounds (n=31) and dyspnea (n=23). Skin lesions was also seen on many seals (n=15).

Some seals died on the day of arrival, others were getting better, showing less clinical signs, but deteriorated after a few days. Figure 18 shows the time in days between arrival and death of those seals.

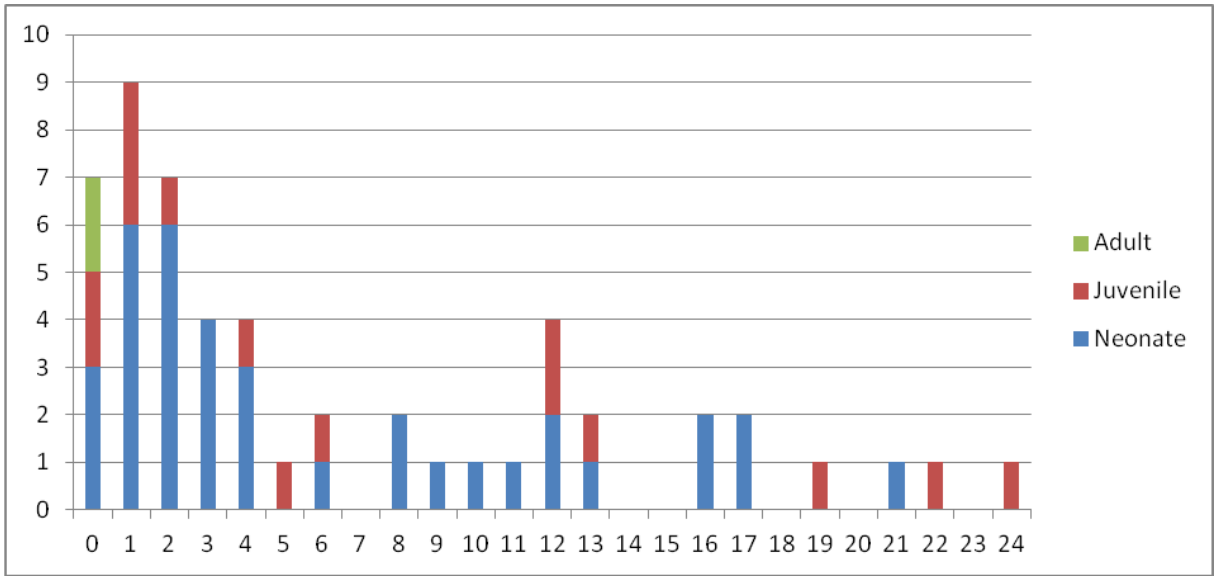

Figure 18: Time in days between arrival and death (n = 53)

64% of the seals died in the first 6 days (n=34). 4 seals died on 12 days after arrival.

Pathologal examination

Table 5 shows the pathological findings in 150 seals stranded between 2009-2012. Divided in species, age category and year of stranding.

		Total	PV	HG	neonate	juvenile	adult	2009	2010	2011	2012
Respiration system											
Pulmonary edema		65	55	10	28	25	12	13	17	19	15
Pulmonary congestion		3	2	1		1	2	2	1		
Pulmonary emphysema		24	21	3	10	9	5	7	8	6	2
Pulmonary heamorrhage		13	11	2	6	4	3	6	2	4	1
Pulmonary atelactase		18	17	1	7	10	1	2	5	4	7
Pulmonary hyperemia		23	20	3	11	8	4	9	5	5	4
Nematodiasis											
	mild	30	28	2	14	14	2	7	10	4	9
	moderate	19	18	1	9	10		3	6	6	4
	severe	21	20	1	15	6		5	8	3	5
Bronchopneumonia		37	34	3	17	16	4	8	11	7	11
Interstitial pneumonia		10	10		5	5		1	6	2	1
Bronchointerstitial pneumonia		7	7		2	4	1	3	2	2	
Pleuritis		1	1			1				1	
Abscess in lungs		1	1		1			1			
Rupture of the lungs		2	2		1	1			2		
Corpora Aliena		9	8	1	3	1	4	2	2	4	1
Foam in trachea		38	30	8	18	19	1	3	18	10	6
Fluid in trachea		14	13	1	3	7	4	6	4	2	2
Fluid in Bronchi/bronchioli		16	14	3	7	7	2	3	7	2	4
Liquothorax		7	6	1	1	5	1	2	3	2	
Pneumothorax		1	1		1				1		
Emphysema in mediastinum		9	9		4	3	2		4	5	
Diaphragmatic hernia		1	1		1				1		
Cardiovascular system											
Myocarditis		2	2			1	1	2			
Endocarditis		1	1		1				1		
Dilatated cardiomyopathy		1	1				1	1			
Persistant foramen ovale		1	1		1			1			
Nematodiasis in heart or A. Pulmonalis		18	17	1	10	8		5	5	7	1
Rupture of the hart		1	1		1				1		
Arteritis / vasculitis / periateritis											
Sepsis		6	5	1	2	1	3	2	1	1	2
Alimentairy system											
Enteritis		2	2				2	1	1		
Torsio intestine		1	1				1			1	
Hyperemic intestine		3	3		1		2			3	
Corpora Aliena gastrointestinal tract		6	6		3	2	1		3	2	1
Constipation		1	1		1				1		
Heamorrhagic contents		8	8		4	3	1	1	4	2	1
Gastritis		4	2	2	1	2	1	2	1	1	
Stomach ulceration		5	5		3	2		1	3		1
Reflux bile in stomach		2	2		1	1				1	1
Hepatomegaly		12	11	1	9	3		2	5	3	2
Hepatolipidosis		3	2	1		2	1		2	1	
Hepatitis		14	12	2	5	4	5	6	4	2	2
Liver necrosis		12	12		2	7	3	7	2	2	1
Liver fibrosis		2	1	1	1	1		2			
Liver rupture		2	2		1		1		2		

Liver congestion		4	4		3	1			2	2	
Fibrin on the liver surface		1	1			1					1
Cholestasis		1	1		1			1			
Pancreas fibrosis		1	1				1	1			
Parasites											
	Esophagus	20	15	5	13	4	3	4	5	8	2
	Stomach	64	56	8	25	28	11	14	23	17	9
	Interstitinal	39	36	3	21	13	5	4	17	12	5
	Liver	2	2				2	1	1		
Ulceration oral cavity		4	3	1	3	1		1	2		
Ulceration esophagus		1	1				1			1	
Inflammation around oesophagus/trachea		1	1			1					1
Fluid in abdomen		12	10	2	3	6	3	2	7	2	
Peritonitis		2	2			1	1	1		1	
Serosa fibrin		3	3		2	1				2	1
Infection navel		1	1			1				1	
Kidney and urinary system											
Nephritis		2	1	1		1	1	2			
Kidney abscess		1	1		1						1
Kidney neoplasia/infection		1	1				1				1
Urolythiasis		1		1		1					
Genital system											
Vaginitis		1	1		1				1		
Endometritis		2	2				2		2		
Fluid in uterus		2	2				2			2	
Pregnant		5	5				5		1	2	2
Uterus rupture		3	3				3			2	1
Skin and subcutis											
Hematoma		56	48	8	21	21	13	13	18	18	6
Trauma (blunt)											
	head	21	18	3	8	6	6	4	7	6	4
	neck	13	11	2	4	5	4	6	2	3	2
	chest	27	22	5	11	12	4	6	12	8	1
	shoulders	15	12	3	7	6	2	3	5	4	2
	flippers front	1	1				1		1		
	abdomen	3	3			2	1		2	1	
	flippers back	2	1	1	1	1			1		1
Trauma (sharp)											
	head										
	neck	2	2		1		1		1		1
	chest										
	shoulders										
	flipper front	4	4		1	3		1	1	1	1
	abdomen	2	2			1	1			1	1
	flipper back	2	2		1		1			1	1
Abscess		5	4	1	3	2		2	2	1	0
Skin parasites		4	4			2	2	2		1	1
Subcutaneous emphysema		6	6		1	4	1	1	4	1	
Dermatitis		9	9		4	4	1	5	3	1	
Alopecia		4	4		2	1	1		3	1	
Skin lesions		30	27	3	13	14	3	5	13	10	2
Scar		5	5		1	1	3	1	3	1	
Hyperkeratosis		2	2		1	1				2	
Pox lesions		5	5		1	1	3			3	2
Haemopoietic system											

Spleen megaly		17	17		7	9	1	3	4	5	5
Spleen hypoplasia		1	1				1			1	
Spleen congestion		4	4		2	2		1	2	1	
Spleen reactive		1	1		1				1		
Lymphadenomegaly		48	44	4	23	20	6	11	8	14	15
Lymphadenitis		1	1			1					1
Lymphoadenopathy		2	2		1	1				1	1
Fibrosarcoma		1	1			1					1
Extramedullary haemopoiesis		4	4			1	3		1	3	
Endocinology											
Thymus present		39	32	7	20	17	2	10	18	9	2
Adrenal hyperplasie		1	1				1				1
Adrenal necrosis		2	2			2		2			
Adrenal congestion		2	1	1		1	1	2			
Adrenal infection		1		1	1			1			
Thyroid necrose		1	1		1			1			
Central nervous system											
Encephalitis		1	1				1	1			
Meningitis		2	2		2			2			
Hyperemic meninges		6	5	1	2	3	1	2	2	2	
Hyperemic cerebrum/ cerebellum		1		1		1		1			
Neural necrosis		1	1		1			1			
Eyes		11	11		2	5	4	2	4	3	2
Hyphaema		5	5			2	3	1	2	2	
Conjunctivitis		4	4		2	2		1		1	2
Exophthalmos		2	2			1	1		2		
Musculoskeletal system											
Bone fracture		13	13		5	6	2	4	4	5	
	Skull	7	7		3	4		2	2	3	
	Vertebra	2	2		1		1		1	1	
	Humerus and ulna/radius	1	1		1				1		
	Metatarsal back	1	1			1		1			
	Metacarpal front	3	3		1	1	1	1	1	1	
Arthritis		4	4		2	2		2		2	
Myositis		1	1			1			1		
Osteomyelitis		1	1			1			1		

Table 5: Pathological findings in 150 seals stranded between 2009-2012. Divided in species, age category and year of stranding. PV = *Phoca vitulina*, HG = *Halichoerus grypus*

Respiration system.

Parasites in the lungs were found in 70 seals (46.6%). In 30 seals a mild infestation, in 19 seals a moderate infestation and in 21 seals a severe infestation. The parasitized animals were 38 neonates, 30 juveniles and 2 adults with a mild infection. 15 parasitized animals were stranded in 2009, 24 in 2010, 13 in 2011 and 18 in the first quarter of 2012.

Pneumonia was found in 54 seals (36%): 51 common and 3 grey seals . Divided in:

- 37 seals had a bronchopneumonia: 17 neonates, 16 juveniles and 4 adults.
- 10 seals had a interstitial pneumonia: 5 neonates and 5 juveniles.
- 7 seals had a bronchointerstitial pneumonia: 2 neonates, 4 juveniles and one adult.

Microscopically there were neutrophils (17), macrophages (10), eosinophils (9), plasma cells (6), lymphocytes (5) hystiocytes (2) and giant cells (1) seen. Also intra alveolar nematodes, fibrin exudation into bronchioles and alveolar spaces, focal necrosis or fibrosis, loss of architure, anisokaryose of bronchial epithelium, type 2 pneumocyte hyperplasia in the alveoli and an activation of BALT were microscopically seen. Bacteria that were frequently isolated out of the lungs were *Streptococcus* species like *Streptococcus equi equi* and *Streptococcus bovi*, *Escherichia coli*, *Clostridium*, *Gemella* species like *Gemella haemolysans* and mixed cultures.

Other abnormalities that have been found in the lungs were:

- Pulmonary edema in 65 seals (43.3%): 28 neonates, 25 juveniles and 12 adults.
- Pulmonary emphysema in 24 seals (16%): 10 neonates,9 juveniles and 5 adults.
- Pulmonary hyperemia in 23 seals (15.3%): 11 neonates,8 juveniles and 4 adults.
- Pulmonary atelectasis in 18 seals (12%): 7 neonates, 10 juveniles and 1adult.
- Pulmonary heamorrhage in 13 seals (8.6%): 6 neonates, 4 juveniles and 3 adults
- Pulmonary congestion in 3 seals (2%): 1 juvenile and 2 adults.

Foam in the trachea of the seals has been found in 38 seals: 18 neonates, 19 juveniles and 1 adult. This is probably due to pulmonary edema. 14 seals had fluid in their trachea and 16 seals had fluid in the bronchi or bronchioles. The presumably consistence of the fluid was mucus, purulent, hemorrhagic or a combination.

Foreign bodies in the lungs have been found in 9 seals: 3 neonates,1 juvenile, 4 adults and in one unknown age category. 2 adult seals and one unknown seal had ‘digested’ fish and fish bones in the trachea and bronchi. One adult had stomach contents in the trachea. Sand was found in the trachea of 2 neonates and one juvenile. One adult seal had shells in the bronchi. One seal died in the rehabilitation center half an hour after the seal was force feed with milk, in this seal milk was found in trachea and in the bronchi.

7 seals had a liquothorax. The color of the liquor was red. The consistence was fluid or viscous. One bacterial examination was done on the thorax fluid, it contained the facultatively anaerobic gram positive bacteria *Glamella* sp.
One seal had a pneumothorax , a rupture of the lungs and a herniation of the stomach trough the diaphragm because of trauma.
9 seals had emphysema in the thorax cavity mostly located in the mediastium.

Cardiovascular system

Nematodic infection of the heart was found in 18 seals: 10 neonates and 8 juveniles. 17 common seals were infected and one grey seal.

Pathological findings in the hearts other than nematodes were rare.
Infection of the heart was seen in 3 seals: one juvenile and adult had a myocarditis, one neonate seal had an endocarditis.

Microscopically in the myocarditis there were lymphocytes, plasma cells, eosinophils and neutrophils visible. In the endocarditis neutrophils and fibrin was visible on the endocardium.

One seal had a dilatated cardiomyopathy. This heart showed no apex and the right lumen side of the heart was dilated. No microscopic lesions were seen on the heart. The cause of death of this animal was an infection of the lungs and liver.
One seal had a congenital heart abnormality. This neonate seal had a persistent foramen ovale. This animal was a female neonate with a total length of 87 cm.
One seal had a rupture of the heart due to trauma.

6 seals had sepsis, this diagnose was made on the basis of the overmatch of infected organs. The organs that were exposed were mainly lungs and liver. Other organs were heart, kidneys, adrenals and uterus.

Alimentary system

Parasitic infection of the stomach was found 64 times (42.6%): 25 neonates, 28 juveniles and 11 adults. 14 parasitized seals were stranded in 2009, 23 in 2010, 17 in 2011 and 9 in the first quarter of 2012. The presence of this parasite was occasionally associated with hyperemic mucosa, ulceration or erosion of the stomach wall, thickened stomach wall and mucous, hemorrhagic or pica contents.
Intestinal parasites were found in 39 seals (26%): 21 neonates, 13 juveniles and 5 adults.

Ulceration of the oral cavity was found in 4 seals: 3 neonates and one juvenile.
Ulceration of the esophagus was found in one adult seal. Stomach ulceration was found in 5 seals: 3 neonates and 2 juveniles, associated with stomach parasites.
Gastritis was found in 4 seals: 1 neonate, 2 juvenile and 1 adult. Microscopically there were eosinophils, macrophages, neutrophils and multi nuclei giant cells seen. Also hyperemia and necrosis of the mucosa was visible.
Bile reflux in the stomach was found in one neonate and one juvenile.
An enteritis was found in 2 adult seals. Microscopically the mucosa had necrosis and numbers of lymphocytes, plasma cells and eosinophils were found.
A hyperemic intestine was found in 3 seals and hemorrhagic contents in 8 seals.
Copora aliena in the gastrointestinal tract was found in 6 seals: 3 neonates, 2 juveniles and one adult. Occasionally sand and shells were found in the intestine. Corpora aliena's were fishing lines, hard nail like material and small metal like material. One neonate seal had constipation in the intestines of hair and faeces.
One adult seal had an torsion of the jejunum through an opening in the mesentery (see figure 19 and 20). These changes were associated with red fluid in the abdomen. Microscopically no changes were seen, this was because of artifacts or autolysis.


Figure 19 and 20: Torsion of jejunum trough an opening in mesentery.

9 neonates and 3 juveniles had an enlargement of the liver.
14 seals (9.3%) had an hepatitis: 5 neonates, 4 juveniles and 5 adults. A macroscopically lesion that was frequently seen were small irregular white areas on the surface and parenchyma. Other lesions were a zonal pattern, enlargement and a pale color of the liver. Microscopically visible were hyperemia, focal necrosis, parasitic infestation, anisokarytose in the hepatocyts and inflammatory cells like neutrophils, eosinophils, macrophages, plasma cells, lymphocytes, giant cells and knupffer star cells.
Bacterial isolates from seals with liver abnormalities were *Streptococcus* species like *Streptococcen* group G Enrofloxacin resistance bacteria, ß-haemolytische *Streptococcen*, *Escherichia coli, Brucellosis* spp and mixed cultures.
Other liver changes that were seen:

- Liver necrosis in 12 seals (8%): 2 neonates, 7 juveniles and 2 adults
- Liver fibrosis in one neonate and one juvenile.
- Liver rupture in one neonate and one adult. The reason of the liver rupture was trauma in the neonate and was unknown in the pregnant adult seal.
- Congestion of the liver was seen in 4 seals: 3 neonates and 1 juvenile
- Hepatolipidosis was found in 3 seals: 2 juveniles and 1 adult. Macroscopically those liver were pale, had an orange color and had a friable consistence. When the liver contacted water grease circles were visible.
- Cholastasis was microscopically seen in one neonate.
- One juvenile seal had fibrin on the liver surface.
- Parasites in the liver were microscopically found in 2 adult seals (1,3%).

Fluid in the abdomen was found in 12 seals (8%): 3 neonates, 6 juveniles and 3 adults. Occasionally a liquothorax was thereby found. The fluid had a red coloration. The causes of the fluid in the abdomen were trauma, infection or unknown.
Peritonitis was found in 2 seals and fibrin on the serosa side was found in 3 seals.

Kidney and urinary system

Lesions of the kidney and urinary tract system were rare in seals.
In one juvenile and one adult a nephritis was found. The grey adult seal had a lymphoplasmacellular purulent nephritis. The nephritis in the juvenile seals showed microscopically a small focus of neutrophils, lymphocytes and plasma cells in the interstitium. In the tubulus and glomeruli clusters of bacteria were seen.
One neonate seal had on the right kidney an 2 by 3 cm abscess. This seal had also a purulent bronchopneumonia and a hepatitis. Bacteriological isolates from the abscess were *Klebsiella* species. This animal was euthanized by the rehabilitation center Ecomare.
One male adult seal had an enlargement of the kidney. The enlargement looked macroscopically on one side like a neoplasia and on the other side like an infection. The microscopic date is not available at the moment of writing. Presumably the enlargement oppressed other organs and the blood circulation (see figure 21 and 22).
One juvenile grey seal had small yellow crystal like material in the kidneys and yellowish crystal like material in the bladder. Also ulcerations were found in the oral cavity under the tongue.


Figure 21 and 22: Enlargment of the kidney. A neoplasia or infection?.

Genital system

5 common seals were pregnant. One was stranded in January, one in February, two in April and one found in May. One seal died of a liver rupture, no abnormalities were seen macroscopically or microscopically on the uterus. 2 seals had an uterus rupture. One seal had an uterus rupture of 7 cm long with a dislocation of the fetus in the abdomen, probably because of trauma. The other seal had an uterus rupture of 40 cm on the major curvature, with local chronic peritonitis. The fetus weighted 5 kg and was also dislocated in the abdomen. The fin was fractured in this adult animal, there was no other evidence that this seal died of trauma (see figure 23 and 24).

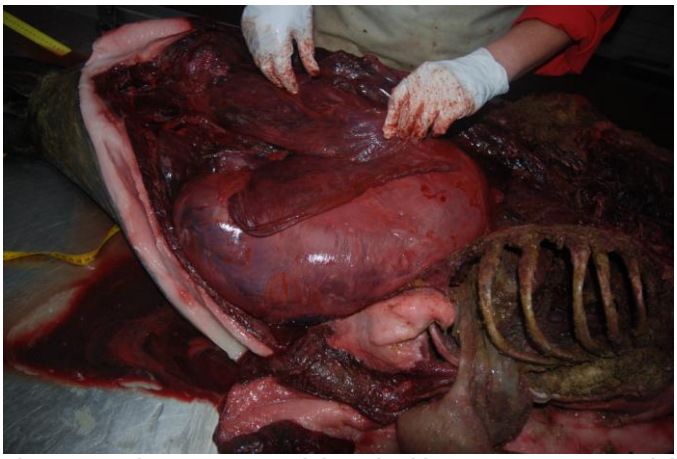

Figure 23 and 24: Pregnant adult seal, with a uterus rupture, and dislocated fetus.

The cause of death of the other 2 pregnant seals remains unknown. The total length of the fetus was in January stranded animal 40 cm. The fetuses that stranded in the April had a total length of 52 and 31 cm. The in May stranded fetus had a total length of 56 cm.
One other non pregnant seal had an uterus rupture. It was unknown if the rupture was ante or post mortem. This seal was bleeding out of the vulva and had an non-involuated uterus.
Two adult seals had an endometritis. Macroscopically the uterus contained a green white substance. Microscopically the endometrium had multifocal large pockets of degenerate neutrophils with necrosis and bacteria. The mucosa had moderate to severe numbers of lymphocytes, plasma cells, macrophages and neutrophils. Bacteriology on an uterus swab confirmed a mixed culture of 4 different gram negative bacteria.
2 seals had fluid in the uterus. The color of the fluid was green white till dark red.
One neonate seal had mild vaginitis, this animal died of emaciation.

Skin and subcutis

Blunt trauma like bruises were found on 56 seals (37.3%): 21 neonates, 21 juveniles and 13 adults. Most bruises were found on the chest (n=27), head (n=21), shoulders (n=15) and neck (n=13). These bruises contained hemorrhage and/or edema in the sub cutis, blubber or muscles. Other locations of blunt trauma were the flippers and abdomen.
Sharp trauma like cuts were seen at the flippers (front: 4, back:2), in the neck (2) and abdomen (2).

Skin lesions were seen on 30 seals (20%): 13 neonates, 14 juveniles and 3 adults. It was hard to differentiate between skin lesions ante mortem and post mortem because a lot of seals were scavenged.
Dermatitis was seen in 9 seals: 4 neonates, 4 juvenile and 1 adult. One dermatitis was found around a open fracture of the hind fin. Macroscopically abscesses, alopecia and ulcerations were seen. Microscopically ulceration, granulation tissue and inflammation cells like lymphocytes, plasma cells, meylenophages, neutrophils and macrophages were seen.

Skin abscesses were found on 3 neonates and 2 juvenile seals. Locations of the abscesses were on the right maxilla, ventral side abdomen, head, neck, thorax and front/back flippers. One neonate seal had several abscesses mainly on the ventral side of the abdomen but also head, neck and thorax. These abscesses contained purulent contents and were located in the subcutis and even in the muscles. Microscopically severe necrosis and inflammation in dermis and subcutis were seen. A swab was taken from the abscesses but no bacteria were found in this seal.
One abscess filled with purulent material was around a front fin bone fracture, one hemopurulent abscess was formed around a back fin polyarthritis and one abscess on the left front paw caused infection till the bone. In total 2 abscesses were sampled, no bacteria were found in the abscesses.

Pox lesions were found in 5 seals: 1 neonate, 1 juvenile and 3 adults. Mostly adults were infected. Macroscopically the lesions were occasionally found on the flippers. The lesions had a diameter of proximally 0,5 mm till 0,5 cm. No reaction was seen in the underlining tissue.

Hematopoietic

The spleen is relatively massive in deep-diving pinnipeds, because the spleen temporarily stores red blood cells. 17 seals (7 neonates, 9 juveniles and 1 adult) had an enlargement of the spleen. Other reactions of the spleen were hypoplasia, congestion and reactivity. Extramedullary heamatopoiesis was identified in one juvenile and 3 adult seals. Microscopically there were megakaryocytes visible.
Lymph node enlargement was found in 48 seals: 23 neonates, 20 juveniles and 6 adults. The lymph nodes that were enlarged were mainly pulmonary and mesenteric lymph nodes. Lymphadenitis was found in one juvenile seal and lymphadenopathy was found in one neonate and one juvenile.
One juvenile seal had lymphadenitis and lymphadenopathy of the pancreas and bronchial lymph nodes. Macroscopically the lymph nodes and spleen were enlarged. Microscopically the lymph nodes showed an active stadium, follicles with germinal centers and fibrin depositions with necrosis. A differential diagnose was tuberculosis, so a Ziehl-Neelsen staining was preformed and was negative. The final diagnose was a fibrosarcoma. The clinical signs of that seal in the rehabilitation center were dyspnea, increased lung sounds, coughing mucus, weight loss and diarrhea. This animal also had a mild parasitic infection of the lungs with a secondary bacterial *Clostridium Spp.* infection.

Endocrine

The thymus was present in 39 seals (26%): 20 neonates, 17 juveniles and even 2 adults. The adrenal gland of seals consist of a catecholamine-secreting medulla surrounded by a steroid-producing cortex[24]. Abnormalities that were seen on the adrenal of the seals were hyperplasia (n=1), necrosis (n=2), infection (n=1) and congestion (n=2).
The thyroid gland is the place of hormone synthesis and storage of both T_3 and T_4[24]. Thyroid necrosis was seen in one neonate seal.

Central nervous system

Encephalitis was found in one adult seal. Microscopically multifocal peri vascular aggregate of lymphocytes, plasma cells and neutrophils were seen. Also the skin, liver, lungs and myocardium were infiltrated by inflammation cells. The cause of death of this animal was infectious. The Carre staining that was performed on the brain was negative.

Two neonate seals had a meningitis.

1. Macroscopically meningual hyperemia was visible. Microscopically neural necrosis and eosiniphilic inclusion body's was seen. Clinical signs of this animal in the rehabilitation center were nystagmus to the right, spasm movements, balance disorder and dorsal flexi of the neck.
2. In the other case macroscopically abscesses on the body, skin lesions on the hind flippers and ulcerations in the oral mucosa were found. Microscopically neutrophills surrounding the vessels of meninges was seen. Beside this, mineralization of the bladder vessels was seen.

Eyes

Ocular lesions are very common in seals. In this research 11 eyes were affected.
Five seals were diagnosed with hyphaema mostly bilateral, four seals with conjunctivitis and two seals with an exopthalmus. A lot of animals had no eyes because of scavenging.

Musculoskeletal system

Bone fractures were found in 13 seals(8.7%): 5 neonates, 6 juveniles and 2 adults. Fractures of the skull were found in 7 seals (4.6%), of the front flipper 4 times (3 times metacarpal and once humerus), back flipper once and vertebra twice. Associated with the fractures there were edema and hemorrhages into the surrounding tissue. The cause of death of the animals with fractures were varied namely by catch, infectious cause, trauma and emaciation.
Arthritis was seen in 2 neonates and 2 juveniles. One juvenile seal had an open fracture of tarsus joint with edema in the surrounding tissues. Microscopically an arthritis and a dermatitis was found.
Also one neonate seal had an open fracture of a carpal bone. Microscopically neutrophils were visible in the joint. A swab for bacteriology was taken from the joint, and revealed mixed culture with *Streptococcen* spp, *Coryne* bacteria and gram negative rod shaped bacteria's.
One neonate seal had polyarthritis in both back flippers, an abscess was formed around the joints and the bones. Abscesses were huge and were formed from knee till nails. This seal also suffered from an hepatitis, two bacteria species were found on the liver (see figure 25).
One juvenile seal had an abscess with dermatitis, myositis and osteomyelitis on the left front fin and the other juvenile seal had swollen joints of a polyarthritis.

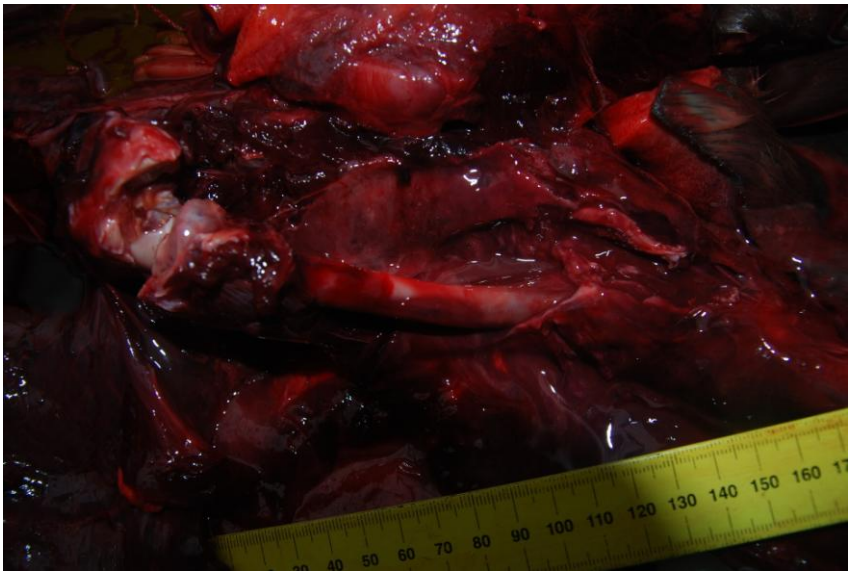

Figure 25: Huge abscess around the joints and bone of the back flippers.

Parasites

Parasites were determine of 60 seals by the parasitologist Dr. Herman Cremers. Figure 26 and Table 6 summarizes species determination.

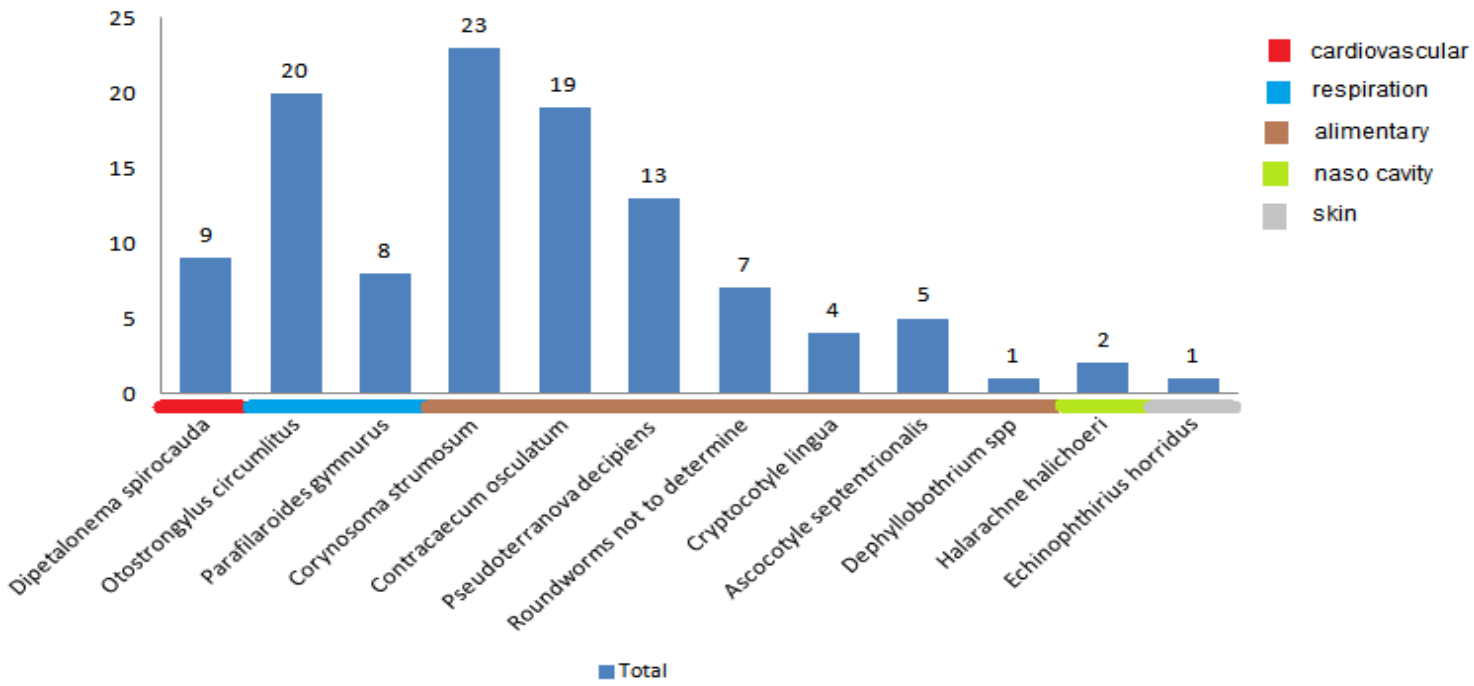

Figure 26 and Table 6: Determination of parasites by Dr. Herman Cremers per seal age class and year.

Parasite	Total	PV	HG	Neonate	Juvenile	Adult	2009	2010	2011	2012
Dipetalonema spirocauda	9	8	1	4	5		1	1	4	3
Otostrongylus circumlitus	20	18	2	9	11		8	4	4	4
Parafilaroides gymnurus	8	7	1	3	5		1	2	3	2
Corynosoma strumosum	23	22	1	15	6	2	2	9	8	4
Contracaecum osculatum	19	17	2	10	6	2	4	6	7	2
Pseudoterranova decipiens	13	9	4	4	4	5	5	3	3	2
Roundworms not to determine	7	7		2	5	0	3	1	1	2
Cryptocotyle lingua	4	4		1	3		1		2	1
Ascocotyle septentrionalis	5	5		1	3	1	1		2	2
Dephyllobothrium spp	1	1			1			1		
Halarachne halichoeri	2		2	2				1		1
Echinophthirius horridus	1	1			1				1	

Nematoda

Dipetalonema spirocauda can be found in the right heart chamber, the pulmonary arteries, and in the vena cava caudalis[25]. *Dipetalonema spirocauda* was determined in nine seals. One grey seal was infected. *Dipetalonema spirocauda* was found in 4 neonate and 5 juvenile seals (see figure 27).

The lungworm *Otostrongylus circumlitus* is macroscopically visible in the bronchi and bronchioles, but can also be found in the pulmonary artery and in the right ventricle of the hart[13]. *Otostrongylus circumlitus* was determined in 20 seals: 9 neonates and 11 juveniles. The lungworm *Parafilaroides gymnurus* is more difficult to find, this parasite lives in the lumen of bronchioles and in de pulmonary alveoli[13] and causes bronchiolitis and bronchopneumonia with pulmonary atelectase and emphsyma[26]. This parasite is found in 8 seals: 3 neonates and 5 juveniles.
A lot of seals were infected with lungworm, not all of the lungworms were determined by the parasitologist Dr. Herman Cremers.
In total 70 seals (46.7%) were infected with lungworm: 30 seals were mild infected, 19 seals moderate infected and 21 seals severe infected. 4 grey seals were infected. (See figure 28)

Pseudoterranova decipiens and *Contracaecum osculatum* can be found in the stomach of the seals[25]. *Pseudoterranova decipiens* infection was determined in 13 seals: 4 neonates, 4 juveniles and 5 adults. *Contracaecum osculatum* infection was determined in 19 seals: 10 neonates, 6 juveniles and 2 adults.
In total 64 seal stomachs contain parasites: 25 neonates, 28 juveniles and 11 adults.
Corynosoma strumosum can be found in the intestines. This parasite has a shape of a spoon. *Corynosoma strumosum* infection was determined in 23 seals: 15 neonates, 6 juveniles and 2 adults.

Trematoda

Ascocotyle septentrionalis can be found in the duodenum and in the proximal part of the ileum[27]. This parasite was determined 5 times: 1 neonate, 3 juveniles and 1 adult.
Cryptocotyle lingua can be found in the intestines and is usually not pathogenic. This parasite was determined 4 times: 1 neonate and 3 juveniles.

Cestoda

Dephyllobothrium spp. can be found in the intestines but is not pathogenic[28]. This parasite was determined one time in a juvenile.

Ectoparasites

Halarachne halichoeri is a mite that infects only *Halichoerus grypus* seals. Adult Halarachne have been frequently described in the nasopharyngeal and lung mucosa, while the larvae are found in the nasal passages called turbinates, they are feeding themselves with the mucosa. This parasite was found twice in the nose of *Halichoerus grypus* neonate seals.

Echinophthirius horridus is a louse that can be found on the skin of seals. *Echinophthirius horridus* was presumably found in 4 seals: 2 juveniles and 2 adults.
This parasite was once determined in a juvenile.

Bacteriology

Brucella Spp. was diagnosed twice, in one adult and one juvenile. Macroscopic lesions were an enlargement of lymph nodes, liver and spleen, irregular liver surface with multifocal white spots, hemorrhages in different organs like kidneys and lungs. Microscopically a hepatitis and pneumonia was visible.

Virology

No morbilli, influenza or herpes virus was detected by microscopically or PCR examination.

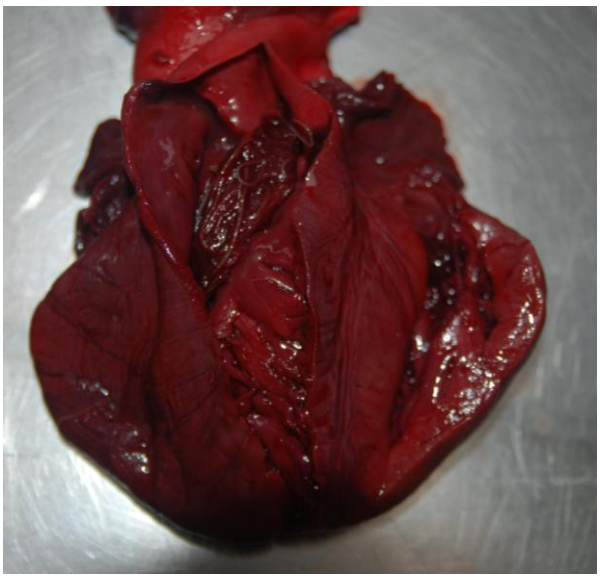

Figure 27 and 28: Dipetalonema spirocauda in the heart and Otostrongylus circumlitus in the lungs.

Causes of death

Figure 29 and table 7 show the possible causes of death of the 150 seals. Divided in species, age category and year of stranding.

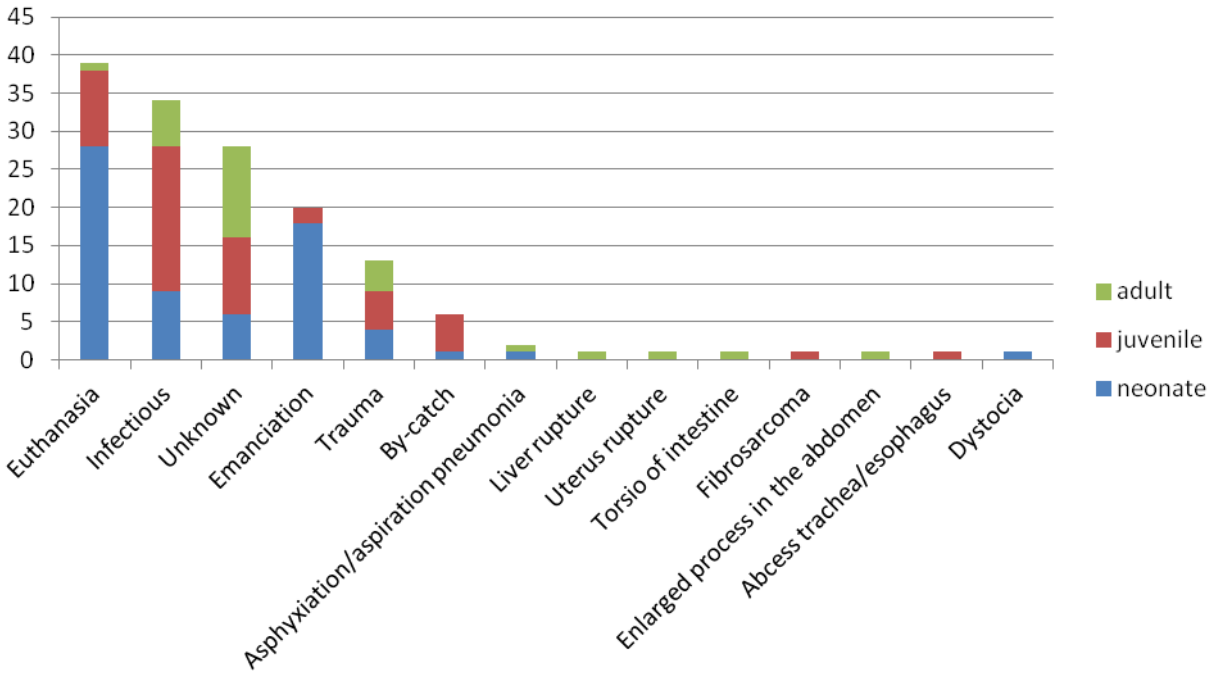

Figure 29 and Table 7: Possible causes of death of the seals (n=150).

	Total		PV	HG	neonate	juvenile	adult	2009	2010	2011	2012
Euthanasia	39	26%	37	2	28	10	1	3	12	11	13
Infectious	34	22.7%	32	2	9	19	6	10	10	10	4
Unknown	29	19.3 %	25	4	6	10	12	5	9	11	3
Emaciation	20	13.3%	15	5	18	2		3	5	9	3
Trauma	13	8.7%	11	2	4	5	4	4	5	2	2
Bycatch	6	4%	5	1	1	5		1	3	1	
Asphyxiation / Aspiration pneumonia	2	1.3%	1	1	1		1	1		1	
Liver rupture	1	0.7%	1				1		1		
Uterus rupture	1	0.7%	1				1			1	
Torsio of intestine	1	0.7%	1				1			1	
Fibrosarcoma	1	0.7%	1			1					1
Enlarged process in the abdomen	1	0.7%	1				1				1
Abscess trachea/esophagus	1	0.7%	1			1					1
Dystocia	1	0.7%	1		1					1	
Total	150	100.2%	133	17	68	53	28	27	45	48	28

Euthanasia

39 seals (26%) were euthanized in the rehabilitation center Ecomare: 28 neonates, 10 juveniles and 1 adult.
Reasons for euthanasia were:

- Respiration problems in 32 seals (21.3%): 23 neonates and 9 juveniles.
- Neurological problems in 2 seals
- An fracture in the front fin in 1 seals
- A bad condition 1 seal
- Unknown in 3 seals

Infectious disease

34 seals (22.7%) died of an infection.
These infection were found in:

- Lungs in 17 seals (11.3%).
- Mouth, this seal had ulcerations in the mouth.
- Skin, this seal had abscesses on the whole body.
- Liver in 1 seal.
- Heart, this seal had parasite infestation in the heart.
- Joints, 2 seals had a polyarthritis.
- More than one organ. In 10 seals (6.7%) the infection spread to more than one organ. The organ that were affected were mostly lungs (6) and the liver (7). Other affected organs were joints, skin, heart, intestines, brain, uterus, kidneys, adrenals and stomach.

Unknown

Of 29 seals (19.3%) the cause of death was unknown, this was due to an autolysis, scavenging or no pathological findings. Sometimes the cause of death was not sure, and was also put under the cause of death unknown.

Emaciation

Twenty seals (13.3%) were emaciated, this was visible on the carcass nutritional body condition or there was no evidence of recent feeding. This cause of death was mostly found in neonates (n =18).

Trauma

Trauma as a cause of death was found 13 times (8.7%). The trauma was mostly found on the head, neck and thorax. Pathological findings were hemorrhages on the body, fractures of bones and lung hyperemia and/or edema. Other findings were fluid in the thorax and abdomen and an uterus rupture.

Bycatch

Bycatch as cause of death was decided 6 times. Pathological findings were hemorrhage on the body, edema in the lungs, foam or fluid in the lungs, fractures of bones, rupture of the lungs and reddish meninges.

Asphyxiation / aspiration pneumonia

Two seals died of asphyxiation. In one seal the airway was blocked by fish and in the other seal by milk.

Other causes

One seal died of dystocia or stillbirth. This seal had an umbilical cord, subcutaneous hemorrhages in the neck, no teeth, atelectasis in the lungs and presumably meconium in the intestines. This seal weighted 7.5 kilograms and had a total length of 84 centimetres (see figure 30 and 31).
One seal died of a severe inflammation process around the trachea and esophagus. A necropurulent peritracheitis/ perioesophagitis process, pushed alongside the whole length of the trachea. The prescapular lymph nodes were enlarged. This animal was found dead in the rehabilitation center Ecomare.

Figure 30 and 31: Neonate seal that died of dystocia or stillbirth

Discussion

Stranding

In this study seal strandings of the common seal increased each year, in every age category. In 2011 49 seals stranded, a growth of 18 percent in comparison with previous years. In the first quarter of 2012 already 22 seals stranded.
An explanation for the growing numbers of strandings is that the population of seals is growing in the Wadden Sea and North Sea or that more seals are getting sick.
Not all seals that die at sea wash up on the coast and live strandings are two to three times more frequent than dead strandings[12].

In the Wadden sea were 7821 common and 1445 grey seals in 2011, see Figure 1[1]. This results in a population ratio of 1 grey seal against 5.4 common seals. Based on this ratio, a higher number of grey seal strandings (namely 24.5) would have been expected. An explanation for this outcome could be that grey seals do not live around the province North Holland, or that less animals died of for example an infection or trauma. With this low amount of grey seals it is more difficult to say something about the amount of strandings. The only thing that this research showed was that the last few years more neonate grey seals stranded.

In this research most common seals stranded in December and January. In this period the common seals have an average age of 6 months and are susceptible for lungworm. Seals can get infected after 3.5 months[13] but pulmonary diseases are reported in seals from 6 months and onward[12].
In study of N. Osinga most common seals stranded in June- July, with more than 120 seal strandings[12]. This can be explained because the common seals are born in June. In this research only 8 neonates (13.8 %) stranded in June.
Most grey seals stranded in December (n=6 ; 37.5%), mainly neonates (n=4), this is because grey seals are born in the winter. This outcome is in line with the study of N. Osinga, wereby most strandings of the grey seals were in January and December[12].

The most common stranding location in the province North-Holland was on the island Texel, mostly on the North Sea side.

General impression

The age of the seals was estimated on base of the total length of the seal[12]. It might be that some seals have growth retardation for example due to emaciation. These animals have been placed in the wrong age category. So it is possible that animals that were categorized as neonate were actually juveniles.

Emaciation is a common finding in neonatal and juvenile marine mammals, especially pinnipeds[24]. Emaciation of pups may be due to conditions affecting the mother seals, like failure or delay of the mother to return to the pup, or due to conditions affecting the pup himself, like dystocia, infection, hypothermia or trauma. Emaciation of young pinnipeds is usually due to an inability to find food[24].
Emaciated seals show no evidence of recent feeding and have lost adipose tissue and skeletal muscle. Lipid is lost from the blubber layer which results in a more fibrous appearance of the blubber[24]. Emaciated pups (under 6 months of age) have an abnormal body stature, they have a disproportionately large head[29], their neck and pelvis are visible, sometimes even their ribs are visible, they weigh less than normal pups (3-10 kilos lighter)[30] and the blubber layer thickness is less than 10 mm[12] (see Figure 32).



Figure 32: Above a normal pup (NCC 3) and bellow an emaciated pup (NCC1)[29]

Histological lesions on emaciated pups are cholestasis due to decreased excretion of bile, leading to bile stasis and bile pigment in the hepatocytes[23].
Atrophy from the hepatocytes can be seen, because hepatocytes react most markedly to lack of nutrients[23]. The thymus is atrophied[31] and there is a loss of zymogen granules in the pancreatic acini[24]. These histological lesions were rarely seen in this research a probable explanation is that these carcasses where frozen before necropsy. It is still difficult to diagnose emaciation as cause of death.
There are three methods to evaluate severe weight loss, render different outcomes in the present study:

1. Blubber thickness measuring[16]. The blubber thickness can be easily measured. A disadvantage is that there is a lot of variation in blubber thickness in animals. In a study with 556 common adult seals had a thicker blubber layer than young seals, also female adult seals have a thicker blubber layer than adult male seals. The blubber thickness also depends on the season, both sexes are thicker in the winter season than the reproductive and molt period[32]. In this present study adult seals had a thicker blubber layer than young animals. Another disadvantage of using this method is that the blubber thickness measuring is less reliable with an higher DCC.
   Using this method, 36 seals were emaciated. Also 42 seals were ill fed.
2. The bodyweight in kg/total body length in cm ratio. Seal pups with a bodyweight/total body length ratio fewer than 0,075 for males and fewer than 0,073 for females were emaciated[23]. This method can only used on pups and using this method only one neonate seal was emaciated. So this is not the best method, because there were more emaciated animals with the other more reliable methods.
3. The nutritional condition code (NCC) is a general impression of the nutritive state of the seals[17]. With this method 35 seals were emaciated. This is a good method, but different people interpreted this code different.

When comparing these methods, the blubber thickness method results and the nutritional body condition code results were almost the same and therefore, most useful. Less useful is the bodyweight/total body length ratio.

Most neonates had an overall blubber thickness between 11 and 15,9 mm. Thereby a mean nutritive condition code of 4 was found. This means that most neonates where ill fed and had a bad nutritive condition. A suboptimal body condition can lead to an impaired immune system, resulting in a higher susceptibility for infections. Juveniles had an overall blubber thickness between 16 and 20 mm. Adults had an overall above 31 mm. Both juveniles and adults had a mean nutritive condition code of 3. This means that most animals were well fed and had a normal nutritive condition.

Pathological examination

Most of the seals were frozen, leading to artifacts such as intracellular and extracellular ice crystals which disrupts cells and tissues.
Post mortem autolysis occurs because bacteria enter the tissues before or after death. This results in the production of color and texture changes, gas production and odors/putrefaction. A long death to fixation time interval can lead to problems in histopathological diagnosis of necrosis and other lesions. Scavenging also leads to problems in pathological diagnosis. Thus post mortem changes can interfere with accurate interpretation of both macroscopic and histological changes in the tissues[33, 34].

When a seal dies, it is preferable to submit the carcass immediately to the Department of Pathology of the Faculty of Veterinary Medicine for post mortem examination. The carcass should be cooled, not frozen, to limit post mortem autolysis. Less autolysis means a higher DCC category classification and thus more samples that can be taken and a more accurate interpretation of both macroscopic and histological changes.

In total there were 150 macroscopic evaluations and 55 histological evaluations. At the time of this writing, not all histological samples have been evaluated by the pathologist.
The post mortem examinations were performed by different pathologist with help from veterinarians, veterinarian students and coworkers. This may lead to different interpretations of the pathological findings. For the present study all post mortem examination reports were read by one veterinarian student to evaluate the reports to an uniform criteria.

Respiratory system

The respiratory system was the most pathological affected organ in seals in this research. At least 55 seals died from lung problems (36.6%). This was in agreement with other studies[15].
In 54 seals a pneumonia was found, these were caused by:

- Lungworm in 32 seals
- Bacteria's in 2 seals
- Bacteria and lungworms in 9 seals
- Unknown cause in 11 seals

In this research mostly parasites where the cause of pneumonias. A secondary bacterial infection could be found in the lungs. 29 seals had a parasitic infestation in the lungs but not a pneumonia.
Bacteria that were responsible for a pneumonia where: *Streptococcus* species like *Streptococcus equi equi* and *Streptococcus bovi*, *Escherichia coli*, *Clostridium*, *Gemella* species like *Gemella haemolysans* and mixed cultures. In other studies bacteria like *α/β Streptococci* and *Escherichia coli*, but also *Brucella maris*, *Coryenebacterium pseudotuberculosis*, *Erysipelothrix rhusiopathiae*, *Klebsiella pneumonia*, *Staphylococcus epidermidis* and *Vibria* spp, were found[15].

The organs in seals with a DCC of 3 or higher were autolytic and therefore no histological examination was performed. This means that it is likely some pneumonias were missed or not well differentiated. In addition, only one sample of one lung lobe was examined. This could also lead to false negative results, if this area of the lung was not affected by the inflammation. Therefore, in future research multiple lung samples should be taken and submitted for histological examination, even from the seals with a higher DCC category. Without the histology results it was sometimes difficult to detect a pneumonia and to differentiate the pneumonia.

The lungs can be discolored to various shades of red, indicating congestion, hyperemia and hemorrhage. It is difficult to differentiate between this possibilities on macroscopical examination of frozen carcasses[34].

Pathological	Description	Total	Causes
Bronchopneumonia	An inflammatory process that takes place in bronchial, bronchiolar and alveolar lumen. With this kind of inflammation exudates can be found in bronchial, bronchiolar and alveolar lumen.	37	• aerogene pathogens, bacteria, mycoplasma and viruses • hematogenous pathogens, viruses, bacteria and parasites • direct extensions
Interstitial pneumonia	The injury and inflammation take place in the layers of the alveolar walls and in the interstitial spaces. These lesions are more diffuse and involve all pulmonary lobes. The color is pale gray to mottled red and the lungs are heavier.	10	See above
Bronchointestinal pneumonia	Combination pneumonia.	7	See above
Edema	Develops when fluid from the pulmonary vessels enter the interstitium or alveoli	65	• Increased microvascular permeability by inflammatory or immunologic stimuli. • Increased intravascular hydrostatic pressure due to increased blood volume. • Decreased intravascular osmotic pressure. • Decreased lymphatic drainage.
Hyperemia	An active process that occurs in a acute inflammatory	23	
Congestion	A passive process resulting from decreased outflow of venous blood	3	
Heamorrhage		13	A result of trauma, coangulopathie, emboli, dic, vasculitis or sepsis.
Atelectasis	Incomplete distention of the alveoli	18	Acquired atelectasis can be caused by compressive atelectasis such as liquorthorax. Or obstructive atelectasis due to the reduction in diameter of the airways, because of mucosal edema, inflammation, or when the lumen of the airway is blocked by mucus, exudates, foreign bodies or lungworms
Emphysema	A pathological air entrapment in a tissue	24	
Pneumothorax	Presence of air in the thorax cavity, there should be a negative pressure to facilitate inspiration.	1	Most common cause is trauma when a penetrating wound is made in the thorax wall

Table 8: Description of pathological findings, with total affected animals and causes [34].

Foreign bodies in the lungs, like sand/shells and nourishment have been found in 9 seals. Corpora aliena in the lungs suggest an aspiration, but another cause aspiration of ingesta from the seal stomach into the lungs commonly takes place at death or can be displaced into these areas when the body is moved[34]. So a differentiation cannot be made.

Circulation system

Pathological finding in the cardiovascular system other than nematodiriasis were rarely found[15].
In this research only one neonate seal had a congenital defect. An atrium septum defect was found. This animal with a persistent foramen ovale was a female neonate with a total length of 87 cm. Based on the total length, this animal was just born, it could be that the foramen ovale still had to be closed. In a study with 20 neonate common seals, they found that the foramen ovale may be patent up to 7 weeks of age, and the ductus ateriosus may be patent up to 6 weeks of age without evidence of clinical consequence[35].

In this research one neonate seal had an endocarditis in that same animal also an pneumonia and an hepatitis was found. Endocarditis is rarely found in pinnepeds and is usually associated with other inflammatory lesions[24]. Also the myocarditis was associated with other inflammatory lesions.

Sepsis was found in six seals. Septicemia is characterized by the multiplication of micro organisms within the bloodstream and seeding into blood from fixed microcolonies present in one more tissues[34]. The tissues that were involved were commonly the lungs and liver.

Alimentary system

Ulcerations in the oral cavity was found in 4 seals: 3 neonates and 1 juvenile. Ulcerations of the oral mucosa are caused by infectious agents, chemical injuries, trauma (example foreign bodies), intoxicants, autoimmune or systemic diseases[34]. An infection example for oral ulcerations are herpes virus, parapox and calicivirus[31]. The calicivirus can be isolated from throat or rectal swabs or vesicle content[24]. This investigation was not preformed in this research.

An enteritis was found in only 2 adults. Microscopically the mucosa had necrosis and numbers of lymphocytes, plasma cells and eosinophils were found. In other studies an enteritis is found more frequently, mostly associated with parasites like hookworms[23]. Besides seals have frequently been diagnosed with bacterial gastroenteritis examples are *Salmonella enteriditis* and *Clostridial enterotoxemia*[24]. In our study the intestines were too autolytic and had freeze artifacts. Therefore it was not always possible to discover an enteritis.

One adult common seal had a torsion of the jejunum trough an opening in mesentery. Intestinal volvulus are more often diagnosed in common seals than in grey seals[12]. A macroscopical change was a red coloration of the intestines and red fluid in the abdomen. Microscopically no changes were seen this was because of artifacts or autolysis. Changes that can be found are catarrhal or hemorrhagic enteritis and hemorrhagic infarctions of the surrounding lymphnodes[36]. In other studies an intestinal volvulus was found, animals that were affected were mostly older than 18 months but there were also cases under the one year of age[12]. Predisposing factors are unclear, although more active behavior has been suggested as important factor[24].

Foreign bodies in the gastrointestinal tract were found in 6 seals. Occasionally sand and shells were found in the intestines.
Stone swallowing is a well recognized phenomenon in seals. Explanations for this habit are: to help with the digestion, to relieve the sensation of hunger or for destroying parasites and irritation on the mucosal wall. Sometimes stones, shells and sand are swallowed accidentally with a pray[31, 37]. In this study no stones were found in the stomachs. However, sand was a common finding in emaciated neonate seals. This could be to relieve the sensation of hunger.

Other foreign bodies that were found in this research were fishing lines, hard nail like material and small metal like material.

9 neonates and 3 juveniles had an enlargement of the liver. The causes of an enlarged liver are endocrine, infectious, neoplasia, congestion, toxins and hepatic accumulations like hepatic lipidosis, amyloidosis[34].
Autolysis of the liver occurs rapidly, because bacteria are released from the gastrointestinal tract into the portal circulation. It begins with pale areas on the capsular surface. The consistency of the liver becomes puttylike and emphysema may be visible[34].
Hepatitis should therefore be confirmed with microscopically evaluation or with bacteriology examination of the liver. This was not done on every liver, so it is possible that a diagnose of hepatitis was missed. Hepatitis was diagnosed in 14 seals. Bacterial isolates were *Streptococcus* species like *Streptococcen* group G Enrofloxacin resistance bacteria, *ß-haemolytische Streptococcen*, *Escherichia coli*, *Brucellosis* spp and mixed cultures. Another study reports the presence of bacteria like *α/β Streptococci* and *Escherichia coli*[15].

Kidney and urinary system

Pathological findings in the kidney and urinary tract system were rare[15].
A nephritis was found in 2 seals. A possible cause can be leptospirosis, this disease is most commonly seen in sea lions and northern fur seals. Pathological findings with this disease are kidneys that are markedly swollen and hard, with a loss of differentiation between the medullae and cortices, gallbladders containing thick black bile, thick pale yellow pericardial fluid and swollen, friable livers. Histopathological findings that can be found are diffuse interstitial nephritis and glomerulonephritis and spirochetes can be found in silver-stained kidney sections[24]. This last staining was not performed in our study.
In this research the 2 nephritis looked macroscopically different and microscopically bacteria clusters were found in the tubulus and glomeruli. This makes leptospirosis unlikely.

One neonate seal had on the right kidney a 2 by 3 cm abscess. This seal also had other inflammations in the lungs and liver. Bacteriological isolates from the abscess were *Klebsiella* species.
One male adult seal had an enlargement of the kidney. The enlargement looked macroscopically on one side like a neoplasia and on the other side like an infection. Neoplasms that have been found in the kidneys of pinnepeds are transitional cell carcinoma, nephroblastoma and fibrosarcoma[24]. The microscopic date is not yet available at the moment of writing.

One juvenile grey seal had small yellow crystal like material in the kidneys and in the bladder. Ulcerations were found in the oral cavity and red fluid was found in the abdomen. Uroliths are abnormal mineral salt concretions or stones found in the urinary tract and are rarely seen in marine mammals.
The uroliths that have been found in pinnepeds were composed of ammonium urate or/and uric acid. Three factors that contribute to the formation of these uroliths are acidic urine, hyperuricuria, and decreased urinary volume. In this present study no hydronephrosis and hydroureter were found, like in other studies[38]. The uroliths and the kidneys/bladder were not microscopically examined.

Genital system

5 common seals were pregnant. One was stranded in January, one in February, two in April and one found in May. The total length of the fetus was in January stranded animal 40 cm. The total length of the fetuses were in the April stranded animals 52 and 31 cm. The total length of the fetus was in May stranded animal 56 cm.

The fetus with a total length of 31 cm was very small. This can be caused by pathological abnormalities in the placenta or uterus, by infection or an unknown cause[34]. The fetus looked macroscopically unharmed.
Microscopically the umbilical cord had no hemorrhages. The placenta and the lungs of the fetus could not be microscopically examined because the carcass was to autolytic. The cause of death of the mother animal was unknown. So a cause of the grow retention is not known.

One neonate seal in this research died of stillbirth and/or dystocia. This seal had a total length of 84 centimeters and weighted 7,5 kilograms. Macroscopically this seal had an umbilical cord, subcutaneous hemorrhages in the neck, no teeth, atelectasis in the lungs and presumably meconium in the intestines.
There are four types of perinatal mortality: premature birth, stillbirth, neonatal mortality and congenital anolmalities[29].
A cause of stillbirth and neonatal mortality is dystocia, this is more common in females with large pups, with a weight of 1.0-1.5 above normal size (reaching up to 14 kg, normal weight is 7-10 kg[15]). Other causes of dystocia are abnormal fetal position and size and age of the females[29].
Seals that are categorized as stillborn have atelectatic lungs and meconium filled intestines[23].
Seals that died because of dystocia were characterized by edema of the head and neck, and frequently with bruising of the head, neck and chest wall and can have intra abdominal hemorrhage[31]. Thus this neonate animal died of stillbirth and probably dystocia.

Dermatology

Skin lesions were found in 30 seals, this is quite a lot. However skin lesions and scars were hard to diagnose, because most carcasses were scavenged. Therefore no differentiation could be made between ante or post mortem lesions of the skin.
Blunt trauma was found on 56 seals (37.3%): 21 neonates, 21 juveniles and 13 adults. Most bruises were found on the chest, head, shoulders and neck. Other locations of blunt trauma were the flippers and abdomen.
Sharp trauma like cuts were seen at the flippers (front: 4, back:2), in the neck (2) and abdomen (2) in all age categories.
Causes of trauma are difficult to diagnose. Possibilities of sharp and blunt trauma are animals dashing against objects like dikes with storms and high seas, injuries from other animals and trauma due to humans[12]. Intraspecific aggression may occur during territorial disputes and mating. Blunt traumatic lesions, characterized by bone fractures, hemorrhages, ruptured diaphragms, and hepatic fissures are frequently observed in neonates as a consequence of crushing by adults.
Bites causes puncture wounds associated with hemorrhage and are common in all age categories. These wounds may become infected, resulting in abscesses, fascitis, and rarely osteomyelitis, polyarthritis, and encephalitis[24].
According to a survey large skin lesions were a common finding in the 1970's . Now a day's skin wounds decreased[15]. This is in agreement with this study only a few sharp trauma was found.

5 seals had abscesses on their body: 3 neonates and 2 juveniles.
An abscess occurs when an inflammatory response fails to eliminate the stimulus, enzymes and inflammatory mediators. Abscesses can have a sterile or non sterile origin.
Septic abscesses are formed because of a bacterial infection like *Staphylococcus* or *Streptococcus*, whereas sterile abscesses arise from a incomplete degraded foreign bodies[34]. In this research 2 abscesses were bacteriological cultured, and no bacteria has been found.

Pox lesions are mostly found in neonates[39], contrary to this research were pox lesions were mostly found in adults. In total 5 seals had pox lesions. Common and grey seals are both susceptible. The incubation period can be long (over 4 weeks).
Light gray lesions with a dark gray border develop (0.5 - 1.0cm in diameter) and increase in size is seen the following 7 – 10 days, these may ulcerate and suppurate. The lesions can be found on the head, neck and flippers. A secondary bacterial infections is possible. Macroscopically hyperkeratosis and parakeratosis can be found in the stratum corneum. Electron microscopy can identify eosionphilic intracytoplasmic inclusion bodies in the stratum intermedium, this is not preformed in this research. The parapox viruses of pinnipeds are zoonotic[24,39].

Haematopoetic

The spleen is relatively massive in deep-diving pinnipeds, because the spleen temporarily store red blood cells. The spleen exist of red pulp, this is for removal of foreign material, storage of mature erythrocytes and for hematopoiesis. Another part of the spleen is white pulp this is for an immunological response with the production of b lymphocytes and plasmacells[34].
An enlarged of the spleen was found in 17 seals: 7 neonates, 9 juveniles and 1 adult. Causes of splenomegaly are storage of blood, increase in cells of monocyte-macrofage system, lymphoid hyperplasia, inflammation or neoplasia.
Severe malnutrition can lead to anemia, due to deficiencies of molecular building blocks, energy and essential co factors. With an anemia, chronic respiration disease and cardiovascular disease extramedullary hematopoiesis can occur[34]. Extramedullary hematopoiesis was found microscopically in 3 seals.
Splenomegaly can also occur in animals that have been euthanized with an intravenous injection of barbiturate[34]. In the early days, the rehabilitation center euthanized seals with T61. Now a days the seals were euthanized with euthasol 40%. Euthasol has as active ingredient barbiturate pentobarbital sodium which works on the medullary respiratory and vasomotor centers and can cause splenomegaly.

Lymphadenomegaly can be a consequence of inflammatory and non inflammatory processes[34]. Lymphadenomegaly was found in 48 seals: 23 neonates, 20 juveniles and 6 adults. A cause of all lymph nodes enlargement are systemic infection, inflammation or neoplastic processes. The most effected lymph nodes were bronchial and mesenteric lymph nodes. The mesenteric lymph nodes are normally larger than other lymph nodes because of a continuously receiving antigens and bacteria via afferent lymphatic drainage of the gastrointestinal tract[34]. A pneumonia was found in 54 seals. With a pneumonia it is normal to find enlarged bronchial lymph nodes.

The amount of reports of neoplasia in marine mammals has increased noticeably over the last 20 years[24]. In this study only 2 neoplasia cases were found. Causes of neoplasm are physical, chemical and infectious agents.
Fibrosarcomas have been found in mammary glands and kidneys in marine mammals[24]. The seal with the kidney fibrosarcoma was a 2 weeks old female northern fur seal and was found dead on the Pribilof Islands in the summer of 1973[40]. Also in this present research a firbosarcoma was found in the lymph nodes of a juvenile common male seal. Macroscopically this animal had enlarged lymph nodes and spleen. Microscopically these lymph nodes showed active stadium, follicles with germinal centers and fibrin depositions with necrosis. A neoplama that has been found more in common seal lymph nodes is a lymphosarcoma. Macroscopic lesions on those young animals included hepatomegaly, splenomegaly and lymphadenopathy. Microscopically on the lymph node solid sheets of neoplastic lymphoid cells infiltrated the sub capsular sinus and extended into the cortex along the internodular trabeculae. The germinal centers were reactive and contained

infiltrating islands and cords of neoplastic cells. Also mitotic figures were seen[41]. Lymphosarcoma in this species is spread by horizontal transmission[28] and probably caused by an infectious agent[24]. So it is possible that the fibrosarcoma in the lymph nodes in our study was the more frequently diagnosed neoplasia lymphosarcoma.

Splendore-Hoeppli phenomenon means eosinophilic material (radiate, star-like, asteroid or club-shaped configurations) around a microorganism like parasites[42].
A Splendore-Hoeppli phenomenon was microscopically found in 3 seals. Microscopic visible were multiple hard eosinophillic colored radiar depositions in the parachema. In another research this Splendore-Hoeppli phenomenon was also detected in two cases. In this research microscopically was seen eosinophilic hyaline masses around the helminthic parasites. Reticulin fibers were sometimes found within and around the eosinophilic masses[43].

Endocrine

The thymus was present in 39 seals. Some carcasses were too autolytic to be able to discover the thymus. In other cases the assistant pathologist was unable to find the thymus, because of lack of experience. The thymus becomes atrophic with advancing age, this reduction in size occurs normally after sexual maturity. Malnutrition also induces thymic atrophy, with an effect of reduction in the numbers of circulating T-lymphocytes and other thymic hormone output. Also the concentration of the hormone leptin is reduced in emaciated animals, this also leads to immunosupression[34].

To learn more about the immune system of seals, additional research should be performed on the thymus. Assistant pathologist should be informed were the thymus is located. Another diagnostic method to learn more about the immune system is blood examination. Most seals were found dead, so no blood examination can be done. However better research should be performed on lymph nodes, spleen and thymus. In the study of U. Siebert an Schumacher et all lymphocyte depletion of the spleen and lymph nodes were described[15]. This was not seen in this present study.
53 seals were brought to the rehabilitation center. When seals enter Ecomare, blood of those seals should be taken and a blood examination should be performed, so that an image can be obtained of the immune system of both common and grey seals, in all age categories.

Central nervous system

Causes of inflammation of the central nervous system are hematogenous, by nervous system or direct extension such as penetrating trauma[34].
Encephalitis is found in one adult seal. Encephalitis has been attributed to morbilliviruses, herpesviruses, rabies, bacteria, fungi, *Toxoplasma gondii*, and *Sarcocystis neurona* infections[24]. The Carre staining was negative, so this animal was probably not infected by morbilli virus. Unfortunately further examination to find the cause of the encephalitis was not done. 2 other neonate seals had a meningitis.

Eyes

Pinniped eyes are characterized by a large globe, prominent tapetum lucidum, mainly rods on the retina, rounded lens and a slitlike pupil[24]. A seal also has a good working lacrimanal gland. When the seal is dehydrated, this gland works less and a reduced amount of tearing is seen.
Ocular lesions are very common in both free-ranging and captive seals[24]. In this research 11 eyes were affected. Predisposing factors are chlorine disinfection (chloramines and other oxydizing agents), opportunistic pathogens, microtrauma, ultraviolet hypersensitivity, and pH imbalance factors. When a seal is blind it adapts very quickly by using his tactile and acoustic skills. This is why the diagnose of blindness is very difficult in seals[24].

In this research 5 seals were diagnosed with hyphaema (mostly bilateral), 4 seals with conjunctivitis and 2 seals with an exopthalmus. A lot of animals had no eyes because of scavenging, so an examination on the eyes could not be performed.

Parasites

The determination of parasites was done with 60 seals. To get a more realistic view, all parasites of all seal carcasses should be examined and determined. This was not done in this research.

Nematoda

8 common seals and one grey seal was infected with *Dipetalonema spirocauda*. An infection with *Dipetalonema spirocauda* in a grey seal is very rare.
Transmission of *Dipetalonema spirocauda* is thought the seal louse (*Echinophthirius horridus*)[28] This louse can cause skin irritation and anemia. The microfilariae from *Dipetalonema spirocauda* are sucked up by the seal louse, the parasite develops in the louse, and by blood sucking passes on to the next seal. *Echinophthirius horridus* is found only four times on seals and more infections with *Dipetalonema spirocauda* were found, so there is probably another unknown transmission. Seals can also be infected intra uterine, because *Dipetalonema spirocauda* can be found in seals with an age of one month[44]. This was not discovered in this study.
Dipetalonema spirocauda infection can frequently be found in the 1 to 2-year-old seals[25], this research had a similar outcome this parasite was only found in neonates and juveniles.

Seals get lungworms form eating fish, which is an intermediair host containing an infective third-stage larvae[28]. When seals are infected they showing clinical signs like anorexia, coughing, and sometimes blood-flecked mucus[28]. In this research 70 seals (46,6%) were infected with lungworms.
Otostrongylus circumlitus is macroscopic visible and causes obstructions with catarrhal or purulent bronchitis or bronchopneumonia[26]. *Otostrongylus circumlitus* was determined in 20 seals: 9 neonates and 11 juveniles.
Parafilaroides gymnurus is not macroscopically visible and causes bronchiolitis and causes a bronchopneumonia with pulmonary atelectase and emphsyma[26]. A way to determine *Parafilaroides gymnurus* is histological examination of the lungs or to solve sputum from the seal in water, put it in a petridish and watch it under a microscope. This was not done in every seal, so it is possible that during the necropsy a *parafiloides gymnurus* infection was not macroscopically discovered and not diagnosed. In this research it was only determined 7 times. Infections with *Parafilaroides gymnurus* are more pathogenic than infections with *Otostrongylus circumlitus*[12].

The grey seal is less infected by the lungworms, in this research 4 grey seals (23.5%) were infected [44]. Possible explanations are species susceptibility, foraging strategies, level of immunosuppressive toxins and genetic variability of the species.

Parasites in the lungs were macroscopic found in 38 neonates, 30 juveniles and 2 adults with a mild infection. Mostly neonates were infected with lung parasites.
Parafilaroides gymnurus and *Otostrongylus circumlitus* infection can be found by young seals[44]. Seals appear to suffer from parasites infections of the lungs between 1 and 18 months, this may be correlated with the short lactation period of 4-6 weeks and a higher pressure on the immune system during the first months after weaning[15]. It appears that seals suffer from parasitic bronchopneumonia at a much younger age now compared with previous decades. When the seal is older than one year, the animal build up immunity, and has as result, no clinical manifestations of a parasite infection[44,13]. Like the 2 mild infected adult seals, without a pneumonia.

An increase in parasitic infection in the lungs is seen[15]. In this research 15 parasitized animals were stranded in 2009, 24 in 2010, 13 in 2011 and 18 in the first quarter of 2012. So a higher infection state of the lungs was found in the year 2010 and already in the first quarter of 2012. Explanations for a higher mobility and mortality due to parasitic lung infections are:

1. A bigger seal population, every year more seals are counted on the coastline, this causes a higher degree of infections.
2. Changing in fish population, seal eating more infected fish species.
3. More emaciated seals in the population, which can lead to a less working immune system. Those animals are more sensitive for a infection of for example the lungs. With an infection of the lungs, animals dive less. Which leads to catching lower amounts of fish, leading again to emaciation(see figure 33).
4. More pollution of the environment, what also can lead to a less working immune system[5].
5. Genetic, an increase in homozygosity and a loss of genetic variation is seen. Also a lot of seals grow up with the help of rehabilitation centers, thus there is no survival of the fittest[6]. No survival of the strongest genes.
6. Reduced immunity caused by diseases like morbilli virus epidemic (in 1988 and 2002)[15].

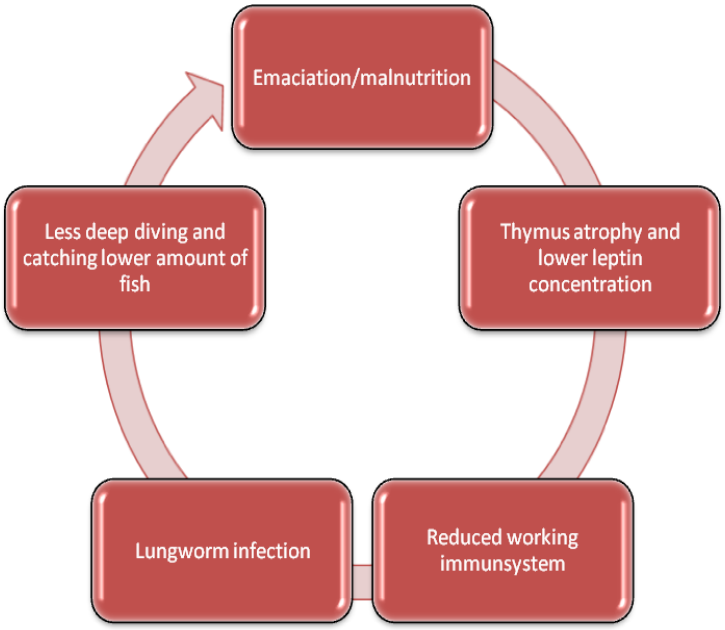

Figure 33: Emaciation cycle

Pseudoterranova decipiens and *Contracaecum osculatum* give no clinical signs, but sometimes can give complications like stomach ulceration and stomach perforations, which leads to an acute fibrinous peritonitis[44]. This research had a similar outcome these parasite causes hyperemic mucosa, ulceration or erosion of the stomach wall, thickened stomach wall and mucous, hemorrhagic or pica contents, no perforations were seen.
In total 64 seal stomachs contain parasites: 25 neonates, 28 juveniles and 11 adults.14 parasitized animals were stranded in 2009, 23 in 2010, 17 in 2011 and 9 in the first quarter of 2012. So again a higher infection state was found in the year 2010.

Trematoda

The prevalence of *Ascocotyle septentrionalis* increased with increasing age of the seals. This parasite can be found more in male seals than in female and younger animals[16].

In this study only 5 seals (1 neonate, 3 juveniles and 1 adult) had an infestation of this parasite in the intestines. Thus a comparison cannot be made.
Cryptocotyle lingua can be found in the intestine and are usually not pathogenic. This parasite was determined 4 times: 1 neonate and 3 juveniles. Their life cycles include snails as first intermediate hosts and fish as second intermediate hosts, in which metacercariae become encysted[28]. This fluke causes black spot disease in the secondary host the fish[45]. Pancreatic fibrosis due to trematodiasis can be found in the necropsy[28] but was not found in this study.
Those trematode parasites were not macroscopic visible. The way to collect those parasites is to wash out the intestines contents and collect it in a plastic bucket. These contents and water filtering with a 150µm sieve and watch the parasite filtrate with a binocular. This method of collecting parasites was performed on only 7 seals, to get a better view of parasites in the intestine more seals should be examined this way.

Ectoparasites

Halarachne halichoeri was found in 2 grey neonate seals, this parasite can only be found in grey seals. Clinical signs are mucous or muco-purulent nasal discharge, sneezing and coughing trying to clear the nasal passages, facial pruritus and head shaking, leading to an upper respiratory tract infection, like a sinusitis.
The life cycle stages of this mite are a free-living hexapod, followed by octopod protonymph and deutonymph, and eventually by the adult. The transmission of *Halarachne halichoeri* is by direct spread of hexapod larvae from seal to seal[46].

Antiparasitic treatment

Ivermectin (0.2 mg/kg) was given the second day to 36 seals in the rehabilitation center Ecomare with pulmonary complaints. This is an anthelmintic medicine, that works on the glutamate-gated chloride channels, leading to paralysis and death of the parasites[47]. The best way to give this medicine is orally, because parental is less effective because of the thick blubber layer on seals. Ivermectine results in a reduction in mean larval excretion in ten days. The clinical sings like rapid breathing rate and dyspnea were getting less after 30 days. Ivermectine is high effective against major nematodes, but their efficacy against *Parafilaroides gymnurus* lungworms may be more limited[26].
In this research 13 seals had a *Otostrongylus circumlitus* infection, 5 seals a *Parafilaroides gymnurus* infection and by 8 seals undetermined nematodes in the lungs were found despite of the ivermectine medication. Some seals were treated for a few days, in these cases it is normal to find them. However 6 seals that were in the rehabilitating center for more than 10 days and still had lungworm infection. These seals were mostly stranded in 2012, one in 2011. It is not possible to determine if these lungworms were alive ante mortem. Further research should be done on antiparasitic medication and potential Ivermectine resistance. Seven seals had no parasites in the lungs, but still a pneumonia was present in these lungs, but a bacterial infection can be a common complication[26].

Bacteriology

Brucella infection can be found in cetaceans and seals. *Brucella* spp. have zoonotic potential[48]. The main route of infection in humans is by eating infected animals[49]. *Brucella* Spp. was diagnosed twice in this research, in one adult and one juvenile seal. Macroscopic lesions were an enlargement of lymph nodes, liver and spleen, irregular liver surface with multifocal white spots, hemorrhages in different organs like kidneys and lungs. Microscopically a hepatitis and pneumonia was visible. Brucellosis was diagnosed in samples of liver, lungs, lungworm and genital organs of those 2 seals.
Other pathological findings in another study on marine animals with brucellosis are subcutaneous abscesses, placentitis/abortion, epididymitis, lymphadenitis, mastitis, spinal discospondylitis, peritonitis, a mineralized lung granuloma, hepatic abscesses, hepatic and splenic necrosis, and macrophage/histiocytic cell infiltration in the liver, spleen and lymph nodes[49]. Only 3 seals were examined on brucellosis in 2009. To get a more realistic view, all seal carcasses should be examined on brucellosis, particular the pregnant seals.

Virology

No morbilli, influenza or herpus virus was detected by microscopically or polymerase chain reaction (PCR) examination. Only 18 seals were examined on these viruses. To get a more realistic view, all seal carcasses should be virology examined.

Morbilliviruses

The morbilli virus infection killed a lot of seals in 1988 and 2002[14]. Therefore it is necessary to check dead stranded seals for this disease because this disease can strike again and kill a lot of seals for the third time. Morbilli viruses are transmitted through aerosol contamination. Clinical signs resemble canine distemper in dogs and include fever, serous or mucopurulent oculonasal discharge, conjunctivitis, keratitis, coughing, difficulty breathing, pneumonia, diarrhea and abortion. The central nervous system is affected, most commonly the cerebrum. Nervous signs were muscle twitching, atypical posture, and increased tolerance to humans. Subcutaneous emphysema of the cervical and thoracic regions causes increased buoyancy and interferes with diving. Also skin lesions have been found on pinnepeds. Common seals are more susceptible to Phocide Distemper Virus than grey seals[24].

Influenza Viruses

A new strain of influenza virus is found in common seals, this is a potential zoonotic strain. This news was given in July 2012. It is an H3N8 strain and found in 5 seals from New England USA. Clinical signs were skin lesions and pneumonia. H3N8 strain has been circulating in North American birds since 2002[50]. Seals in the Wadden Sea should also examined on this strain for the interests of public health.
Other influenza types that can be found on seals are: Influenza A viruses namely H7N7, H4N5, H4N6 and H3N3. Influenza B was diagnosed in 1999 in the Netherlands. Clinical signs were weakness, uncoordination, dyspnea, pneumonia and conjunctivitis[24].

Herpes virus

Herpes viruses have been isolated from common seals, grey seals, and a California sea lion. Phocid herpesvirus type-1 (PhHV-1) was found in seals in northern European waters and on the coasts of the United States. Phocid herpesvirus-2 has been isolated in the Wadden Sea. Clinical signs are skin lesions (2 cm in diameter), encephalitis and esophagus ulcerations. Phocid herpesvirus type-1 (PhHV-1) was found in neonates and causes respiratory problems[24]. Encephalitis and skin lesions (on the body and in the mouth) were found on animals in this present study, but no further examination was done, so there is a possibility that some animals were infected.

In overall, more histopathological, immunohistochemical, polymerase chain reaction, microbiological and parasitological examinations should be performed, preferably on all animals, so that more information can be given about the health status of the Dutch seal population. Examinations to provide more clarity about seal pathogens cannot be performed because of budget limitations.

Causes of death

Euthanisia

In this study the major cause of death was euthanasia, 39 seals (26 %) were euthanized in the rehabilitation center Ecomare. This considered 28 neonates, 10 juveniles and one adult. 32 seals, mainly neonates and some juveniles, were euthanized because of respiration problems. Most of those animals were infected with lungworm, these were not always found during pathological examinations. Signs that those animals showed were dyspnea, increased lung sounds, coughing lungworms, blood on their nose and mouth etc.
Another study from N. Osinga did not use seal carcasses that died during rehabilitation for pathological examination because the mortality may have been influenced by the rehabilitating process. In this present study the carcasses of the rehabilitation center were useful, so that pathological abnormalities can be found and the influence of medicines can be obtained.

Infectious disease

34 seals (22.7% with confidence interval 0.16 to 0.29) died of an infection disease. This considered 32 common and 2 grey seals. In 17 seals (11.3% with confidence interval 0.06 to 0.16) the inflammation could only be found in the lungs. In 10 seals (6.7% with confidence interval 0.03 to 0.11) the infaction had spread to more than one organ, the organs that were mostly affected were the lungs and liver.
Common seals appear to be more susceptible to infectious diseases than grey seals[12]. In common seals an increase in homozygosity and a loss of genetic variation was found, maybe this is the reason that common seals are more susceptible to infections[6].

In comparison with the study of N. Osinga 59 common (20.6%) and 8 grey seals (8.6%) died of an infectious cause. A parasitic bronchopneumonia was a common cause of death with a percentage of 4,6%. Only 2 seals died of septicaemia (0.7%)[12].
In this present study an higher percentage of bronchopneumina was found in comparison with the study of N. Osinga, but in the research of N. Osinga there were more living stranded animals affected with a parasitic bronchopneumonia, those seals were not used in that study (see euthanasia).

In the study of U.Siebert 26.7% died of a bronchopneumonia caused by parasitic and bacterial infections, and 13.8% of septicaemia[15].
In this study 41 seals (27,3%) had a parasitic pneumonia, this percentage is almost the same compared to the study of U. Siebert. However not all the animals with a pneumonia died because of an infectious cause, also euthanasia, emaciation, bycatch and unknown cause were decided as cause of death (see additional graphic on the end).

Trauma

Trauma as cause of death was found 13 times (8.7%, with confidence interval 0.04 to 0.13), in 11 common and 2 grey seals.
This percentage is higher than the reports of N. Osinga and U. Siebert, this is because different studies had different interpretations of trauma.
In the study of N. Osinga only 5 grey seals died from trauma. These animals had different traumatic lesions[12].
In the study of U. Siebert in total 13 seals (3.7%, lower than the confidence interval) died of trauma. These animals had multiple fractures and/or ruptured intestinal organs and body cavity or intra-pericardial hemorrhage[15].

In this present study the location of trauma was mainly found on the head, neck and thorax. Pathological findings were hemorrhages on the body, fractures of bones and lung hyperemia and/or edema.
The causes of trauma were rarely identified. Possibilities of trauma are animals dashing against objects like dikes with storms and high seas, injuries from other animals and trauma due to humans.
In the study of N. Osinga it is suggested that grey seals are maybe more prone to non infectious causes of death because of their playful and inquisitive behavior[12].
In this present study an equal amount of grey seals died because of trauma and infectious disease. However the researchers opinion is that grey seals are less affected by infectious pathogens (less grey seals stranded in this study) because of the significantly higher genetic variation in grey seals compared with common seals[7].

Bycatch

Bycatch as cause of death was found 6 times (4%, with confidence interval 0.01 to 0.07) in 1 neonate and 5 juveniles. This is lower than the reports of N. Osinga where a 15-19% by catch rate was reported, but this study was done from 1979 till 2008[12].
In the late seventies and early eighties bycatch caused death in 10 % of the seal population in the Wadden Sea. These seals had a good body condition, no trauma, fish remains in stomach, presents of only lung edema and no other pathological findings. In that research they assumed that animals drowned from fishing lines and traps[51].
In the study of N. Osinga the occurrence of bycatch was higher in the period 1979-1993 than in the period 1994-2008. The number of bycatch cases was never higher than one case a year except in 2008, when there were 3 cases[12]. In this present study there was one case in 2009, 3 cases in 2010 and one case in 2011. So this finding is similar.
Pathological findings in this present study were hemorrhage on the body, edema in the lungs, foam or fluid in the lungs, fractures of bones, rupture of the lungs and reddish meninges.
In this study bycatch was more frequently seen in juveniles. In other researches it was found more in juveniles and adults and in another study in yearlings[12].
Bycatch in this present study was mostly found in the months May and September, but also in June and December seals died of bycatch. In the study of N. Osinga higher numbers of bycatch were found in the months March-May and August. Low numbers in June and July because different and/or less fishing by mother seals during pupping season. Another possible explanation was seasonality of certain types of fishery[12].

So at least 55 seals (36.6%) died or were euthanized because of lung problems, this is the most common cause of death. These lung problems could be found in neonates and juveniles, due to lungworm infection with or without a secondary bacterial infection.

Generally the health status of common and grey seals in the Wadden sea appears to have improved compared with earlier decades (before 2002). Every year more seals are counted on the Dutch shores. This may be due to the stop of hunting seals, to less pollution of the Wadden sea and more warning information of organization to the people[52].
However, in this present study more seals stranded every up following year and parasitic infections is a very common finding in seals now-a-days. Therefore, monitoring the health status of seals should continue, because an increasing prevalence of parasites infections was found (namely in 2010 and 2012) and every moment a new threat can come.

Conclusion

From 2009 till the First quarter of 2012, 150 seals (133 *Phoca vitulina* and 17 *Halichoerus grypus*) stranded in the province North Holland included Texel. 97 seals were found dead on the coast line, 14 seals found dead in Ecomare and 39 seals were euthanized in Ecomare. All those seals were pathologically examined at the University Utrecht, Faculty of Veterinary Medicine. Dept. Pathobiology. Most seals, both common and grey seals, stranded in the month December, mostly on the North Holland island Texel.

Seals were divided in age categories based on their total length (see table 1). This leads to 68 neonates, 53 juveniles and 28 adults in this research.
The mean blubber thickness of neonate seals was of 12 mm (common seals) and 11 mm (grey seals) and a mean NCC of 4. This means that most neonates were ill fed and had a bad nutritional condition.
Juveniles had a mean blubber thickness of 16.4 mm (common seals) and 24.8 mm (grey seals). Adults had a mean blubber thickness of 27 mm (common seals). Both juveniles as adults had a NCC of 3. This means that most of the juveniles and adult were well fed and had a normal nutritional condition.

Histopathological, immunohistochemical, microbiological and parasitological examinations were performed.
The respiratory system was affected most by pathological changes. Pathological changes that were most commonly seen were nematodiasis (46.7%), pneumonia (36%) chiefly a bronchopneumonia and pulmonary edema (43.3%). Other important findings where: pulmonary emphysema, pulmonary hyperemia and foam and/or fluid in the airways.
The causes of pneumonia were lungworms (21.3%), bacteria (1.3%), unknown causes (7.3%) or both bacteria and lungworm (6%). Bacteria that were found in the lungs were: *Streptococcus* species, *Escherichia coli*, *Clostridium*, *Gemella* species and mixed cultures. Clinical sings that were seen on the living animals where respiratory signs like dyspnea and increased lung sounds.

Another organ system that was often affected was the alimentary system. Parasites that were macroscopically found in the gastrointestinal tract were found in the esophagus (13.3%), stomach (42.7%), intestines (26%), and liver (1.3%). These parasites could lead to lesions like ulceration and hyperemia in the mucosa. Pathological changes were commonly found on the liver, these changes were inflammatory (9.3%) by the bacteria *Streptococcen*, *Brucellosis*, *Escherichia coli* and mixed cultures, hepatomegaly (8%), and liver necrosis (8%).

A lot of seals were affected by trauma. Blunt trauma (37.3%) was associated with hemorrhage and/or edema in the subcutis, blubber or muscles. Locations of blunt trauma were the chest (18%), head (14%), shoulders (10%) and neck (8.7%), whereas sharp trauma was seen on the flippers (front 2.6%, back 1.3%). Skin lesions were found in 30 seals but this would probably be more, but due to scavenging no differentiation could be made. Also bone fractures (8.6%) were seen mostly on the skull (4.7%).

The most parasitic infections in seals were seen in 2010 in the gastrointestinal tract and in the respiratory tract as well. In the first quarter of 2012 also a higher number of parasitic infections in the respiratory tract was found.

The causes of death were euthanasia (26%), infectious cause (22.7%), unknown (19.3%), emaciation (13.3%), trauma (8.7%) and by catch (4%).
In total 36.6% of the seals (mostly neonates and juveniles) died because of respiratory problems. 32 of these seals (21.3%) were euthanized in Ecomare.

The other seals that died without human interference, died because of inflammation of only the lungs (11.3%) or inflammation of lungs and other organs (4%).

The population of seals is growing every year, which is a good thing. However more seals stranded, more seals are getting sick and more seals are infected by lungworms. Eventually those seals end up in rehabilitation center. So is there an healthy seal population? Is the seal population prepared for a new threat like the morbilli virus in 1988 an 2002?.

To answer this question, more research on lungworms is necessary. This can be done through more extensive histopathological examinations of the lungs, better diagnosis of the *Parafilaroides gymnurus* parasite, more research to the live cycle of the lungworms and investigation on antiparasitic medication.

Also more investigation should be done on the immune system of seals.
This can be done through blood examination on living animals and more pathological examination on lymph nodes, spleen and thymus in dead stranded animals.

Acknowledgements

The author is grateful to her supervisor dr. Jooske IJzer from the department of pathobiology, Faculty of Veterinary Medicine, Utrecht University for helping me with pathological examinations and with writing my thesis. I would like to thank Rebekha Fleis, Andrea Gröene, Jooske IJzer and Marja Kik for the histopathological examinations, Sjoukje Hiemstra for the assistance with the necropsies and information about the seals, parasitologist Dr. Herman Cremers for the determination and information of the seal parasites, coworkers of the Veterinary Microbiologic Diagnostic Center (VMDC) of Utrecht University for the bacteriology of the organs, Hans Vernooij for the statistics, Karolien de Vor for helping me with my English language and Eveline Mus for helping me with the necropsies on the seals. I sincerely thank head animal caretaker Mariëtte Smit and all coworkers from seal rehabilitation centre Ecomare, Texel and Imares.

Protocol SEAL autopsies

Part 1 Identification	Number	.....	GLIMS	.....
	Stranding date:			
	Autopsy date:			
	Autopsied by:			
Chip check[1]:				
□ yes / □ no	True location:	.....	NSO	.....
negative / positive	Provided by:	□ EHBZ □ EcoMare □ Other		



Diagram 1 – blubber thickness

(including skin)

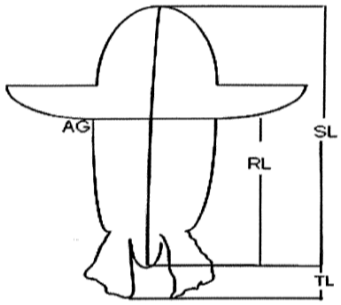

Diagram 2 - morphometry

Part 2 Biometrics	Morphometry (see diagrams above)	Blubber thickness **neck** (N)..... mm Blubber thickness **breast** (B)..... mm	**TL**.....cm **SL**.....cm **RL**.....cm **AG** (axillary girth).....cm
Sex:	□ ♂ □ ♀ (certain / uncertain) □ sex unknown		♂ large anogenital distance ♀ vulva located just ventral to anus
Body mass:	.....kg real / estimation		
Nutritive condition code:	□ NCC**1** □ NCC**2** □ NCC**3** □ NCC**4** □ NCC**5** □ NCC**6**		
Storage:	□ Direct delivery □ Cooled (ca. ……hrs) □ frozen □ other		
Expected age:	□ Neonate □ Juvenile □ Adult □ Unknown		
Decomposition DCC:	□ Very fresh DCC**1** □ Fresh DCC**2** □ Putrefied DCC**3** □ Very putrefied DCC**4** □ remains DCC**5**		
State of carcass:	□ fully intact □ peck or bite wounds □ incomplete □ skeletal parts, namely:		

Bycatch: (based on external observation only)	□ certain □ highly probable □ probable □ possible □ no evidence
Part 2 Photography	
Entire body	
Head only	
Snout	
Eyes	
Teeth	
Urogenital region	
External Observations (Specify lesion and location)	
Internal observations (Specify organ)	

Estimated significance of the presence/absence of criteria for the diagnosis of bycatch

Criteria	Presence	Absence	Observed
1. Health state			yes ? no
A. Exclusion of other causes of death	+	--	◻ ◻ ◻
B. Good nutritional condition	+	-	◻ ◻ ◻
C. Evidence of recent feeding	+	0	◻ ◻ ◻
2. Contact with fishing gear			
A. Superficial skin lesions			yes ? no
1. cuts in edge of mouth, fin or tail	++	0	◻ ◻ ◻
2. encircling lesions around extremity	++	0	◻ ◻ ◻
B. Bruises	+	0	◻ ◻ ◻
C. Skull fractures	+	0	◻ ◻ ◻
3. Lack of oxygen (hypoxia)			yes ? no
A. Oedematous lungs	+	-	◻ ◻ ◻
B. Persistent froth in the airways	+	-	◻ ◻ ◻
C. Bullous emphysema in the lungs	+	0	◻ ◻ ◻
D. Epicardial and pleural petechiae	+	0	◻ ◻ ◻
4. Damage during release of the net			yes ? no
A. Amputated fin, fluke or tail	++	0	◻ ◻ ◻
B. Penetrating incision into body cavity	++	0	◻ ◻ ◻
C. Rope around tail stock	++	0	◻ ◻ ◻
D. Gaff mark	++	0	◻ ◻ ◻
5. Other relevant characteristics			yes ? no
A. Sharp edged cuts or blubber defects on body	++	0	◻ ◻ ◻
B. Sharp edged cuts or blubber defects on mandible	++	0	◻ ◻ ◻

++ consistent with bycatch + bycatch possible 0 no significance for diagnosis - bycatch less likely -- bycatch unlikely

[1]**Kuiken T. 1994. Review of the criteria for the diagnosis of by-catch in cetaceans. *In:* Kuiken T. (ed.) Diagnosis of By-Catch in Cetaceans. Proc. 2nd. ECS workshop on cetacean pathology, Montpellier, France, 2 March 1994. European Cetacean Society Newsletter 26: 38-43**

Part 3 Pathology	Number	.....	GLIMS	.....
Necropsy form – 1				

External observations & lesions	
□ Scavenging	□ Severe □ Moderate □ Mild □ None
Subcutaneous observations & lesions	
□ Subcut. fat	□ Absent □ Present, approximate thickness: …….

Part 3 Pathology	Number	.....	GLIMS	.....
Necropsy form - 2				

Internal observations & lesions

Abdomen (tick if normal, describe if abnormal) □ Urinary bladder □ Mesenteric LN □ Intestine □ Stomach □ Spleen □ Pancreas □ Liver □ Adrenal □ Kidney □ Genital tract □ Gonads	Sex □ ♂ □ ♀ □ ND Age □ Neonatal □ Juvenile □ Adult □ Undetermined
Thorax (tick if normal, describe if abnormal) □ Trachea	

□ Lungs □ Bronchial LN □ Heart □ Oesophagus □ Thymus (present/absent)	

Part 3 Pathology	Number	.....	GLIMS	.....
Necropsy form - 3				

Head and Neck (tick if normal, describe if abnormal) □ Larynx □ Thyroid □ Oral cavity □ Nostrils □ Eyes □ Teeth □ Auditory system □ Skull □ Brain	
Conclusions	

Probable cause of death	

Part 6 Sample Collection	Number	.....	GLIMS	.....
Sample list				

	HP	-80	-20	Alchol / Glycerin	TX Alu	TX PL	TX PL	Life History
Skin		Lesions	Lesions					Skin&Hair
Blubber					3x TX	TX	TX	
Muscle					TX	TX	TX	
Genital split			Swab					
Mam.gland/penis								
Gonad & reproductive tract								
Reproductive tract LN								
Placenta, umbilical cord								
Urinary bladder								
Ileocecale LN								
Mesenteric LN								
Pre scapular LN								
Stomach				Parasites			SB	
Pancreas								
Spleen								
Liver				Parasites	3x TX	TX	TX	
Kidney					3x TX	TX	TX	

Adrenal								
Lung			Parasites	Parasites				
Pulmonary LN								
Heart								
Blood & / Serum								
Thymus								
Thyroid								
Eye								
Teeth								2x Mandible
Cerebellum								
Cerebrum								
Intestine								
Intestinal contents								
Rib cartilage								Ontkalking
Collection/ DCC correlation	DCC 1		DCC 2		DCC 3		DCC 4 and 5	

Additional graphic: pneumonia causes (total number of seals)

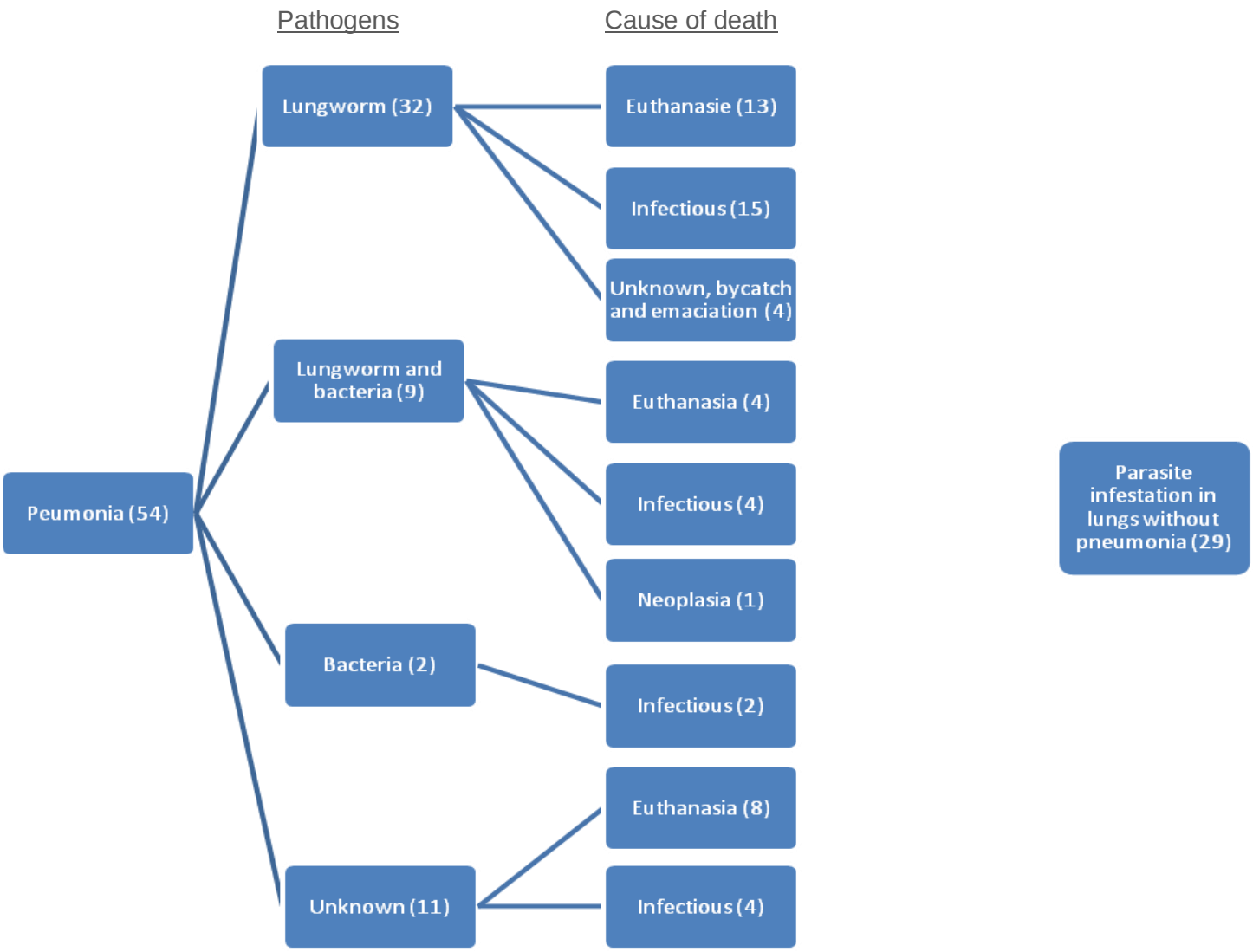

References

1. Imares. Meer zeehonden in de waddenzee, webpage: http://www.imares.wur.nl/NL/nieuwsagenda/nieuws/Meer_zeehonden_in_de_Waddenzee.htm; .

2. Brasseur, S. Borchard, T. Czec, R. Jensen, L.F.Jørgense, A.G. Ramdohr, S. Siebert, U. Teilmann J. Trilateral Seal Expert Group: Commen Seals in the Wadden Sea in 2011. Aerial Surveys of Harbour Seals in the Wadden Sea in 2011 - Solid increases in total number as well as pups. http://www.waddensea-secretariat.org/news/news/Seals/Annual-reports/seals2011.html
. (november 2011).

3. Hueffer, K. *et al*. Serologic surveillance of pathogens in a declining harbor seal (*Phoca vitulina*) population in Glacier Bay National Park, Alaska, USA and a reference site. *J. Wildl. Dis.* 47, 984-988 (2011).

4. Ecomare. Zeehonden, webpage: http://www.ecomare.nl/ecomare-encyclopedie/organismen/dieren/zoogdieren/roofdieren/vinpotigen/zeehonden/; .

5. Dr. K. Zijlstra, Dr. T. Kuiken, Dr. Ir. P.J.H. Reijnders, Dr. H.J. Lindeboom, Drs. J.M. Revier, Dr. Ir. J. Kuiper, Prof. Dr. A.D.M.E. Osterhaus, Dr. M.L. Eggens, Dr. F. Stafleu. COMPILATIE VAN GEGEVENS OVER ZEEHONDEN EN ZEEHONDENOPVANGIN DE NEDERLANDSE WADDENZEE. (SEPTEMBER 2002).

6. Kappe, A. L., Bijlsma, R., Osterhaus, A. D., van Delden, W. & van de Zande, L. Structure and amount of genetic variation at minisatellite loci within the subspecies complex of Phoca vitulina (the harbour seal). *Heredity (Edinb)* **78 (Pt 5)**, 457-463 (1997).

7. Kappe, A. L., van de Zande, L., Vedder, E. J., Bijlsma, R. & van Delden, W. Genetic variation in Phoca vitulina (the harbour seal) revealed by DNA fingerprinting and RAPDs. *Heredity (Edinb)* 74 (Pt 6), 647-653 (1995).

8. Atkinson, S. Reproductive biology of seals. *Rev. Reprod.* **2**, 175-194 (1997).

9. Reijnders, P. J., Brasseur, S. M. & Meesters, E. H. Earlier pupping in harbour seals, Phoca vitulina. *Biol. Lett.* **6**, 854-857 (2010).

10. Zeehonden crèche Lenie 't Hart, Pieterburen. Feiten over opvang zeehonden, Webpage: http://www.zeehondencreche.nl/wb/pages/zeehondenziekenhuis/opvang.php.

11. Mulder, J. L. Zeehonden opvang moet aan banden. De levende natuur. http://www.mulder-natuurlijk.nl/pdfs/zeehond%20DLN.pdf. (Maart 2005).

12. N. Osinga, M.M. Shahi Ferdous, D. Morick, M. García Hartmann, J.A. Ulloa, L. Vedder, H.A. Udo de Haes, P.M. Brakefield, A.D.M.E. Osterhaus, T. Kuiken,. Patterns of Stranding and Mortality in Common Seals (Phoca vitulina) and Grey Seals (Halichoerus grypus) in The Netherlands between 1979 and 2008. Journal of Comparative Pathology (24 May 2012).

13. Piche, C., Measures, L., Bedard, C. & Lair, S. Bronchoalveolar lavage and pulmonary histopathology in harp seals (*Phoca groenlandica*) experimentally infected with *Otostrongylus circumlitus*. *J. Wildl. Dis.* 46, 409-421 (2010).

14. Earle, J. A. P., Melia, M. M., Doherty, N. V., Nielsen, O. & Cosby, S. L. Phocine distemper virus in seals, East Coast, United States, 2006. *Emerging Infectious Diseases; 2011.17: 2, 215-220.26 ref*.

15. Siebert, U., Wohlsein, P., Lehnert, K. & Baumgärtner, W. Pathological Findings in Harbour Seals (Phoca vitulina): 1996–2005. *J. Comp. Pathol.* 137, 47-58 (2007).

16. Strauss, V. *et al*. The helminth fauna of the common seal (*Phoca vitulina vitulina,* Linne, 1758) from the Wadden Sea in Lower Saxony. *Journal of Veterinary Medicine*, Seres B-641-648. 27 ref (1991).

17. Jauniaux T., Beans C., Dabin W. Stranding, Necropsy and Sampling: Collection data, sampling level & techniques. *Euoapean Cetacean Society Workshop* (7 APRIL 2005).

18. Blundell G.M., P. G. W. Estimating age of harbor seals (Phoca vitulina) with incisor teeth and morphometrics. *MARINE MAMMAL SCIENCE, 24(3): 577–590* (July 2008).

19. Brucella I-ELISA antibody test.Brucella-Ab I-ELISA. On webpage: http://www.svanova.com/filearchive/Brucella%2007-03.pdf. (2007).

20. Detection of influenza A matrix gene by real time Taqman® RT-PCR. On webpage: http://vla.defra.gov.uk/science/docs/sci_ai_vi493.pdf; (18/09/07).

21. L. J. R. van Elden, M. Nijhuis, P. Schipper, R. Schuurman, and A. M. van Loon. Simultaneous Detection of Influenza Viruses A and B Using Real-Time Quantitative PCR.

22. Petrie A., W. P. in *Statistics for Veterinary and Animal Science, second edition. Chapter 9* , 2006).

23. Seguel, M. *et al*. Pathological findings in South American fur seal pups (*Arctocephalus australis gracilis*) found dead at Guafo Island, Chile. *Journal of Comparative Pathology; 2011.145: 2/3, 308-317.43 ref*.

24. Dierauf, Leslie A. and Gulland, Frances M.D. CRC Handbook of marine mamal medicine. (Second edition. 2001).

25. Borgsteede, F. H. M., Bus, H. G. J., Verplanke, J. A. W. & Burg, W. P. J. Endoparasitic helminths of the harbour seal, *Phoca vitulina,* in the Netherlands. *Netherlands Journal of Sea Research; 1991.28: 3, 247-250.16 ref*.

26. Vercruysse J, Salomez A, Ulloa A, Alvinerie M, Osterhaus A, Kuiken T. Efficacy of ivermectin and moxidectin against Otostrongylus circumlitus andParafilaroides gymnurus in harbour seals (Phoca vitulina). .

27. Broek, E. & Van Den. [English title not available] [Dutch]. *Lutra*, 28 (1963).

28. The Merck Veterinary Manual (MVM). Parasitic diseases in marine mammals. (2011).

29. Spraker, T. R. & Lander, M. E. Causes of mortality in northern fur seals (*Callorhinus ursinus*), St. Paul Island, Pribilof Islands, Alaska, 1986-2006. *Journal of Wildlife Diseases; 2010.46: 2, 450-473.many ref*.

30. Barnett, J. E. F., Woodley, A. J., Hill, T. J. & Turner, L. Conditions in grey seal pups (*Halichoerus grypus*) presented for rehabilitation. *Veterinary Record; 2000.147: 4, 98-104.43 ref*.

31. J. R. Baker, P. D. Jepson, V. R. Simpson, and T. Kuiken. Causes of mortality and non-fatal conditions among grey seals (Halichoerus grypus) found dead on the coasts of England, Wales and the Isle of Man. Veterinary Record 1998;142:595-601 doi:10.1136/vr.142.22.595.

32. Pitcher, K. W.,. Variation in blubber thickness of harbour seals in soutern Alaska. J. Wildl. Manage. 50 (3): 463-466 (1986).

33. McCarthy, A. J. *et al*. Variation in European harbour seal immune response genes and susceptibility to phocine distemper virus (PDV). *Infection, Genetics and Evolution* 11, 1616-1623 (2011).

34. McGavin, M. Donald, Zachary, James F. in *Pathologic basis of veterinary disease* , 2007).

35. Aquatic mammals. Foramen Ovale and Ductus Arteriosus Patency in Neonatal Harbor Seal (Phoca vitulina) Pups in Rehabilitation. On webpage: http://www.aquaticmammalsjournal.org/index.php?option=com_content&view=article&id=526:foramen-ovale-and-ductus-arteriosus-patency-in-neonatal-harbor-seal-phoca-vitulina-pups-in-rehabilitation&catid=37:volume-37-issue-2&Itemid=121. , 161-166.

36. Siebert, U. *et al*. Post-mortem findings in harbour porpoises (*Phocoena phocoena*) from the German North and Baltic Seas. *Journal of Comparative Pathology; 2001.124: 2/3, 102-114.50 ref*.

37. Nordøy, E. Gastroliths in the harp seal Phoca Groenlandica. *Polar Res.* 14 (1995).

38. Dennison Sophie, Gulland Frances, Haulena Martin, De Morais Helio, Colegrove Kathleen. Urate nephrolithiasis in a northern elephant seal (Mirounga angustirostris) and a california sea lion (Zalophus californianus). (2007).

39. UCD College of Agriculture, Food Science & Veterinary Medicine. Marine wildlife rehabilitation. (2008).

40. Brown Richard J., Smith Alvin W., Keyes Mac C. Renal fibrosarcoma in a Northern fur seal. (January 1975).

41. Stroud, R. K. & Stevens, D. R. Lymphosarcoma in a harbor seal (Phoca vitulina richardii). *Journal of Wildlife Diseases; 1980.16: 2, 267-270.5 ref*.

42. Hussein, M. R. Mucocutaneous Splendore-Hoeppli phenomenon. *J. Cutan. Pathol.* 35, 979-988 (2008).

43. Schumacher, U., Horny, H. P., Heidemann, G., Schultz, W. & Welsch, U. Histopathological findings in harbour seals (Phoca vitulina) found dead on the German North sea coast. *Journal of Comparative Pathology; 1990.102: 3, 299-309.15 ref*.

44. Vedder, E. J. Wormen bij zeehonden. (sept-okt 1998).

45. Flukes (Trematoda). On webpage: http://www.holar.is/~aquafarmer/node137.html. (Feb, 2004).

46. Alonso-Farré, J. M., D'Silva, J. I. D. & Gestal, C. Naso-pharyngeal mites Halarachne halichoeri (Allman, 1847) in Grey seals stranded on the NW Spanish Atlantic Coast. *Vet. Parasitol.* **183**, 317-322 (2012).

47. Het College ter Beoordeling van Geneesmiddelen (CBG). Wijzigingsbeschikking Met Spc-Etiket-Bijsluiter van Ivomec. Op CBG-MED. (23 augustus 2010).

48. Brucellosis in Marine Mammals. (July 28, 2009).

49. Nymo, I. H., Tryland, M. & Godfroid, J. A review of Brucella infection in marine mammals, with special emphasis on Brucella pinnipedialis in the hooded seal (Cystophora cristata). *Veterinary Research; 2011.42: 93, (5 August 2011).154 ref*.

50. ScienceDaily. New Influenza Virus from Seals Highlights the Risks of Pandemic Flu from Animals. (July 31, 2012).

51. Reijnders P.J.H. , Brasseur S.M.J.M. , van Leeuwen P.W. , Smit C.J. Onderzoek naar vermindering van bijvangst van zeehonden in fuiken. On webpage: http://www2.alterra.wur.nl/Webdocs/PDFFiles/Alterrarapporten/AlterraRapport1211.pdf. (2005).

52. Peter J.H. Reijnders, Sophie M.J.M. Brasseur, Thomas Borchardt, Kees Camphuysen, Richard Czeck, Anita Gilles, Lasse Fast Jensen, Mardik Leopold, Klaus Lucke, Sven Ramdohr, Meike Scheidat, Ursula Siebert and Jonas Teilmann, 2009. Marine Mammals. Thematic Report No. 20. In: Marencic, H. & Vlas, J. de (Eds), 2009. Quality Status Report 2009. Wadden Sea Ecosystem No. 25. Common Wadden Sea Secretariat, Trilateral Monitoring and Assessment Group, Wilhelmshaven, Germany. Quality status report 2009, Marine mammals. On webpage: http://www.waddensea-secretariat.org/QSR-2009/20-Marine-Mammals-(10-03-05).pdf. (2009).