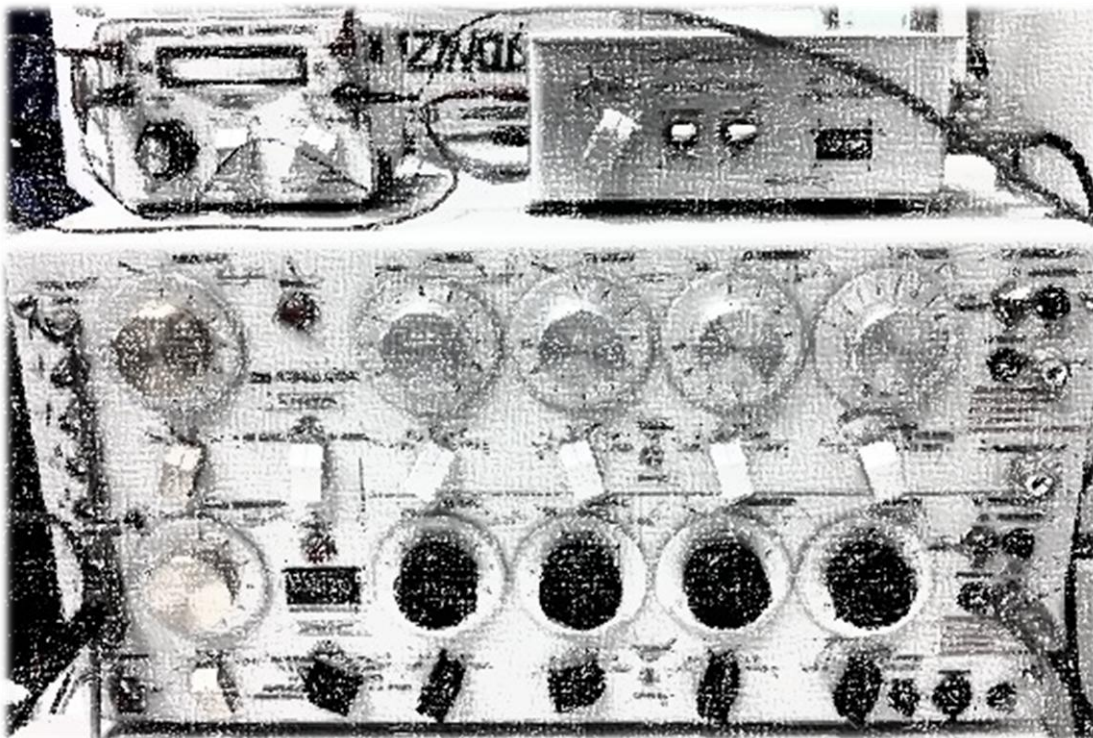


Recording somatosensory-evoked potentials by biotelemetry in common marmosets (*callithrix jacchus*), a pilot study



Research Project, Faculty of Veterinary Medicine, Utrecht University

Student: M.M. Hölscher

Studentnumber: 3259153

Supervisors:

Biomedical Primate Research Centre, Rijswijk: Drs. J. Bakker

Drs. R. Klomp

Utrecht University: Dr. S.S. Arndt

Department of Animals in Science & Society

Division of Animal Welfare & Laboratory Animal Science

Faculty of Veterinary Medicine, Utrecht University

January - June 2013

Abstract

Veterinary medicine has a lack of knowledge about objectively measuring pain and the efficacy of analgesics in non-human primates (NHP). Upcoming use of biotelemetry in animal research seems an improvement for studying nociception in animals. Biotelemetry has never been used for objective pain measuring in NHPs before. The aim of this study was to investigate whether somatosensory-evoked potentials (SEPs) can be monitored in common marmosets by the use of electrical stimulation of the skin and biotelemetric EEG devices in order to make a first step in studying the efficacy of analgesics in NHPs.

With use of noxious electrical stimulation of the skin peripheral somatosensory nociceptive A-delta fibers were activated in isoflurane-anesthetized marmosets, which resulted in nociception-related electroencephalographic SEPs. After testing two marmosets no SEPs could be monitored, where after the decision was made to stop this study. In the first marmoset, the waveforms' stimulus artefact was too broad for the SEP to appear. The second marmoset did not show any stimulus artefact or SEP in the waveforms at all. This all could be due to the used biotelemetric devices, such as the small bandwidth of the F40-EET transmitter or the insensitivity of the receiver.

This pilot study proved that the used biotelemetry devices are not suitable for monitoring and recording SEPs at this moment because of technical limitations.

Contents

	Page
Abstract	2
Contents	3
Introduction	4
Materials and methods	
<i>Animals</i>	6
<i>Surgery</i>	6
<i>Transmitter</i>	8
<i>Recording of somatosensory evoked potentials</i>	8
<i>Data analysis</i>	10
<i>Necropsy</i>	10
Results	
<i>General waveform characteristics</i>	11
<i>Necropsy</i>	13
Discussion	15
Conclusion	20
Acknowledgements	21
References	22
Appendix	25

Introduction

Veterinary medicine and biomedical research have a major lack of knowledge about objectively measuring pain and the efficacy of analgesics in the non-human primate (NHP). There are no objective scores of pain in NHPs and the standard analgesics have never been studied for their efficacy in these primates. According to the International Association for the Study of Pain (IASP), pain is defined as 'an unpleasant sensory and emotional experience associated with actual or potential tissue damage, or described in terms as such damage'.^{1,2,3} The sensation of pain originates from neuronal activity within the nociceptive system. In animal research, the terms 'pain' and 'analgesia' are often avoided, and replaced by the terms 'nociception' and 'anti-nociception' respectively. Nociception is defined as 'the neural process of encoding noxious stimuli'³, not definitely indicating conscious perception of the nociceptive stimuli. This terminology is more appropriate as animals cannot verbally communicate, consequently (except for behavioral responses) it cannot be assessed whether the animal actually experiences unpleasantness from the nociceptive stimuli applied.^{1,2} Also when considering unconscious animals under anesthesia, obviously nociception is the apposite term.

Next to behavioral animal models of pain, studying objective measurements of nociception in humans and other animals have recently been quantified successfully by the use of electroencephalography. The electroencephalogram (EEG) is a bioelectrical variable that cannot be measured by direct observation of the animal. A biomedical instrumentation to permit transmission of this biological information from the brain to a remote monitoring site is biomedical telemetry. This tool offers wireless, restraint-free, simultaneous, long-term data monitoring in animal studies.^{4,5} Biomedical telemetry therefore could be a useful reliable method for bioelectrical data gathering in an objective pain study.^{4,6}

With the use of a biotelemetry device, EEG can be monitored and thereby also evoked potentials can be recorded. Evoked potentials are fragments of EEG-activity time-locked to the administration of a certain sensory stimulus.^{1, 2, 7} When short stimulation of peripheral somatosensory fibers is applied, it results in electroencephalographic somatosensory evoked potentials (SEPs). Noxious stimulation of these fibers evokes SEPs that electroencephalographically appear as waveforms that represent the cortical processing of the noxious stimulus.² This specific neurophysiologic methodology of recording pain-related evoked potentials is considered a very promising approach for studying (anti)nociception in animals.^{1,8,9} Since SEPs evoked by noxious stimulation, represent neural processing of noxious stimuli and with neural processing of noxious stimuli being affected by anesthetic drugs, the drug-induced changes in SEP waveforms are considered to be related to an altered nociceptive state.^{1,10,11,12,13}

In rats, the SEP components in the 10-30 ms latency range after stimulus are believed to be of special interest in relation to nociception and analgesia. It is described that these SEP components have the advantage that they correspond with synaptic connections early in the neural pathway and consist of simple, sequential connections (primary processing of sensory information), which makes the interpretation of these waveforms relatively straightforward.^{1,14}

Electrical stimulation of the skin is described as an appropriate method to generate evoked potentials, in humans and in animals.^{8,9,15,16,17} When elicited in high intensity, the response reflects the level of activation of the nociceptive system (fast A-delta and slow C-fibres) next to the activation of the tactile system (A-beta fibres). However, the aim of this study is to solely activate the A-delta fibres because these are merely activated by nociceptive stimuli. It is described that electrical stimulation of the skin with the use of a low current intensity electrode preferentially activates the cutaneous A-delta fibres.^{16,17} This type of electrical stimulation in man evokes clear cortical responses at a weak intensity, which is not reported by the subjects as painful at all¹⁵, or only as a pin-prick-like pain sensation.¹⁷ The electrode itself can be fixated to the skin without penetrating or damaging the skin at the stimulus site.¹⁸ Depending on whether the stimuli are actually causing (tissue) damage or not, they are called noxious or nociceptive, respectively.² Electrical stimulation using a small electrode with short duration pulses of low current intensities results in nociception induced by nociceptive stimuli applied at the skin without damaging the stimulus site of the animal. The recorded SEPs are related to nociception and can therefore be used to quantitatively characterize the perception of noxious stimuli in pain- and analgesia-related research.^{1,8,16,17}

The aim of this pilot study is to investigate whether biotelemetry could be a valuable method to monitor nociception-related electroencephalographic SEPs in anesthetized marmosets as an important first step in objective pain measuring to ultimately study the efficacy of analgesia in NHPs.

Materials and methods

Animals

Five female adult common marmosets (*Callithrix jacchus*) born and raised at the BPRC were included in this study. Their age was 3.8 ± 0.3 (mean \pm SEM) years with a bodyweight of 367 ± 9 gram. Before inclusion, all marmosets received a complete physical, hematological, and biochemical examination performed by a veterinarian. The marmosets were housed with a same sex buddy for company of whom two buddies did not participate in the study. Housing conditions were in compliance with the directive 2010/63EU¹⁹ and consisted of standard cages filled with enrichment such as wooden poles and plastic tableaus and trays to sleep in. Cages stood in a room with conspecifics at constant ambient conditions; lights on between 07:00 - 19:00h, ambient temperature between 23.2 - 26.8°C. Animal care provided food and water ad libitum. Food was removed 16 hours prior to sedation, thus no regurgitation or vomiting could occur when the marmosets were sedated or recovering, which could cause reflux esophagitis or aspiration pneumonia. Water intake was never restricted. During the entire study, a veterinarian was present in order to monitor health and welfare of the animals.

Surgery

Three months before EEG recording the marmosets underwent surgery to place a transmitter for registration of EEG.²⁰ One day prior to surgery, 12.5 mg/kg amoxicillin (Synulox®, Pfizer Animal Health B.V., Capelle a/d IJssel, The Netherlands) was given orally twice a day as an prophylactic antibiotic. At least one hour preoperatively 0.20 mg/kg meloxicam (Metacam®, Boehringer Ingelheim, Alkmaar, The Netherlands) was administered orally and 0.020 mg/kg buprenorphine (Buprecare®, ASTfarma B.V., Oudewater, The Netherlands) was injected intramuscular (IM). For surgery, sedation was performed with injection of alphaxalone (Alfaxan®, Vétoquinol B.V., 's Hertogenbosch, The Netherlands), in 16 mg/kg IM. Combined with the administration of meloxicam and buprenorphine, this created 75 minutes of surgical anaesthesia, which was sufficient for the performed procedure. After sedation of the marmoset, head and abdomen were shaved carefully and washed with Hibiscrub and Betadine. Before initiating the actual surgical procedure, the marmoset was placed on a heat mat in order to maintain its body temperature.²⁰

A surgical method was performed that permanently equips the marmosets with a transmitter in their abdomen (fig 1A).^{21,22} Electrode wires originating from the intraperitoneally positioned transmitter were tunneled through the abdominal wall, subcutaneously via the shoulder area to the skull. There, in the skull, two small holes were drilled, using a dental circular saw, both 3 mm lateral (right) to the saggital suture and 2 and 9 mm cranial to the bregma, which represented the parietal and frontal cortex respectively.²³ These coordinates were previously used in marmosets in successful sleep EEG studies at the BPRC.²⁴ The electrode wires were protruded through these holes, placed on the dura and fixed by epidural electrodes (stainless steel screws), to connect them to the underlying brain (fig. 1B). Epidural electrodes provide a high amplitude EEG signal without muscle or movement artifact. Because they do not penetrate the dura the risk of infection is minor.²⁵ The screws were additionally attached to the skull by bone cement. Postoperatively the marmosets received oral meloxicam (0.10 mg/kg) once a day combined with buprenorphine (0.020 mg/kg IM) twice a day for a period of 2 days, which contributed to multimodal analgesia.

The transmitters were tested for functioning weekly and 142 days after surgery, SEP recording started.

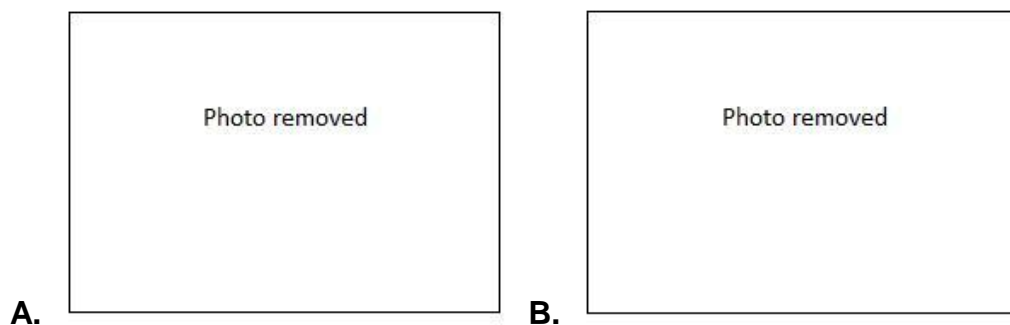


Fig. 1. A. Fixation of the transmitter to the abdominal wall. **B.** Position of the electrode wires fixed in the skull by epidural electrodes (stainless steel screws).

Transmitter

The transmitter (TL11M2-F40-EET, PhysioTel®, Data Sciences (DSI), St. Paul, MN, USA) for registration of EEG contained a battery, an amplifier and an epoxy encapsulated electronics module within a thermoplastic case, all coated in a biocompatible silicone coating. Enclosed in flexible silicone tubing, four stainless steel electrode wires originate from the transmitter. The manufacturers' specifications state the channel bandwidth to be 1-50 Hz, with a maximum input voltage of ± 1.25 mV. An internal switch enabled the transmitter to be turned on and off using a magnet, when passed within approximately 1-2 cm of the transmitter. Specifications state battery life can be maintained for 3 months if used continuously. All transmitters were tested before implantation.

Recording of somatosensory evoked potentials

To monitor EEG, the transmitter in the marmoset was switched on. The telemetric receiver (RPC-1, PhysioTel® Receivers, DSI) with a pick up range of approximately 20 cm was connected to a consolidation matrix (Dataquest A.R.T.™, Data Exchange Matrix, DSI). This matrix was connected with a computer that contained a data acquisition program (Dataquest A.R.T.™, DSI) and a data analysis program (Dataquest A.R.T.™ Analysis, DSI). A second loose transmitter and receiver were also connected to the matrix and computer in order to register solely the stimulus artefact without corresponding response in order to serve as a control.

After proper anesthetizing the marmoset with deep isoflurane administered by an anesthesia mask placed over the head of the marmoset, as judged by abolition of the nocifensive movements, the base of the tail was shaved carefully. Deep isoflurane, >1.6 minimum alveolar concentration (MAC), was needed continuously to keep the marmoset proper sedated. The marmoset was placed on a heat mat in order to maintain its body temperature. For electrical stimulation two custom-made stainless steel concentric stimulation electrodes (diameter: 1 mm) that were fixed in a piece of plastic tube which enclosed the tail⁷ were placed on the dorsal side of the tail base and firmly fixated to the skin by Velcro (fig. 2). The stimuli were generated by a Grass-stimulator (Model S-88, Grass Medical Instruments, Quincy, Mass, USA) and delivered to a Grass stimulation isolation unit (Model SUI 5, Grass Medical Instruments) and a constant current unit (Model CCU 1A, Grass Medical Instruments) to control the intensity.^{1,2,7}

Stimulus intensity-response characteristics were recorded in response to stimulus intensities of successively 0.0, 1.0, 2.0, 3.0 and 4.0 mA. Per intensity 32 square-wave electrical pulses of 2 ms duration were delivered with a stimulus frequency of 0,5 Hz. The sampling frequency was 250 Hz. Recordings were saved on the computer for analysis. Analyzing the cortical waves of the marmosets during the baseline measurements (before the actual measurements

with electrical stimulation) revealed that the EEG was sensitive to electrical 50 Hz-interference from the environment. Therefore, a cage of Faraday was used during the measurements and a 50 Hz notch-filter was applied to the data before analysis.^{1,2,14,22}

After stimulation at the different intensities, the transmitter was switched off and the marmoset was disconnected from the electrodes and the isoflurane. Latex gloves were filled with warm water and placed besides the marmoset's body to keep it warm during recovery. When the present veterinarian evaluated the marmoset becoming conscious, the marmoset was returned to its cage.



Fig. 2. *Two custom-made stainless steel concentric stimulation electrodes were placed on the dorsal side of the shaved tail base of the marmoset and firmly fixated to the skin by Velcro for electrical stimulation of the skin.*

Data analysis

Data were extracted from the Dataquest analysis program. The data consisted of 90-second recordings per stimulus intensity, which included the 64 seconds of actual stimulation. Calculations were performed with Microsoft Excel 2000 and Microsoft Excel for Mac 2011.

Data were analyzed with and without use of a 50 Hz notch-filter in the data-analysis program. However these data did not differentiate in waveform, so the filter was excluded during further analysis.

SEP data analysis was performed by visual determination of the 32 stimulus artefacts in each 90-second recording. Recordings of 400 ms (=100 data points) pre-stimulus and 800 ms (=200 data points) post-stimulus were extracted for analysis. These 32 epochs of 301 data points were averaged, which excludes the non-specific background-EEG, leaving only the stimulus-related EEG.^{7,26} These averaged data were plotted in a waveform to visualize the averaged stimulus artefact with the following averaged SEP per stimulus intensity.¹⁴ Since at 0.0 mA no responses could be recorded, these data were used as baseline noise and were not further analyzed for this intensity, leaving only 1.0, 2.0, 3.0 and 4.0 mA.

Necropsy

Necropsy was performed at the end of the study. The abdominal cavity was opened and all abdominal organs were inspected for possible trauma or inflammation caused by the transmitter. Electrode wires were followed to the skull to determine if they were still in place and if they caused any damage to the adjacent tissue. The skull was opened carefully to observe the indentation in the brain caused by the two screw electrodes in the skull.

Results

General waveform characteristics

After plotting the averaged recordings of the two marmosets, M08011 and M08018, these waveforms were observed to discover the SEPs (fig. 3). Figure 3 shows the averaged waveforms containing the 301 datapoints with the visually detected stimulus onset placed at the chosen data point 101. As in rats, the pain-related SEP arose from A-delta fibres in a marmoset tail is expected in the 10-30 ms latency range after stimulation^{1,14}, which is around data points 103-108 in the waveform, and with an amplitude around 20-40 μV .

The waveforms of M08011 (fig. 3A) showed an evident stimulus artefact. Unfortunately in every waveform the curve of the stimulus artefact appeared to be too broad for the possible SEP to become visible. The broad artefact clearly concealed the SEP.

The waveforms of the second marmoset M08018 (fig. 3B) showed no sign of stimulus artefact or any corresponding EEG response in the curve. Adjusting the scale of a waveform (fig. 3C) to visualize the smaller waves of cortical activity displayed that there was normal EEG activity in the anesthetized animal, but no sign of the stimulus or corresponding response could be discovered. Moreover, unfortunately M08018 died during recovery for unknown reasons.

Subsequently, creating a stimulus intensity-response curve without being able to create SEPs was of course impossible. Also for the welfare of the marmosets continuing these unusable measurements would not be ethically correct. Therefore, the decision was made to stop this study at this point.

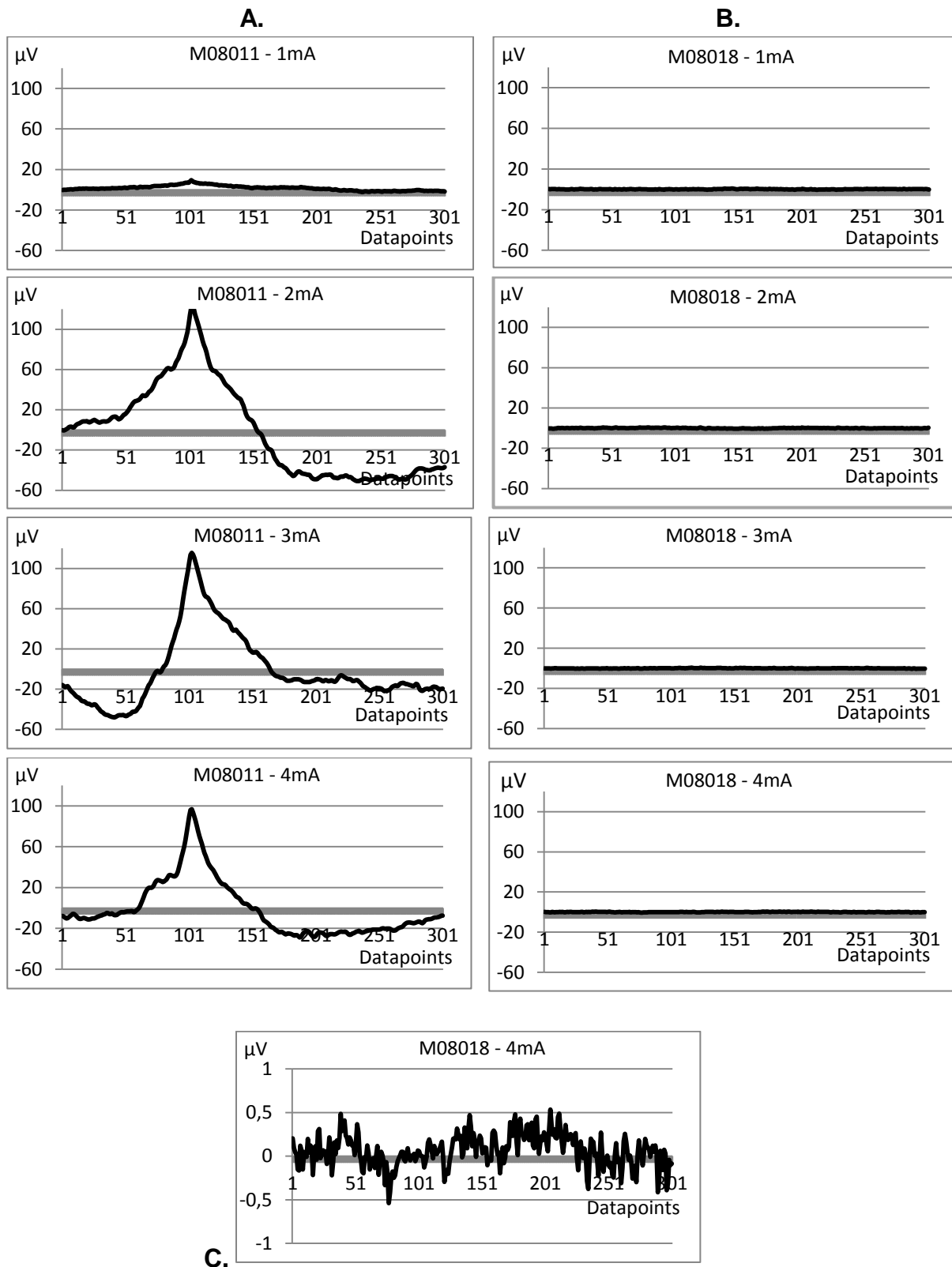


Fig. 3. Stimulus-response waveforms of the two marmosets; M08011 and M08018. Stimulus is given at datapoint 101. **A:** Waveforms of M08011; the stimulus artefact appeared to be too broad for a SEP to emerge. **B:** Waveforms of M08018; no stimulus artefact or corresponding EEG response became visible. **C:** The waveform of M08018 – 4mA with adjusted scale; showed that there was normal EEG activity in the animal under general anesthesia, but no sign of the stimulus.

Necropsy

Necropsy was performed on M08018, M08011 and one of the other three marmosets, M09006. The other two marmosets will be offered as surplus animals.

At necropsy of M08018, which died during recovery, severe focal hemorrhagic necrosis of the ceaco-colonial junction was discovered (fig 4C). The gastrointestinal tract cranial from the lesion was filled with food and the caudal tract was completely empty, so congestion of food was obviously severe. Because the lesion was located in the dorsal abdomen while the transmitter was fixated to the ventral abdominal wall, this lesion could not be directly linked to the abdominal transmitter. The reason for its gastrointestinal disease is still unknown. No abnormalities were found concerning the other abdominal organs or the placement of the transmitter and electrodes (fig 4A-B).




Fig. 4. Necropsy of M08018, macroscopic views. **A:** The abdominal organs and the ventral position of the intra-abdominal transmitter. **B:** The intact skull with screw electrodes and electrode wires still in place covered with bone cement. **C:** The gastrointestinal tract from the stomach (right) to the colon (left). The rectangle displays the focal hemorrhagic necrosis at the ceaco-colonial junction.

In the other two euthanized marmosets, visual inspection of the abdominal organs showed no sign of trauma or inflammation. Electrode wires were still intact, fixed at the right location and no adjacent tissue was damaged. All brains showed one or two macroscopic indentations caused by the epidural electrode screws. These indentations varied in depth between 0.1 – 2 mm (fig. 5). At some

of the deeper indentations the dura was not intact anymore, so the screw had penetrated to the subdural space into the brain tissue. Although for this study subdural placement of the electrodes was not required, this was not a disturbing finding. Biomedical implantable deep needle electrodes and plate electrodes exist that are intentionally placed into the brain tissue or subdural respectively for long periods of time, which are also tolerated well by animals.^{22,27} Moreover no marmoset has showed neurological signs or other signs of illness that could be due to the screw electrode placement when they were alive, so these deep indentations apparently did not have clinical relevance or negative effect on the health or welfare of the marmosets.




Fig. 5. Macroscopic views of the opened skull of M08018 (left), M08011 and M09006 (right). All three brains show indentations of the two screw electrodes.

Discussion

The present study investigated whether SEPs can be monitored in marmosets by the use of electrical stimulation and biotelemetric EEG devices in order to make a first step in studying the efficacy of analgesics in NHPs. Unfortunately the decision had to be made to stop this study after testing two out of five marmosets. The results after testing the first two animals made clear that this project design somehow did not result in useful data. It would be unethical to continue the measurements in the other three marmosets when this would be obviously futile. A useful ethical view in this case is the animal welfarists utilitarianism, in which the general rule is that the right actions are those that maximize utility summed over all those who are affected by the actions. In animal research this means that it is permissible to use animals in research if the relationship between the costs to the animals and the benefits for the research is such that the costs are less than the benefits.²⁸ In this study the benefits after monitoring the first two marmosets did not appear valuable enough for the costs of the other marmosets to continue this study.

Besides the distinct decision to stop this study, the explanation for these unexpected disappointing results is worth some discussion. The results obtained in marmoset M08011, were unusable because of the broad stimulus artefact. An explanation for this can be partially accused on the used telemetric receiver and transmitter. The receiver had a voltage range of 1250 μV , while the amplitude of a SEP merely reaches 20-40 μV (fig. 6). This means a SEP only requires 2-3% of the receivers' total voltage range, which could be too little for the sensitivity of the receiver to intercept. A receiver with a more appropriate sensitivity can be advantageous for measuring SEPs in future studies.

The used transmitter type was formerly used at the BPRC²⁴ for sleep EEG studies in marmosets.^{24, 29} For this purpose these transmitters were greatly suitable. But, in this study it works out that the appliance of electrical stimuli to these transmitters for registration of evoked potentials is not appropriate. The transmitters' channel bandwidth of 1-50 Hz appears to be too narrow. This low bandwidth does degrade the noise tolerance, but it inhibits the capacity of the channel and will thereby decrease the precision in the resulting data. A transmitter with a higher channel bandwidth is expected to lead to more precise registration of data and hence a narrow stimulus artefact. It improves the resolution and can even increase the amplitude of the SEP.³⁰ Unfortunately there are no implantable transmitters with such high channel bandwidths designed yet.

Another technical issue in monitoring and analyzing SEPs is data filtering. Registered data can be filtered in multiple ways to achieve a higher signal-to-noise ratio.²⁶ However, waveforms can be deformed and stretched by filtering. High-pass filters with low cutoff frequencies can increase the convergence to baseline, which means that the response to stimulation sustains longer and the amplitude of the waveform decrease.²⁶ In this study a 50 Hz notch-filter was applied before data analysis in attempt to visualize a SEP.^{1,2} Early data analysis showed no difference between the waveforms with or without use of the 50 Hz notch-filter, so this filter had clearly no impact on the results. Higher frequency filters were not used in this study because the transmitter did not register such signals. The transmitter's 40 Hz filter is the only possibility for deformation of the waveform of the possible SEP in this study. This filter cannot be excluded from the transmitter and frequency values lost by filtering cannot be restored from the filtered data itself.²⁶ So the impact of the transmitter's filter on the unfiltered data cannot be defined, but maybe a transmitter containing a filter with a higher cutoff frequency as a precaution will be a better choice in future studies.

These technical limitations show that technical devices can have major impact on the results and outcome of a study. Thorough research, selection and testing of all needed technical devices' capacities before starting an animal study is very important. Choosing and using suitable devices can lead to less unusable study designs, so consequently to a reduction in animal use.³¹

In this study the method of electrical stimulation preferentially activates the cutaneous fast A-delta fibers, with a conducting velocity of 4-30 m/s, which mediate the sharp, fast and well-localized pain sensations.^{1, 32, 33} In rats, these SEP components appear in the latency range of 10-30 ms after stimulation and the components in this latency range in rats have been shown to be highly sensitive to different anesthetic drugs.^{34, 35} Comparing the similar size and bodyweight of a rat with those of a marmoset, moreover the same location of electrodes and site of stimulation, the same SEP latency range would theoretically be of interest in this study with respect to nociception and analgesia. Fig. 6 shows an example of a SEP waveform recorded in a rat after electrical stimulation of 5 mA at the tail base, containing the three complexes usually described in a SEP waveform in multiple species and different types of stimulation.¹ Three complexes comprising positive-to-negative peaks are designated with P1, P2 and P3, of which the first complex (P1) is the complex of special interest in the 10-30 ms latency range. This example shows the small amplitude (less than 20 μ V) of this first complex. This demonstrates how these SEP components unfortunately disappear in the broad stimulus artefact recorded in this study. It was expected that the third very large complex (P3) would become visible when the stimulus artefact is in decline. However, these third complex SEP components did not appear in the data. The latter could be explained by the fact that the responsiveness of the nociceptive system in these late SEP components is

modulated during drowsiness and especially during sleep. In African green monkeys sleep significantly decreases the amplitude of these latter SEP components, or the third complex SEP components do not even take shape at all.³⁰

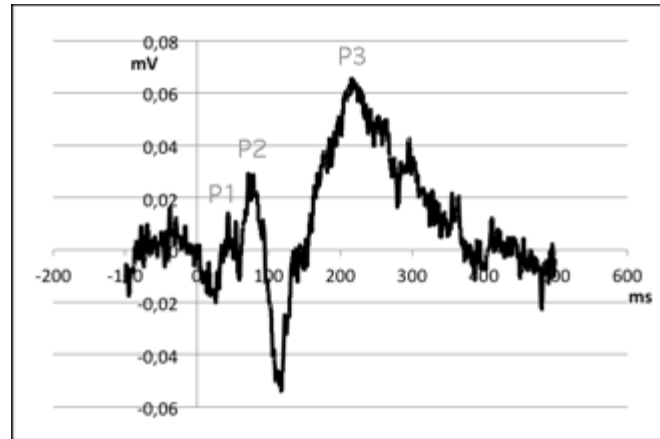


Fig 6. SEP waveform recorded from a rat after electrical stimulation of the tail base. Stimulation of 5mA is given at $t=0$. Three complexes of positive-to-negative peaks are visible of which the positive peaks are designated by P1, P2 and P3.^{stiener thesis, fentanyl 1}

Another explanation for the SEP not to appear can possibly be found in the use of deep isoflurane for anesthesia. Isoflurane was chosen as sole drug for anesthesia in this study because it had no or minimal analgesic effects.^{10, 36} It does not change the responses to pain induced experimentally in man with heat, cold or mechanical pressure neither the threshold for the summation of nociceptive reflexes to repeated electrical stimulations. This indicates the absence of analgesia or the negligible analgesic effects of isoflurane so it would not be of clinical relevance.³⁶ In this study deep isoflurane (>1.6 MAC) was used to keep the marmoset proper anesthetized continuously. This high MAC was necessary because endotracheal tubing of a marmoset was not achievable because of its extremely narrow trachea, so a facemask was placed over its head. But the facemask did not fit exactly around the head of the marmoset, so a certain amount of gas was wasted. Because of this, high levels of isoflurane were administered through the facemask in order to make sure the marmoset stayed properly anesthetized.

However when used in recording SEPs, all volatile anesthetics produce a dose-dependent increase in SEP latency, an increase in central conduction time and a decrease in amplitude. Satisfactory monitoring of early cortical SEP waves, like the P1 complex within the 10-30ms latency range, is possible with 0.5-1 MAC isoflurane. When used in higher MAC, the amplitude of the early cortical waves decrease. Under deep isoflurane (>1.6 MAC) the amplitude can even decrease with 60-70%. Nevertheless it can still be recordable. Deep isoflurane may also

cause morphologic changes, such as contraction of early cortical waveforms into a simple monophasic wave. The later cortical waveforms, the bigger P2 and P3 complexes, are even more sensitive to volatile anesthetics, with marked attenuation at concentrations exceeding 0.5 MAC. Under deep isoflurane these waves diminish so much that they cannot be recorded anymore in 47% of cases.¹⁰ The latter can be an explanation why the later complexes did not appear in the decline of the stimulus artefact. Better choices of anesthetics when monitoring SEPs could be propofol, etomidate, clonidine or isoflurane below 1.0 MAC, or combinations of these drugs, as in man these drugs have a negligible decreasing or even an increasing effect on the SEP amplitudes.¹⁰

In M08018 no sign of stimulus artefact or SEP became discernable. The separate transmitter did record the given stimuli, which proves that the stimulator was working properly. Also the marmosets' transmitter and receiver were not to blame, because there was normal EEG activity recorded in the marmoset during these measurements. At necropsy no impairments in electrode placement was found. It is a fact that this marmoset died during recovery. Maybe it is possible that the animal was already brain-dead during the trial, subsequently the somatosensory processing failed the projection of the stimulation on the cortex? The actual reason is still unknown.

The method of EEG-recording by biotelemetry was suspected to be a great solution as it was in the sleep-EEG studies, as the highly active marmosets at the BPRC had disrupted the former used head-mounted receptacles from their skull multiple times in previous studies.²⁰ Although biotelemetry technology for monitoring laboratory animals has existed for some time, only in the last decade affordable, reliable, totally implantable and easy-to-use products have come available for biomedical research. This development led to a certain amount of Reduction and Refinement, thus following the principle of the three R's described by Russell and Burch.³⁸ Unlike in conventional measurements techniques, like tethering the animals or use of recorders worn in jackets, biotelemetry refines the study in means of elimination of stress related to the use of restraints when measuring in conscious animals. Kramer et al. reported a possible reduction in animal use because of the accurate, reliable and objective telemetric measurements and the multiple physiologic parameters that can be measured in one animal.⁵ In addition, the totally implantable telemetry systems have no external connectors or cables, which means that besides there is no possibility for destruction by the marmosets itself, there are no exit wounds and so the infection risk is greatly reduced.^{4, 5, 21, 29} It represents a humane means for monitoring of physiologic parameters in animals.⁵ Unfortunately in this study, despite all the advantages of this method, the used transmitters turned out to be unusable for the aim of this study.

Maybe in future studies technical development will exclude the technical limitations of the biotelemetry devices hence it can be an appropriate method for monitoring SEPs in marmosets. However, invasive surgery is needed for implantable biotelemetry devices or the conventional head-mounted receptacles as well. This disadvantage might be overcome by use of more non-invasive techniques for EEG monitoring. An example can be the development of 'mini electrocaps', which can be temporarily placed over the head of the small marmoset with minimal discomfort. In larger species, such as horses³⁷, dogs⁸ and macaques³⁰, it is already possible to record SEPs using non-invasive techniques like needle EEG electrodes fixated to the skin or, as used in human studies, with silver disc or cup electrodes on the skin.^{16,17} Development of non-invasive techniques for EEG monitoring can lead to refinement in future EEG studies.

Conclusion

The aim of this pilot study was to investigate whether the used implantable telemetry devices can monitor SEPs in common marmosets. Unfortunately, creating SEPs in the first two marmosets was not accomplished. This study proves that the current biotelemetric devices are not appropriate for monitoring SEPs (yet) because of technical limitations. Perhaps in the future, with new, innovative designed biotelemetric devices, the use of biotelemetry for monitoring SEPs can be profitable. But for now, these biotelemetry devices are not suitable for this purpose.

Acknowledgements

I wish to thank the BPRC and its staff for doing my research project at their great facility and for all the instructive veterinary opportunities you offered me during my internship. I would like to thank Jaco Bakker and Rianne Klomp from the BPRC, for their supervision and guidance in this study. From the Faculty of Veterinary Medicine Utrecht I would like to thank Saskia Arndt and Manon Schaap for their feedback and useful advice during my research project. Finally, my special thank is extended to Arie Doornenbal for his great help during this entire study.

References

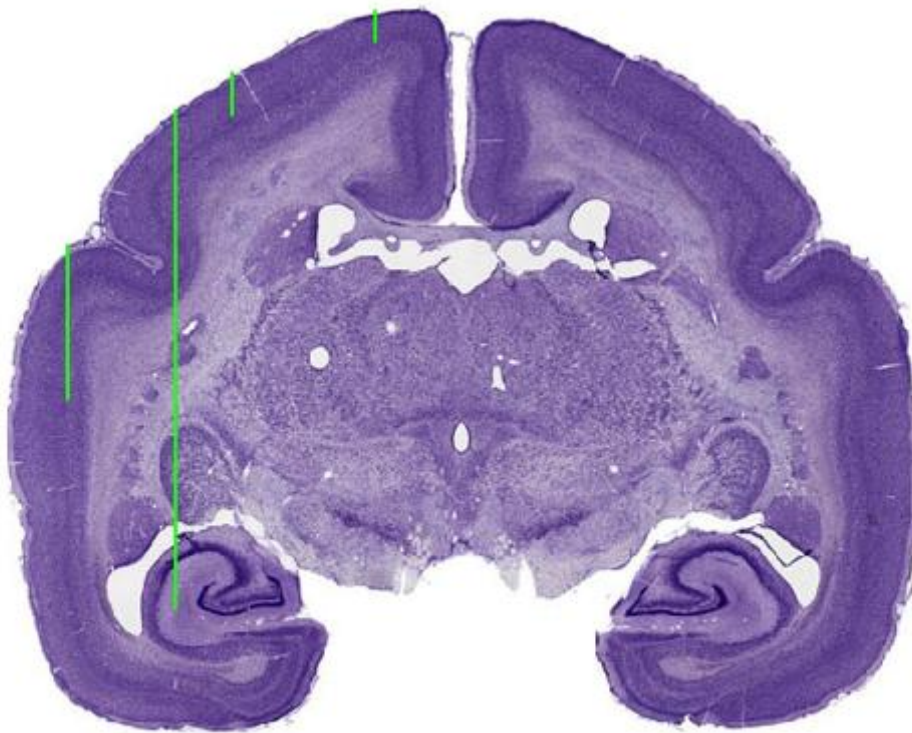
1. Stienen PJ. Development of a rat model to assess analgesic efficacy using somatosensory-evoked potentials. PhD-thesis, Faculty of Veterinary Medicine, Utrecht University, Utrecht, The Netherlands, 2005.
2. Van Oostrom H, An attempt to assess animal pain using brain activity. PhD-thesis, Faculty of Veterinary Medicine, Utrecht University, Utrecht, The Netherlands, 2007.
3. Merskey H, Bogduk N; Part III: Pain Terms, A Current List with Definitions and Notes on Usage. Classification of Chronic Pain, Second Edition, pp 209-214, 1994, IASP Task Force on Taxonomy, Seattle.
4. Güler NF, Übeyli ED; Theory and Applications of Biotelemetry. *Journal of Medical Systems* 2002; 26-2.
5. Kramer K, Kinter L, Brockway B, Voss H, Remie R, Van Zuthpen B. The Use of Radiotelemetry in Small Laboratory Animals: Recent Advances. *Contemporary Topics, The American Association for Laboratory Animal Science*; 2001; 40(1).
6. Jeutter DC; Biomedical telemetry techniques. *Crit Rev Biomed Eng.* 1982; 7(2): 121-74.
7. Schaap MWH, van Oostrom H, Doornenbal A, Baars AM, Arndt SS; Predictability of Painful Stimulation Modulates the Somatosensory-Evoked Potential in the Rat. *PLoS ONE* 2013, 8(4): e61487.
8. Van Oostrom H, Stienen PJ, Doornenbal A, et al.; Nociception-related somatosensory evoked potentials in awake dogs recorded after intra epidermal electrical stimulation. *Eur J Pain* 2009; 13: 154-60.
9. Stienen PJ, van Oostrom H, van den Bos R, de Groot HNM, Hellebrekers LJ.; Vertex-recorded, rather than primary somatosensory cortex-recorded, somatosensory-evoked potentials signal unpleasantness of noxious stimuli in the rat. *Brain Res Bull* 2006; 70(3): 203–12.
10. Banoub M, Tetzlaff JE, Schubert A; Pharmacologic and physiologic influences affecting sensory evoked potentials. *Anesthesiology* 2003; 99: 716-737.
11. Haberham ZL, van den Brom WE et al.; EEG evaluation of reflex testing as assessment of depth of pentobarbital anesthesia in the rat. *Laboratory Animals* 1999; 33: 47-57.
12. Van Oostrom H, Doornenbal A, Schot A, Stienen PJ, Hellebrekers LJ. Neurophysiological assessment of the sedative and analgesic effects of a constant rate infusion of dexmedetomidine in the dog. *Vet J.* 2011; 190(3): 338-44.
13. Franken ND, van Oostrom H, Stienen PJ, Doornenbal A, Hellebrekers LJ. Evaluation of analgesic and sedative effects of continuous infusion of dexmedetomidine by measuring somatosensory- and auditory-evoked potentials in the rat. *Vet Anaesth Analg.* 2008; 35(5): 424-31.
14. Stienen PJ, de Groot HNM, Venker-van Haagen AJ, van den Brom WE, Hellebrekers LJ; Differences between somatosensory-evoked potentials recorded from the ventral posterolateral thalamic nucleus, primary somatosensory cortex and vertex in the rat. *Brain Res Bull* 2005; 67: 269-280.

15. Inui K, Kakigi R; Pain perception in humans: use of intraepidermal electrical stimulation. *J Neurol Neurosurg Psychiatry* 2012; 83: 551-556.
16. Jung K; Electrical low-frequency stimulation induces central neuroplastic changes of pain processing in man. *Eur J Pain* 2012; 16: 509–521.
17. Kaube H, Katsarava Z, Kaufer T, Diener H, Ellrich J.; A new method to increase nociception specificity of the human blink reflex. *Clin Neurophysiol* 2000; 111: 413–6.
18. Mouraux A, Iannetti GD, Plaghki L.; Low intensity intra-epidermal electrical stimulation can activate A δ -nociceptors selectively. *Pain* 2010; 150: 199-207.
19. Jagessar SA, Heijmans N, Bauer J, Blezer ELA, Laman JD, Migone T, Devalaraja MN, 't Hart BA; Antibodies Against Human BLYS and APRIL Attenuate EAE Development in Marmoset Monkeys. *Journal of Neuroimmune Pharmacology*, 2012: 7(3).
20. Rijnbeek MWM; Optimizing EEG recording in common marmosets (*Callithrix jacchus*) in order to improve laboratory animal welfare (a pilot study). Research Project, Faculty of Veterinary Medicine, Utrecht University, Utrecht, The Netherlands, 2012.
21. Pearce PC, Crofts HS, Muggleton NG, Scott EAM; Concurrent Monitoring of EEG and Performance in the Common Marmoset: A Methodological Approach. *Physiology & Behavior* 1998; 63-4.
22. Weiergräber M, Henry M, Hescheler J, Smyth N, Schneider T; Electrographic and deep intracerebral EEG recording in mice using a telemetry system. *Brain Research Protocols* 2005; 14: 154-164.
23. Yuasa A, Nakamura K, Kohsaka S; Stereotaxic atlas of the marmoset brain with immunohistochemical architecture and MR images. *National Institute of Neuroscience* 2010; National Center of Neurology and Psychiatry, Japan.
24. Verhave P, Jongsma M, Van den Berg R, Vis J, Vanwersch R, Smit A, Van Someren E, Philippens I; REM Sleep Behavior Disorder in the Marmoset MPTP Model of Early Parkinson Disease. *Sleep* 2011; 34(8): 1119–1125.
25. Cosgrove RG, Cole JMD; Surgical treatment of epilepsy. Departments of Neurology and Neurosurgery, Massachusetts General Hospital Epilepsy Center, Harvard Medical School, Boston, Massachusetts
26. Mizuhiki T, Inaba K, Setogawa T, Todab K, Ozaki S, Shidara M. The influence of passband limitation on the waveform of extracellular action potential. *Neuroscience Research* 2012; 72: 214–220
27. Delgado J; Permanent implantation of multilead electrodes in the brain. *Yale Journal of Biology and Medicine* 1952; 351-358.
28. Bekoff M; Aquatic animals, cognitive ethology, and ethics: questions about sentience and other troubling issues that lurk in turbid water. *Dis Aquat Organ*. 2007; 75(2): 87 - 98.
29. Crofts HS, Wilson S, Muggleton NG, Nutt DJ, Scott EAM, Pearce PC; Investigation of the sleep electrocorticogram of the common marmoset (*Callithrix jacchus*) using radiotelemetry. *Clin. Neurophysiol*. 2001; 112: 2265-2273.

30. Beydoun A, Morrow TJ, Shen JF, Casey KL; Variability of laser-evoked potentials: attention, arousal and lateralized differences. *Electroencephalogr Clin Neurophysiol* 1993; 88: 173-181.
31. Goldberg AM, Zurlo J, Rudacille D; The Three Rs and Biomedical Research; *Science* 1996; 272: 5267 - 1403
32. Jones SJ, Edgar MA, Ransford AO. Sensory nerve conduction in the human spinal cord: epidural recordings made during scoliosis surgery. *Journal of Neurology, Neurosurgery, and Psychiatry* 1982; 45: 446-451.
33. Bromm B, Lorenz J; Neurophysiological evaluation of pain. *Electroencephalogr Clin Neurophysiol.* 1998; 107(4): 227-53.
34. Stienen PJ, Haberham ZL, van den Brom WE, de Groot HNM, Venker-van Haagen AJ, Hellebrekers LJ; Evaluation of methods for eliciting somatosensory-evoked potentials in the awake, freely moving rat. *J Neurosci Methods* 2003; 126: 79-90.
35. Stienen PJ, van den Brom WE, de Groot HNM, Venker-van Haagen AJ, Hellebrekers LJ; Differences between primary somatosensory cortex- and vertex-derived somatosensory-evoked potentials in the rat, *Brain Res* 2004; 1030: 256-266.
36. Petersen-Felix, S; Depth of anaesthesia. *Veterinary Anaesthesia and Analgesia* 1998; 25: 1467-2995.
37. van Loon JP, Stienen PJ, Doornenbal A, Hellebrekers LJ. Use of epidurally derived evoked potentials for quantification of caudal nociception in ponies. *Am J Vet Res.* 2009; 70(7): 813-9.
38. Russell WMS, Burch RL; The principles of humane experimental technique. London, Methuen. 1959.

Appendix

Optimizing the method of intracerebral injection of the marmoset brain with appropriate anesthesia



Research Project, Faculty of Veterinary Medicine, Utrecht University

Student: M.M. Hölscher

Studentnumber: 3259153

Supervisors:

Biomedical Primate Research Centre, Rijswijk: Drs. M. Keehnen

Utrecht University: Dr. S.S. Arndt

Department of Animals in Science & Society

Division of Animal Welfare & Laboratory Animal Science

Faculty of Veterinary Medicine, Utrecht University

April - June 2013

Abstract

Alzheimer's Disease (AD) is the most common form of dementia in the elderly with no cure or preventive therapy yet available. Studying this formidable disease at the BPRC in marmosets will provide potential benefit for AD patients. Injecting exogenous β -amyloid protein into the cerebrum of marmosets may experimentally induce cerebral β -amyloidosis, consequently causing AD. The method of stereotactically injecting fluids into the marmoset brain with a suitable anesthesia is a new method at the BPRC. In this study this accurate technique is practiced in three marmosets. Constant rate infusion (CRI) in the marmoset's tail base with diluted alfaxalone appeared to deliver the most appropriate anesthesia. Intracerebral injection of Evans Blue succeeded, but microtomy of the brain revealed that the brain coordinates must be better adjusted to the location of interest. By adjusting the coordinates and again practicing this procedure, this method can be used for intracerebral injection of β -amyloid in AD research at the BPRC.

Contents

	Page
Abstract	26
Contents	27
Introduction	28
Materials and methods	
<i>Animals</i>	30
<i>Anesthesia</i>	30
<i>Intracerebral injection</i>	33
Results and conclusion	35
Acknowledgements	36
References	37

Introduction

With the increasing longevity of our human population, Alzheimer's Disease is approaching epidemic proportions with no cure or preventive therapy yet available. It is the most common form of dementia in the elderly.¹ Clearly, studying this formidable disease will provide potential benefit for AD patients.

A prominent diagnostic feature of the neuropathology of AD is the accumulation of deposits of fibrillar protein within parenchymal plaques (fig.1) and the cerebral vasculature (fig 2). This protein is a ~4-kiloDalton protein fragment: β -amyloid. Injecting exogenous β -amyloid protein into the cerebrum will experimentally induce cerebral β -amyloidosis, consequently causing AD.^{1,2,3,4}

When we consider animal models for nervous and mental disease in particular, rodents are not the ideal animals for these models, because of the huge differences in structures and functions of nervous system between rodents and humans. Common marmosets (*Callithrix jacchus*) have become an increasing focus of attention of biomedical researchers because of their high reproductive rate as well as the biosafety, ease of handling and low cost for breeding of the animals. In addition the availability of a modern atlas of the brain of the marmoset, these small non-human primates are increasingly used for studying AD.^{3,5}

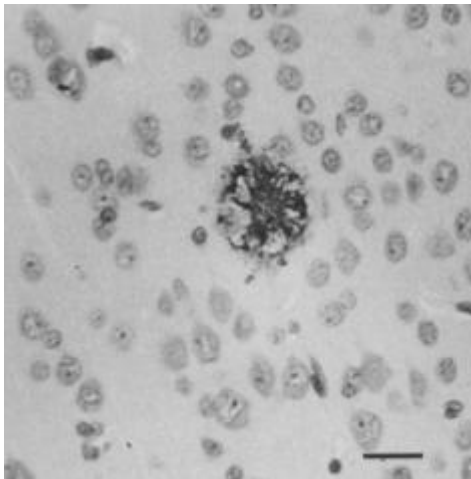


Fig. 1. Neuritic plaque in the cerebral cortex of a marmoset injected with brain material from a human AD patient. Bar=25 μ m. Baker et al. '94

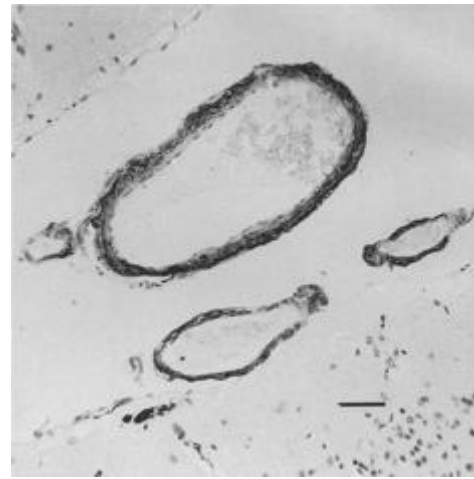


Fig. 2. B-protein positive meningeal bloodvessel in a marmoset injected with brain material from a human AD patient. Bar=60 μ m. Baker et al. '94

Hence the Biomedical Primate Research Centre (BPRC) is the biggest primate research centre in Europe, the development of using their marmosets for AD research was obvious. The use of a stereotact in marmosets was a new technique for the biomedical researchers and veterinarians at the BPRC. Even the appropriate choice of drug and method for anesthesia during this procedure was a challenge. The aim of this pilot study was to master, investigate and develop the method of stereotactically injecting fluids into the marmoset brain with a suitable anesthesia. Subsequently this method can be used for intracerebral injection of β -amyloid in AD research at the BPRC. In this paper the developments and findings in the procedures of this study will be discussed.

Materials and methods

Animals

Five female adult common marmosets (*Callithrix jacchus*) born and raised at the BPRC were included in this study. Their age was between 3-4 years with a bodyweight between 300-400 gram. Four marmosets were formerly used for a telemetry-EEG study that had been timely stopped and another marmoset was not usable for other studies at the BPRC any more. Housing conditions were in compliance with the directive 2010/63EU. Animal care provided besides food and water ad libitum also optimization of the cage environment such as wooden poles and plastic tableaus and trays to sleep in. Animal food was removed 16 hours prior to sedation. Water intake was never restricted. During the study, a veterinarian was present in order to monitor health and welfare of the animals.

Anesthesia

Choice of drug

Usually the chosen drug for sedating or premedicating marmosets at the BPRC is alfaxalone (Alfaxan, 10mg/ml, Vetoquinol B.V. 's Hertogenbosch, The Netherlands). However when this drug is injected intramuscular, the marmosets invariably start sneezing during their sedation/anesthesia. The reason for this is unknown. Nevertheless this would be an undesirable feature when the marmoset is positioned in the stereotact, because this movement could cause possible trauma to the ear or tympanic membrane, or even to the brain tissue when the needle is penetrating the brain. Besides that, movement of the head during injection of fluids in the brain would be detrimental for the important precise positioning of the needle and the injection of its fluids in the brain.

Gaseous anesthesia by isoflurane was considered a possibility for this study. Endotracheal intubation was not an option because of the small diameter of the trachea in marmosets there are no tubes with cuffs that small available. Tubes without cuffs will lead to leakage of gases, which is undesirable. A facemask to cover the whole snout of the animal was not achievable due to the impossibility to connect the snout of the marmoset thoroughly with the facemask while the animal is positioned in the stereotact. The restraints obstruct the animal's mouth. As a result there would be a lack of adequate waste gas scavenging and a risk of rapid recovery of the animal.⁶ However a new product for inhalation anesthesia was considered an option: The v-gel® (Docsinnovent Ltd., London, UK). This supraglottic airway device (SGAD) is used for human, cats and rabbits anesthesia.^{7,8} The smallest v-gel

for rabbits was chosen to be possible (fig. 3) for the small marmosets to deliver the isoflurane anesthesia.

Intramuscular injections of ketamine (Ketamine, 100mg/ml, AST Farma BV, Oudewater, The Netherlands) were not considered appropriate for use in this study due to the short effective persistence (<1 hour) of this drug as single injection and the unpredictable and hardly controllable depth of anesthesia.^{6,9} Extra doses for maintenance need to be injected and the depth of anesthesia would be hard to predict or control, which was considered unfavorable.

CRI of alfaxalone was considered most suitable. When used as CRI, alfaxalone produces excellent induction of anesthesia, maintenance and recovery while keeping ideal hemodynamic values.⁹ Anesthetic depth changes slowly and predictably and can be deepened rapidly by intravenous bolus injections if necessary. It produces a safe, easily controlled surgical anesthesia suitable for procedures of long durations in marmosets.⁶

The CRI anesthesia and the inhalation anesthesia were tested in separate marmosets to evaluate the effect of each method of anesthesia.

Intravenous CRI anesthesia

The dosage of the alfaxalone CRI for the marmosets was administered as calculated in rats (by the Netherlands Institute for Neuroscience, Amsterdam, The Netherlands): 0.15 mg/kg/min, which gives a flowrate of 0.015 ml/kg/min. For a marmoset of approximately 0.3 kg the flowrate of the alfaxalone CRI became 0.3 ml/h.

To allow induction by intravenous alfaxalone infusion, the marmoset was first premedicated by a single intramuscular injection ketamine (30 mg/kg) and alfaxalone (6 mg/kg). Then the tail base was shaved carefully and warmed for approximately two minutes by placing a latex glove filled with hand-hot water around the tail base. The lateral tail vein was cannulated using an intravenous over-the-needle 24G catheter (Vasofix Braunule, B. Braun® Medical, Oss, The Netherlands), which was then securely fixated to the tail by leukotape. It became clear that it is extremely beneficial to warm up the tail of the marmoset for the veins to become dilated and hence more visible so the catheter can be placed more easily. An infusion pump (Medima S2, Medima Ltd., Warsaw, Poland) with a 10ml syringe was used to infuse the Alfaxan dilution.

Early on in the experiment, the infusion pump started to repeatedly denote an error of 'too high pressure' or 'occlusion': Probably the pump's pressure was too low to operate with this low flow rate. To diminish the pressure problem the tail of the marmoset was raised with use of some coasters placed

beneath it and also the pump was raised on its stand, so gravity might help to increase the pressure of the infusion into the vein.

Besides that, the warm water-filled latex glove was again placed around the tail base to keep the cannulated vein diluted continuously to diminish the resistance of the vein.

In addition, the pumps' malfunctioning would probably be solved when a smaller syringe was used. When the plunger of the syringe moves more in its barrel per time unit, the pump could operate easier and also more accurate.

Moreover the dilution of the alfaxalone was adjusted with use of 0.9% NaCl to increase the flowrate, whereby the pressure of the infusion into the vein was expected to become higher. The maintenance infusion (in ml per hour) for a marmoset was compared with that of a dog and a cat, which is respectively calculated by $132\text{ml} \times \text{kg}^{0.75}/24\text{h}$ and $80\text{ml} \times \text{kg}^{0.75}/24\text{h}$.¹⁰ For a marmoset with a weight of approximately 0.3kg these calculations result in respectively 2.3 and 1.4 ml/h. A flowrate between these two rates was maintained. To achieve this, a dilution of 1.25 mg/ml alfaxalone was made with 0.9% NaCl. With an alfaxalone CRI dose of 0.15 mg/kg/min the flow became 0.12 ml/kg/min, which results in a flowrate of 2.4 ml/h for a marmoset.

Later on in the experiment, by using the smallest syringe the pump could manage (5ml syringe), the higher positioning of the tail and pump, the heating of the tail base and the apply of the higher flowrate, the error of the infusion pump consequently abated. Maybe for future studies, a new infusion pump that can adequately manage these low flow rates can be procured.

Inhalation anesthesia

After lubricating the v-gel it was inserted into the marmoset's pharynx. Connection to a capnograph showed that the marmoset could not breathe when the v-gel was completely inserted. After approximately 1 cm withdrawal of the v-gel, a nice respiratory pattern became visible in the animal and on the capnograph. This demonstrated that the rabbit mouthpiece of the v-gel was actually too long for the marmoset's anatomy. After appropriate positioning of the v-gel isoflurane in 0.2 and later on 0.5 minimum alveolar concentration (MAC) was administered. No leakage of gas was smelled and the marmoset remained in a stable anesthesia for approximately two hours.

However, miniscule movement of the marmoset during the anesthesia displaced the v-gel from the trachea which inhibited breathing hence hindered the respiratory pattern on the capnograph. Also positioning the marmoset into the stereotact while keeping the v-gel in place was challenging. During fixation of the marmoset in the stereotact the v-gel displaced and the tubes of the anesthesia device did not easily fit through the openings of the stereotact

without excessively stretching the marmoset's mouth. Accordingly, this method was considered inappropriate for use in a marmoset in a stereotact. Innovation and development of a smaller SGAD or adjustment of the v-gel's proportion is necessary before this new method could be considered a valuable option in anesthetizing a marmoset.




Fig. 3. **A.** The v-gel for rabbits. **B.** V-gel relative to the rabbit's upper airway anatomy. (Docsinnovent® - Tech sheet, 2012.) **C.** Anesthetized marmoset breathing through v-gel.

Intracerebral injection

Coordinates were determined earlier by use of the brain atlas of the marmoset.^{5,11} In the left and right hemisphere the temporal cortex (5.0 mm cranial to bregma, 9.5 mm left and right from midline, 8.0 mm ventral from the brain/dura mater surface), the prefrontal cortex (0.1 mm cranial to bregma, 5.5 mm left and right from midline, 15 mm ventral from the brain/dura mater surface) and the superior parietal cortex (6.0 mm caudal to bregma, 2.0 mm left and right from midline, 18 mm ventral from the brain/dura mater surface) were the used stereotaxic locations.

An expert in intracerebral injections in rodents (Hamelink R., Sr. Research Technician, Netherlands Institute for Neuroscience, Amsterdam, The Netherlands) visited the BPRC early in the study for instruction and guidance during these accurate procedures. His instructions were followed for the rest of the following procedure.

An Evans Blue dye¹² was used in this study to inject into the brain tissue in order to verify after dissection if the injections by these coordinates resulted in blue staining in the brain tissue of interest.

The infusion pump with a 10 µl Hamilton syringe (Hamilton Company, Europe) was prepared with the Evans Blue and set at the correct infusion volume (4 µl) and infusion rate (0.2 µl/min).

After anesthetizing the marmoset by premedication and CRI as previously described, its head was carefully shaved and washed before proper fixating the animal into the stereotact. The top surface of the skull was positioned horizontally so the coordinates from the brain atlas were correctly located in the marmoset's brain. A craniocaudal skin incision over the head was made and the skin was bluntly dissected in mediolateral direction. A local Xylocaine spray (Lidocaine 100 mg/ml, AstraZenica, Zoetermeer, The Netherlands) was administered before erasing the sensitive periosteum by using a cotton swab. The bregma in the skull became visible and the coordinates were determined using the stereotact in order to drill the six holes in the skull using a circular dental drill. After drilling, the dura overlying the brain was punctured using a loose 27G injection needle, as the injection needle of the stereotact was too blunt to penetrate the dura. By again using the stereotact's coordinates the injection needle was accurately positioned above a drilled hole, just above the brain surface. The needle was slowly injected into the brain tissue whereupon the injection pump was activated in order to inject the 4 µl fluid over 10 minutes time. When the total volume is injected there was a five-minute waiting period before slowly withdrawing the needle thus the fluid can properly diffuse into the brain tissue. Otherwise the withdrawal of the needle would extract the fluids up along its needle track. The injection procedure was repeated for each hole.

After the intracerebral injections the marmosets were euthanized by an overdose pentobarbital (Euthasol 200 mg/ml, AST Farma, Oudewater, The Netherlands) intravenously or intracardially. At necropsy the brain was removed and frozen in liquid nitrogen (-196 °C) in order to cut slices off by cryostat microtomy.

Results and conclusion

Anesthesia

CRI of diluted alfaxalone in 0.15 mg/kg/min in the tailbase of the marmoset resulted in a stable anesthesia period of approximately 3 hours. This method seems the most appropriate for anesthetizing a marmoset fixated in a stereotact for a long period.

Intracerebral injection

By macroscopic evaluation of the cross-cuts of the brain while slices were cut off by the cryostat, the blue colorant spots in the brain tissue became clearly visible (fig. 4). Pictures were taken of almost every slice in order to check if every blue staining was injected in the right brain area. This revealed that some of the injected fluid was not located in the intentional brain tissue of interest. Assuming the method of intracerebral injection was correctly performed following the expert's instructions, the stereotaxic coordinates must have been incorrect.

From an ethical perspective, deliberation about and adjustment of these brain coordinates must take place before continuing this study and testing this method in more marmosets.



Fig. 4. *Cross-cut of the marmoset brain by cryostat microtomy. The blue colorant injections became visible to check if the injections were in the intentional brain locations.*

Acknowledgements

I would like to thank the BPRC and its staff, especially Jan Langermans, Jaco Bakker and Rianne Klomp for giving me the opportunity to fulfill my internship at the BPRC by doing this second pilot study. Special thanks in this second study are extended to Merei Keehnen for supervision and guidance during this research and for all the educational veterinary opportunities that were offered to me during my internship at the BPRC.

References:

1. Tanzi RE, Bertram L; Twenty Years of the Alzheimer's Disease Amyloid Hypothesis: A Genetic Perspective. *Cell* 2005; 120: 545–555.
2. Baker HF, Ridley RM, Duchon LW, Crow TJ, Bruton CJ; Evidence for the experimental transmission of cerebral β -amyloidosis to primates. *Int. J. Exp. Path.* 1993; 74: 441-454.
3. Baker HF, Ridley RM, Duchon LW, Crow TJ, Bruton CJ; Induction of β (A4)-Amyloid in Primates by Injection of Alzheimer's Disease Brain Homogenate: Comparison with Transmission of Spongiform Encephalopathy. *Molecular Neurobiology* 1994; 8(1): 25-39.
4. Maclean CJ, Baker HF, Ridley RM, Mori H; Naturally occurring and experimentally induced β -amyloid deposits in the brains of marmosets (*Callithrix jacchus*). *J Neural Transm.* 2000; 107: 799-814.
5. Yuasa A, Nakamura K, Kohsaka S; Stereotaxic atlas of the marmoset brain with immunohistochemical architecture and MR images. *National Institute of Neuroscience* 2010; National Center of Neurology and Psychiatry, Japan.
6. Whelan G, James MF, Samson NA, Wood NI; Anaesthesia of the common marmoset (*Callithrix jacchus*) using continuous intravenous infusion of alphaxalone/alphadalone. *Laboratory Animals Ltd. Laboratory Animals* 1999; 33: 24-29.
7. van Oostrom H, Krauss, MW, Sap R; A comparison between the v-gel supraglottic airway device and the cuffed endotracheal tube for airway management in spontaneously breathing cats during isoflurane anaesthesia. *Veterinary Anaesthesia and Analgesia* 2013; 40: 265–271.
8. Crotaz IR; Initial feasibility investigation of the v-gel airway: an anatomically designed supraglottic airway device for use in companion animal veterinary anaesthesia. *Veterinary Anaesthesia and Analgesia* 2010; 37: 579–580.
9. Ambros B, Duke-Novakovski T, Pasloske KS; Comparison of the anesthetic efficacy and cardiopulmonary effects of continuous rate infusions of alfaxalone-2-hydroxypropyl-beta-cyclodextrin and propofol in dogs. *Am J Vet Res.* 2008; 69(11): 1391-8.
10. Dibartola SP; Fluid, Electrolyte And Acid-base Disorders in Small Animal Practice, 3rd Edition, 2005, WB Saunders.
11. Hikishima K; Population-averaged standard template brain atlas for the common marmoset (*Callithrix jacchus*). *NeuroImage.* 2011; (54) 2741–2749.
12. Hed J, Dahlgren C, Rundquist I; A Simple Fluorescence Technique to Stain the Plasma Membrane of Human Neutrophils. *Histochemistry* 1983; 79 (1): 105–10.