

2012

Utrecht University
Faculty of Veterinary
Medicine

Authors:
J.Y. Brunsting, Bsc.
M. Pluim, Bsc.

Supervisor:
Drs. S.M. Cokelaere,
DVM

[DEVELOPMENT OF A STANDARDIZED SURGICAL (OSTEO-)CHONDRAL DEFECT MODEL IN THE EQUINE STIFLE]

[Surgical techniques for cartilage repair in an equine model]

Summary

Osteoarthritis is an important factor for lameness in horses. This degenerative joint disease is characterized by breakdown of articular cartilage. Therefore a significant amount of research on cartilage repair is currently undertaken (Harmel, 2004). Hyaline cartilage consists of chondrocytes, proteoglycans, collagen and water (Weeren van, 2010). Where proteoglycan can be replaced, collagen can be created, however the body is unable to recreate the arching configuration of collagen that anchors hyaline cartilage to the subchondral bone. This configuration is required for cartilage to perform as unique mechanical properties (Bramlage, 2009). Different osteochondral scaffolds are developed for cartilage defect repair. These different scaffolds aim to repair tissue that is superior to fibro-cartilage, which is formed after the natural cartilage repair process (Bramlage, 2009). These scaffolds for human use are currently being tested in animal models. The equine stifle model seems to most closely approximate the human knee cartilage wise (McIlwraith, 2011). Nevertheless, there is no universal model for (osteo-)chondral defect surgery for cartilage repair in the equine stifle. Therefore, a cadaveric study is performed with the aim to optimize this surgical procedure. Both mini-arthrotomy and arthroscopy can be used for (osteo-)chondral scaffold implantation. In this study the advantages and disadvantages of both techniques have been investigated. Arthroscopy, while using gas as a distention medium is preferred because it is minimally invasive, although this technique is more challenging than mini-arthrotomy. Defects of at least 9 mm in diameter and 9 mm in depth (which is the critical size) are created on both the lateral and medial trochlear ridge and the medial condyle by using a drill bit inserted through a surgical sleeve. Different composite scaffolds can be inserted and secured through this same sleeve. Post-operative management includes antibiotics and NSAID's and a rehabilitation protocol.

Contents

1. Introduction	4
1.1 Hyaline cartilage.....	4
1.2 Scaffolds.....	5
1.3 Animal Model.....	6
1.4 Research setup.....	7
2. Open surgical procedure: Mini-Arthrotomy	8
2.1 Arthrotomy of the femoropatellar joint	8
2.2 Arthrotomy of the femorotibial joint	8
2.3 Wound closure.....	9
3. Minimally invasive surgical procedure: Arthroscopy.....	9
3.1 Surgical approach for femoropatellar joint.....	9
3.2 Fluid versus gas distention	10
3.3 Wound closure.....	11
4. Defect creation and scaffold implantation.....	11
4.1 Material.....	11
4.2 Cartilage thickness.....	13
4.3 Defect size	15
4.4 Defect location.....	15
4.5 Defect creation and scaffold implantation.....	16
5. Post-operative management	18
5.1 Complications: per- and postoperative complications.....	18
5.2 Post-operative medication	19
5.3 Rehabilitation	19
6. Conclusion	21
7. References	22

1. Introduction

Recently there has been much interest in research for the treatment of cartilage defects. For 250 years people have been trying to heal articular cartilage with only mild therapeutic improvements (Harmel, 2004). The reason for this is the highly specialized nature of articular cartilage and the need of an intact structure to accomplish its biochemical and physiological functions. Cartilage repair has two distinct goals: restoration of joint function and prevention or delay of onset of osteoarthritis (McIlwraith, 2008). Osteoarthritis is one of the most common diseases in horses (Goodrich, 2006). It is not just a degenerative disease of the joints, but is characterized by a dynamic imbalance between the breakdown and healing of the cartilage. The joint is inflamed and painful with limited mobility which eventually leads to lameness. Osteoarthritis is treated with a variety of non-surgical methods. The aim is to remove the symptoms of osteoarthritis rather than the actual cause of the disease. The effect of these non-surgical therapies is transient, and repeated treatments are necessary (Harmel, 2004). Several drugs have been evaluated, including NSAID's, corticosteroids, hyaluronic acid, PRP, IRAP and stem cells (Goodrich, 2006). Treatment protocols only prevent further degradation but cannot reverse the damage to the surface of the articular cartilage. Hence, further research in the field of surgical cartilage repair is required as the aim of surgical treatment is to replace damaged cartilage.

1.1 Hyaline cartilage

Healthy articular cartilage, subchondral bone and synovial membranes along with an intact joint capsule are required for a fully functioning joint. Damage to these components can contribute to joint disease (Weeren van, 2010). However, the state of hyaline cartilage often defines the functional state of a joint. The rate of progression of joint disease and therefore the prognosis is reflected in the gross appearance of the hyaline cartilage and stage of degeneration which is compounded due to its slow rate of healing.

Healthy articular cartilage is smooth and glasslike on gross appearance, which is why it is called hyaline cartilage. The thickness of articular cartilage depends on numerous factors such as age, which joint, location within the joint and is related to the degree of weight bearing and compressive forces an area of cartilage is subjected to (Auer 2006, Goodrich 2006).

Cartilage depends on the surrounding synovial membrane and the synovial fluid for nutrition as cartilage lacks a vascular, lymphatic and neural supply. Nutritional solutes diffuse from the synovial membrane, through the articular matrix cartilage into the chondrocytes (Auer, 2006).

Articular cartilage consists of multiple layers: Calcified zone, deep, intermediate and superficial layers, covering the subchondral bone. Each layer has its own distinct composition, depending on its function. The superficial zone has the highest density of chondrocytes, these chondrocytes are orientated parallel to the joint surface in a flattened shape. Towards the intermediate zone, chondrocytes are larger and more round shaped. In the deep layer the largest chondrocytes are apparent. These are oriented perpendicular to the joint surface. Mineralized cells between matrix are found in the calcified zone. This calcified zone on the surface of the bone anchors the collagen arches of the cartilage. The

junction of the non-calcified and calcified cartilage is called the tidemark, which can be seen on histologic sections (Auer, 2006).

Chondrocytes are sparse, only accounting for 1-2% of the total volume of cartilage, with the extracellular matrix composing the remaining volume. The three main compounds of this extracellular matrix are: proteoglycans, collagen and water (Weeren van, 2010). Water accounts for 70% of the total volume of hyaline cartilage. The dry contents are 50% collagen, 35% proteoglycans, 10% glycoproteins, 3% minerals, 1% lipids, 1% miscellaneous substances (Auer, 2006). The chondrocyte population regenerates slow and up to a certain extent and therefore cartilage is only able to regenerate if the cartilage damage is minimal (McIlwraith, 1996).

Hyaline cartilage consists of collagen arches. These arches cross the calcified zone prior to attachment into the subchondral bone. Orientation in this deep layer is perpendicular to the joint surface, where near to the joint surface these arches bend and are orientated in a parallel way (Auer, 2006). The body is unable to recreate the configuration of these collagen arches. This architecture is required for a proper function of hyaline cartilage. When joint disease occurs and hyaline cartilage is degenerating, fibro-cartilage replaces hyaline cartilage. Fibro-cartilage although containing proteoglycans and collagen, is lacking the architecture of collagen arches that anchors it to the bone, and is therefore not as functional as hyaline cartilage. As resistance to joint loading is dependent on these collagen arches, fibro-cartilage is poorly anchored to the underlying subchondral bone, therefore it does not resist heavy loading and shear as effectively (Bramlage, 2009).

In a healthy joint there is a balance between the production and destruction of chondrocytes and proteoglycans, but in a state of inflammatory response this production can be slowed or destruction accelerated. The proteoglycan population has more regenerative capacity compared to the chondrocyte population (Bramlage, 2009). Proteoglycans protect the collagen due to its lubricating function. When proteoglycan becomes depleted in a diseased joint, collagen becomes exposed and vulnerable. Loss of proteoglycans associated with excessive joint use can result in significant damage to the articular surfaces of a joint. It is possible to stimulate proteoglycan production by medical treatment although neither medical or surgical treatments have shown the ability to replace collagen in the architecture that is present in hyaline cartilage (Bramlage, 2009). Therefore, surgical techniques such as joint lavage, microfracture and osteo-chondral scaffold implantation procedures are being used. (Osteo-)chondral scaffold implantation is based on aiming to restore the joint function by replacing articular cartilage (McIlwraith, 2008).

1.2 Scaffolds

Scaffolds can be used to fill into a (osteo-)chondral defect to try to improve cartilage repair. These scaffolds vary from cell-free to one or more cell types. They can consist of single-component or composites with various compositions and biomechanical properties. The variety of scaffolds available reflects the many specific requirements needed to replace hyaline cartilage. The four main categories of (osteo-)chondral scaffolds are: a single homogeneous scaffold (e.g. homogeneous PCL-scaffold or poly-ethylene fiber scaffold with HA), a single but heterogeneous composite scaffold (e.g. PLGA or PLA scaffold), different scaffolds for the bone and cartilage components combined at the time of implantation (e.g. collagen-hydroxyapatite sponge or natural or synthetic calcium

carbonate), and a scaffold for the bone but a scaffold free approach for the cartilage component (e.g. cell-free PLA or collagen HA) (Martin, 2006). These scaffolds can be loaded with a cell type with chondrogenic capacity, loaded with two cell types containing either chondrogenic or osteogenic capacities, loaded with one cell type with both chondrogenic and osteogenic differentiation capacity or using a cell-free approach. These different features can be combined and therefore various scaffolds can be created. Nowadays there are scaffold wise about 16 different strategies available for human cartilage repair (Martin, 2006). Also, in equine medicine many different osteochondral scaffolds have been tested. Different compositions require different implantation techniques. Implantation techniques are outlined in paragraph 4.5.

1.3 Animal model

Cartilage studies often use animal models to create a greater understanding of the nature and healing abilities of articular cartilage. Commonly used are: mice, rabbits, pigs, dogs, goats and horse models. Each model has advantages and disadvantages. Smaller animals are cost efficient and easy to house, but their small joint size and thin cartilage does not simulate a human joint properly. Goats, dogs, and pigs have larger joints, but the cartilage thickness is still significantly thinner than in the human. Only the equine model meets the requirements for joint size and cartilage thickness to draw a comparison to the human situation. However, horses are financially and logistically less efficient because their needs for housing and caretaking requires more materials and skill (Chu, 2010). Cartilage repair techniques in horses are well understood due to the clinical need for cartilage repair in these athletic animals. Equine model studies are also of social importance because there are considerable similarities between horse and human articular cartilage of the knee and the carpus (both histologically and biochemically) and can therefore offer a relevant model for human medicine (Hurtig, 1988).

Earliest studies of cartilage repair in horses involved surgically created defects in the carpus (Hurtig, 1988), because the carpus often suffers with cartilage defects in race horses. The variety of healing and relative thinness of cartilage in this joint are a disadvantage (McIlwraith, 2011). Also, the lack of a dorsal cartilage rim is inappropriate for use as a model for human medicine. Although, if a defect is created in a more palmar location with complete cartilage rims, this model can still be useful.

Non-calcified cartilage thickness on different locations in the equine stifle vary from 2.0 mm on the medial femoral condyle, and between 1,5-2.0 mm on the trochlear ridges. Total thickness, including the 0,2 mm calcified layer, ranges from 1,8-2,2 mm, which is among all animal models the closest approximation to human articular cartilage thickness of 2,2-2,5 mm (Frisbie 2006).

Similar to human, articular cartilage in horses has very low capability for repair (Convery, 1972). Chondral and subchondral defects ranging from 15 mm to 20 mm can be created to study the repair process of cartilage (Convery, 1972). These defects can be created on non-weight-bearing or weight-bearing areas of the joint. The medial and lateral compartments of the equine stifle are primary weight-bearing, where the femoropatellar joint is considered non weight-bearing during stall rest and hand walking. (Ahern, 2009). A defect on the medial condyle of the equine joint simulates a lesion on the medial femoral condyle in humans (McIlwraith, 2011). Another important reason to prefer the equine stifle model

is the ability to perform arthroscopic assessment.

The tibiotarsal joint is smaller and has a thinner cartilage layer compared to the stifle, but this joint does also allow arthroscopic assessment. Therefore, the tibiotarsal joint may be also useful for cartilage regeneration studies. Because of its anatomic similarity to the human ankle.

1.4 Research setup

Surgical techniques for cartilage repair in horses are being developed and used in research projects (Frisbie, 2006). However, there is no universal protocol for creating standardized (osteo-)chondral defects. In this study the optimal surgical method to make both chondral and subchondral defects in the equine stifle and use of cartilage scaffolds was examined. To develop a standardized surgical (osteo-)chondral defect protocol, cadaveric studies need to be performed and optimized before in vivo studies are performed. Sixteen hindlimbs of adult warmblood horses were used to develop this protocol. Different techniques are performed to decide which one was the most optimal. The different steps of these techniques were thoroughly investigated.

The hindlimb is extended by pulling the limb upright with a pulley and tackle, to mimic the physiological position of a horse during stifle surgery. In this position the femoropatellar joint is extended and allows the best surgical approach due to the fact that the patella is positioned most proximally and the femoropatellar joint is good accessible. Initially, the optimal surgical approach for osteochondral defect creation is tested, for both mini-arthrotomy and arthroscopy. For mini-arthrotomy the optimal approach is made using an incision at four different locations, depending on the location of the defect: between middle and medial patellar ligament, between middle and lateral patellar ligament and over middle patellar ligament to approach the femoropatellar joint and to reach the femorotibial joint an incision is made distally between the middle and medial patellar ligament. For the femorotibial joint approach the limb should be in a 90 degrees flexed position. The minimal incision size is determined by positioning the limb at different angles, because the smaller the incision the lower the risk of wound complications (McIlwraith, 1987). Complications of this technique are investigated using scientific literature. For the arthroscopic approach of the femoropatellar joint a thorough investigation of the anatomy of the medial and lateral trochlea ridge needs to be done. The angles of the trochlear surface at different defect locations were determined to be able to create a perpendicular defect by arthroscopic view. To perform the arthroscopic procedure the femoropatellar joint needs to be distended. Both media, fluid and gas, were investigated and both the benefits and the complications were compared to the literature. Also wound closure for the arthroscopic approach was tested. To determine optimal size, depth and location of (osteo-)chondral defects literature was compared to the practical application. There are several studies performed relevant to critical size lesions (Frisbie, 2006), depth of the (osteo-)cartilage defect is depended on cartilage thickness and the scaffold used (Gleeson, 2012). By anatomical evaluation of both the medial and the lateral trochlear ridge the optimal defect location can be determined and compared to the literature. To create an (osteo-)chondral defect in an equine stifle the materials developed for human defect creation are not suitable. Because the subchondral bone is much denser in the equine stifle. Therefore, to create a standardized lesion appropriate material needs to be found and tested. Therefore,

different drills and drill bits are compared to the requirements and tested in cadaveric models. Also the scaffold implantation procedure needs to be standardized and optimized. Post-operative medication and rehabilitation are based on human and equine scientific literature.

2. Open Surgical procedure: mini-arthrotomy

2.1 Arthrotomy of the femoropatellar joint

The technique of the femoropatellar mini-arthrotomy can be used to remove osteochondral fragments as well to create (osteo-)chondral defects for scaffold implantation. The horse must be under general anesthesia and positioned in dorsal recumbency. The stifle area is clipped and aseptically prepared before surgery. There are three different locations for incisions, depending on the location of the created defect; a linear skin incision can be made over the middle patellar ligament, between the middle and medial patellar ligament, or between the middle and lateral patellar ligament. After the skin, superficial- and deep fascia are incised the underlying fat pad is exposed. This fat pad can be split using Mayo scissors, removing as little of the fat as possible to maintain the physiological organization and limit blood loss. Retractors are placed to open the wound maximally. Finally, the joint capsule can be opened. Positioning the limb in an extended or more flexed position displays different areas of the trochlear ridge. A 12-cm linear incision is described for this procedure (McIlwraith, 1987) but a smaller incision and use of flexion of the limb seems to be as efficient to display enough cartilage surface to create a defect. With a 4-cm incision there is not sufficient cartilage surface displayed to be able to judge the right orientation of the defect. With both a 6-cm and 8-cm incision there is sufficient display of the cartilage surface to determine the correct location for a defect. McIlwraith described a 5-cm mini-arthrotomy between the lateral and middle patellar ligaments for defect creation on the lateral trochlear ridge. Larger incisions are undesirable because they are more prone to postoperative wound complications. Compressive bandaging is difficult to achieve in the equine stifle because of its anatomy and location.

2.2 Arthrotomy of the femorotibial joint

The horse is under general anesthesia in dorsal recumbency. The stifle area is clipped and aseptically prepared before surgery. The limb has to be flexed in a 90 degree position to expose the medial condyle of the femorotibial joint. The femorotibial joint is approached by creating an incision between the medial and middle patellar ligament. A 5-cm vertical incision is created at the distal tibial tuberosity and extended to the distal part of the patella. When superficial and deep layers of the fascia are dissected the femoropatellar fat pad is visible. To visualize the femorotibial joint capsule the fat pad is partially removed. To determine the exact location of the medial femoral condyle the area can be palpated. A 2-cm incision is made in the joint capsule and the defect creation procedure can commence (McIlwraith, 1987).

When performing this (osteo-)chondral defect creation procedure the femoropatellar and femorotibial joint are the points of interest. In theory, it is possible to approach these two

joints through one incision while extending the incision between the medial and middle patellar ligament from the distal aspect of the patella to the distal part of the tibial tuberosity. This incision needs to be at least 12 cm long. Although, the longer the incision the higher the risk of wound complication after surgery and therefore creating one incision is not always preferred over creating 2 smaller incisions. Therefore, the best approach for osteochondral defect creation in both joint is to approach both joints individually through small incisions.

2.3 Wound closure

After completing the procedure the surgical wound is sutured in 3 or 4 layers. The initial layer is a single non-perforating interrupted suture in the joint capsule using a 2-0 absorbable synthetic suture (Vicryl®). The following layer is the deep fascia, this layer is closed with a 0 or 1-0 synthetic absorbable filament (Vicryl®) with simple interrupted sutures. The superficial fascia can be left open or sutured in the same way as the deep fascia (McIlwraith, 1987). The skin is closed with 2-0 non-absorbable sutures (Prolene®) using a far-far-near-near (or vertical mattress) or a far-near-near-far pattern. These tension relieving sutures are most commonly used because of the considerable risk that the wound will tear after simple interrupted suturing (Kirpensteijn, 2006). It is possible to place a stent bandage to cover the incision and sutures (McIlwraith, 1987). Sutures can be removed two weeks following surgery.

3. Minimally invasive surgical procedure: arthroscopy

3.1 Surgical approach for femoropatellar joint

The horse is under general anesthesia in dorsal recumbency with the leg in extension. If both legs are to be operated on, only one should be in extension whilst work is performed on the joint in question, the other leg should remain flexed to reduce the change of postoperative femoral nerve paresis or quadriceps myopathy. The surgical field is widely clipped and aseptically prepared for surgery. The stifle does not need any pre-distension with fluid or gas.

The arthroscope should enter the stifle through a skin portal located halfway between the distal aspect of the patella and the tibial crest. This portal can be made either between the middle and lateral patellar ligament or through the middle patellar ligament. Inserting the arthroscope through the middle patellar ligament gives a better fixation of the scope and is therefore preferred (McIlwraith, 2005). The portal is made through the skin, superficial fascia, deep fascia and into the femoropatellar fat pad, with an 8-mm stab incision.

Subsequently the sleeve and conical obturator are manipulated through the incision and angled 45 degrees to the skin in a proximal direction. The obturator and arthroscope are manipulated under the patella, if there is any resistance, the obturator is manipulated more laterally to avoid cartilage damage. The obturator is more easily to move laterally past the patella and over the lateral trochlear ridge because it is less prominent compared to the medial site. The obturator can now be removed and replaced by the arthroscope. The view becomes optimal after the light cable is attached and the joint is distended by gas or fluid (McIlwraith, 2005).

3.2 Fluid versus gas distention

The use of fluid as a distention medium is the golden standard for performing equine arthroscopy. Lactated Ringer's or Hartmann's solution has been recommended rather than saline by McIlwraith et al (2005). Although recent studies demonstrate that also Ringer's sterile solution wash out proteoglycans and ions from the cartilage surface (Luciani 2008). McIlwraith et al. (2005) confirmed there is a stress pattern of the chondrocytes and synoviocytes after irrigation with lactated Ringer's. These patterns return to normal after 48 hours and are totally physiological normal after one week (McIlwraith, 2005). Gas distention is less frequently used during equine arthroscopy. Different types of gas are applicable such as carbon dioxide, nitrous or helium gas (Wilke, 2007). Carbon dioxide (CO₂) is the most common used gas as a joint distention medium (McIlwraith 2005, Boening 2005).

The choice whether to use gas or fluid as the distension medium to perform an arthroscopy requires further review. There are advantages in the use of gas as the distension medium. Gas distension allows an improved intra-operative view by preventing the "red out" (intra-articular bleeding), "white out" (synovial protrusion) and the "aquarium effect" (intra-articular structures appear much larger and closer to the observer). "Red out" is of no significant relevance while using gas because the blood will end up in the deepest articulation point due to gravity. The "white out" effect due to synovial protrusion cannot occur because the synovial villi stay close to the synovial membrane and cause an increased joint space and visualization (Boening, 2005). With the use of gas there is no possibility for the fragments to free-float inside the joint, it does not disturb the synovial villi, it produces rapid distension, it gives a higher quality of image (because of less light absorption occurs in air than in fluid) and it gives good visibility and depth field. (Luciani 2008, Boening 2005). Gas distension is required when autologous and heterologous grafting of chondrocytes is performed.

Although, in human arthroscopy the use of fluids is preferred because of fatal complications caused by gas embolisms after using CO₂. (Gruenwald, 1990) The risk of gas embolisms in equine surgery is negligible, so the use of CO₂ as gas distension can be applied (Boening, 2005). The other described disadvantages when using gas are the emergence of subcutaneous emphysema, the difficulty to evaluate the synovial membrane and hyaline cartilage, the vision that can be obscured by gas bubbles (whether or not caused by a portal-related leakage) or due to soiling of the lens by blood and fluid. This technique is incompatible with the use of electrosurgical instruments and motorized instruments like shavers (Strobel, 2002). Because of the fact there is no irrigation during surgery extensive lavage with 500-5000ml of lactated Ringer's at the end of the procedure is recommended (Boening 2005, Luciani 2008).

The pressure and flow rate of gas and liquid should be kept at safe levels and be capable of delivering necessary flow rate on demand. Most of the pumps provide pressures varying from 0 to 150 mmHg and fluid flows as high as 2 L/min. Some pumps can even provide a maximum pressure of 313 mmHg (McIlwraith, 2005). When using gas as a distention medium, 80-100 mmHg of any gas appears to be sufficient for a good arthroscopic view (McIlwraith, 2005). Luciani et al. (2008) investigated a high pressure technique using CO₂ gas with a pressure of 250-300 mmHg. Performing these arthroscopic surgeries using high pressure techniques seem to be effective in 100% of the cases. The surgeries were easy to

perform and there were no anesthetic complications like ETCO₂ changes. Subcutaneous emphysema was always present after surgery but none of the horses showed any signs of acute pain. This subcutaneous emphysema resolved by itself within 6-24 hours after surgery (Luciani, 2008). Specific for stifle arthroscopy, high gas pressure improved the visualization, especially for the femoropatellar joint (Luciani, 2008).

In cadaver studies the surgical techniques for creating (osteo-)chondral defects have been tested. Gas appears to be preferred because this creates the best opportunity to insert the scaffold and raises the possibility to use glue as an adhesive to ensure the scaffold in the defect. Also, scaffold in gel composition need a dry environment in order to polymerize. Therefore the use of fluid as a distention medium should be excluded. The advantages and disadvantages as described above were confirmed during tests on cadaveric equine stifles. The use of gas gives a better intra-operative view, therefore it is easier to determine the position of the arthroscope on the trochlear ridge. Unfortunately there is an additional disadvantage when using gas as a distention medium in a (osteo-)chondral defect model: To insert the sleeve and drill to create a defect, a portal has to be made. This portal must at least be 1 cm wide for most instruments to be sufficient to fit through. As a result, the gas can leak through the incisions and the joint will collapse. To avoid the gas from leaking through the incision the surgeon can place a cap on top to cover the sleeve. It is important to make sure the incision is smaller in diameter at the level of the joint capsule compared to the diameter at skin level. This will ensure less gas leakage subcutaneously and development of subcutaneous emphysema. In theory a tube with an inflatable cuff could be invented to insert into the incision and enclose the joint space from the surroundings. This device should be flexible, wide enough for an 11 mm sleeve to fit through, and thereby not longer than this sleeve. After inserting the tube into the incision, the cuff must be inflated underneath the joint capsule to secure this position.

3.3 Wound closure

After using gas as a distention medium lavaging with 500-5000 ml of lactated Ringer's is recommended. The joint capsule does sometimes not need any suture after the procedure, this depends on the stab incision size. Only one or two sutures are placed in the skin incision using a simple interrupted pattern (McIlwraith, 2005). This non-absorbable suture material is removed after 7-10 days post surgery.




4. Defect creation and scaffold implantation

To create standardized subchondral defects there are certain requirements on the defect size, location, and materials. Also, the technique of placing a scaffold needs some practical instructions to be applied in a standardized model.

4.1 Material

The required drill bit must have multiple properties due to the fact that cartilage is slippery on surface, the subchondral bone is firm and swath material should not stay behind in the joint space. Exact and careful positioning of the drill bit is important. The drill bit should not slip off the cartilage surface and damage surrounding cartilage. The surgeon must be

able to keep the drill perpendicular on the cartilage surface to drill a 90 degree defect. The drill bit must be firm and sharp, it is not allowed to break when used during surgery and it should be sharp enough to penetrate the subchondral bone (Auer, 2006). Breakage and slipping off the superficial cartilage layer can be prevented by using a sleeve as a drill guide. This sleeve should be stabilized into the cartilage to ensure exact positioning of the drill bit. Also, swath material can be removed easily through this sleeve. The preferred shape of the defect is a cylinder, because most scaffolds are cylindrical shaped as well. The depth of the defect should be equal and the edges of the defects smooth. The drill bit or drilling machine needs an adaptable depth measure. Because the cartilage surface is heat intolerant, heat production of the drill bit should be limited. Heat production can be limited by drilling at maximal speed and for short periods (Fackelman, 2000). A battery powered Colibri® drill (Synthes, West Chester, Pa) is suitable. This drill can be sterilized after use, to ensure aseptically conditions. All properties of the different drill bits are displayed in the Figure 1.

	Drill bit	Not slipping on surface	Perpendicular on surface	Non breakable	Sharp enough to penetrate subchondral bone	Depth of defect equal	Smooth edges of defect	Swath material easily removed	Heat production limited	Depth can be adjusted
1		✓	✓		✓		✓		✓	✓
2			✓	✓	✓	✓			✓	✓
3			✓	✓	✓					✓





4		✓	✓	✓			✓			✓
5			✓	✓	✓		✓	✓		✓
6		✓	✓	✓			✓	✓		✓
7		✓	✓	✓	✓		✓	✓	✓	✓

Fig. 1. Overview of materials for osteochondral defect creation. 1: Wood cutter 2: Metal cutting spade 3: Plug cutter 4: Brad point drill bit 5: Diamond drill bit 6: Karl Storz surgical drill bit 7: Diamond drill bit in Arthrex sleeve

As figure 1 display, drill bit #5 matches with most properties required. Only swath material cannot be removed easily, and the drill bit slides off the cartilage surface when drilling is started. Therefore, drill bit # 5 should be used in combination with a sleeve. The sleeve displayed in table 2 is an Arthrex single-use osteochondral autograft transfer system (OATS). Also, this sleeve contains parallel bands on the distal end that display depth. These bands can be used to determine perpendicular placement of the sleeve on the cartilage surface.

4.2 Cartilage thickness

Models for standardized cartilage defects in the femoropatellar, femorotibial and tibiotarsal joints of the horse have been developed (McIlwraith, 2011).

A thorough study is done after cartilage thickness on different locations in the equine stifle by Frisbie et al. (2006). The average thickness of the non-calcified layer is 2.0 mm on the medial femoral condyle, and between 1,5-2.0 mm on the trochlear ridges. The calcified layer has an average thickness of 0,2 mm. The sum of calcified cartilage and non-calcified cartilage ranges from 1,8-2,2 mm, which is among all animal models the closest

approximation to human articular cartilage thickness of 2,2-2,5 mm. (see figure 2) (Frisbie, 2006). Another important reason for preference for the equine stifle model is the ability to perform arthroscopic assessment. Both surgical methods as well as diagnostic arthroscopy are possible.

Cartilage thickness can be measured in situ by using an ultrasound indentation instrument. A 3 mm in diameter 10 MHz broadband ultrasound transducer can be brought into the joint by arthroscopic assessment (Brommer, 2005). Cartilage thickness can be calculated by determining ultrasound flight time (TOF) between cartilage surface and subchondral bone (Brommer, 2005). This method is non-destructive. Another method used for determining cartilage thickness is a needle-probe technique. With this slightly destructive technique a penetrating needle is used to determine articular thickness. (Jurvelin 1995, Brommer 2005) Both methods give highly similar outcomes. Thickness of articular cartilage in the equine metacarpophalangeal joint was in average 0,76 mm. (Brommer, 2005). Also, MRI is available to determine articular cartilage thickness in vivo. Unfortunately, MRI is not yet available to evaluate cartilage of the equine stifle in vivo due to the size of the horse. However, MRI in vivo evaluation is possible in the tibiotarsal joint (Latorre, 2006). In an experiment with 16 equine carpal joint were no significant differences found between MRI and histology measurements of articular cartilage and subchondral bone. (Murray, 2005). However, the equine stifle is not suitable for MRI assessment because of its size.

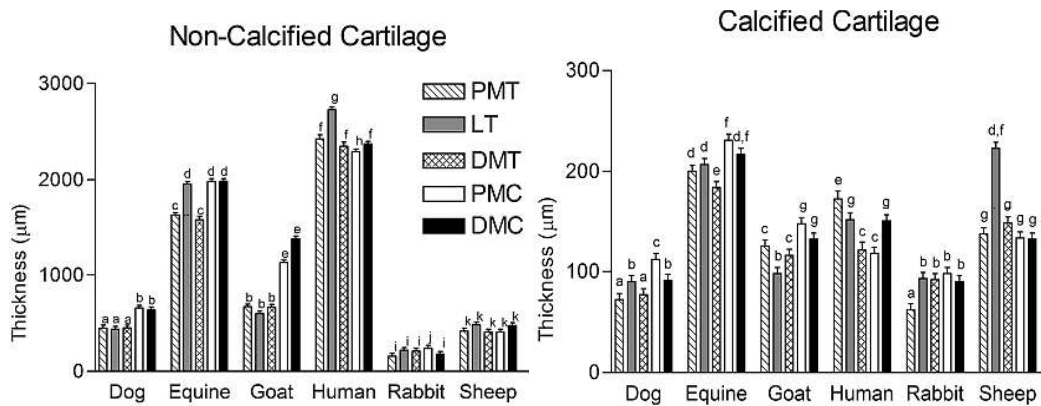


Fig. 2. Cartilage thickness in different animal species at different joint locations

Depth of the created defect can vary, a partial thickness lesion only includes the cartilage layer up to the calcified layer. Articular cartilage thickness varies between different joints and joint locations. Therefore depth of a partial thickness defect should be determined after knowing the location of the lesion (Hurtig, 1988).

While creating a lesion for subchondral scaffold implantation, a relative large subchondral layer has to be taken out in order to ensure the scaffold stays in place. Commercially available osteochondral scaffolds used in the equine stifle model are usually around 8 mm in length (Gleeson, 2012). If the scaffolds are shorter in length than in diameter it is not possible to create a stable fixation and the scaffold might fall out of the defect.

Depth of the created defect can be determined by using a stop device on the drill. While using a sleeve, the drill has to be long enough to fit through the sleeve and still leave enough length to penetrate into the subchondral bone at the required depth. To confirm the depth of the lesion a digital measuring device can be used on all sides of the lesion, to ensure depth is equal in the entire lesion. Also, markers on the Arthrex sleeve (see figure 3) can be a good measuring device to check the depth of the created defect. These parallel bands are spaced 2 mm apart and they can easily be viewed by the arthroscope (see figure 3). This method is especially useful during arthroscopy because inserting a digital measuring device aseptically is not as practical as using the sleeve that is already inserted at the location of the defect.

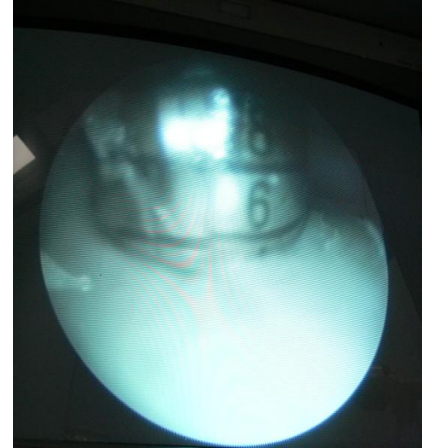


Fig. 3. Arthroscopic view of Arthrex sleeve as measuring device

4.3 Defect size

Defects for osteochondral scaffold implantation in the equine stifle should be at least the critical size of 9 mm. Convery et al performed a study to determine the minimal size of a defect on the weight bearing surface of the medial femoral condyle. Defects of 3 mm were completely repaired after 3 months, but defects of 9, 11 and 15 mm failed to heal after 9 months. Hurtig et al. (1988) determined the critical-size defects in the lateral trochlear ridge. Small weight bearing defects healed better than large (15 mm) weight bearing and non-weight bearing lesions. 5 mm diameter lesions were not large enough to be considered critical size. On the medial trochlear ridge defects of 15 mm are created in cartilage transplantation tests to ensure that the minimal size is achieved. 9 mm is considered to be the minimal critical size at any location of the equine stifle (McIlwraith, 2011).

4.4 Defect location

Chondral and subchondral defects can be created to study the repair process of cartilage (Convery, 1972). These defects can be created on non- weight-bearing or weight-bearing areas of the joint. The medial and lateral compartments of the equine stifle are primary weight-bearing, where the femoropatellar joint is considered non weight-bearing during stall rest and hand walking (Ahern, 2009). Most osteochondral defects in horses are seen on the proximal 1/3 of the lateral trochlear ridge and on the medial femoral condyle. These locations are subjected to highest weight-bearing. A defect on the medial condyle of the equine stifle simulates a lesion on the medial femoral condyle in humans (McIlwraith, 2011).

To manage to create an equal defect, it is important to drill perpendicular onto the joint surface. Because the trochlea is round shaped it is important to pick a location on the trochlear ridge where the surface is flat. On both the lateral- and medial trochlea it is possible to create defects on the distal, middle or proximal part on approximately 1/3, 1/2 and 2/3 of the trochlea. The defect should be created halfway between the sulcus groove and the trochlear edge, although on the medial trochlear ridge a proximal defect should be

positioned slightly more towards the sulcus and a distal defect more towards the edge of the trochlea because this is where the surface is flattest (see figure 4). Some individual variation may be apparent although these relative measures are equal in most equine stifles.

During mini-arthrotomy, it is possible to determine the perpendicular angle by direct vision. By an arthroscopic approximation it is hard to determine the perpendicular angle by vision because the arthroscopic view is in a 30 degree angle while the scope is inserted perpendicular into the joint. Therefore, the angles of the different defect locations must be kept in mind by inserting the drill. By knowing the angles of the sagittal and horizontal plane of the different locations of the joint surface, it is possible to insert the drill at these locations at the same angle. It is important however to insert the drill at the exact correct location of the trochlear ridge, which can be a challenge also.

The angles of the different location are collected in table 1 below:

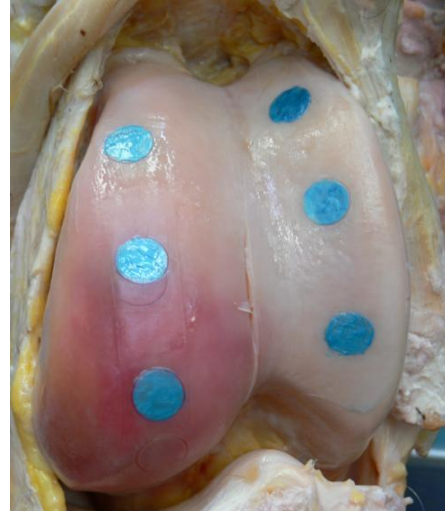


Fig. 4. Defect locations

Lateral Trochlea	Sagittal plane (degrees)	Horizontal plane (degrees)
Proximal	87	100
Middle	77	90
Distal	65	50
Medial Trochlea	Sagittal plane (degrees)	Horizontal plane (degrees)
Proximal	80	90
Middle	95	60
Distal	110	60

Table 1: Position of trochlea in sagittal and horizontal plane.

Another possibility to ensure a perpendicular angle of the drill onto the joint surface is by using a sleeve with parallel bands. While the joint space is sufficiently distended it is possible to determine if the sleeve is perpendicular placed by viewing the parallel bands from multiple views. Also, it is easy to adjust the position with arthroscopic guidance.

4.5 Defect creation and scaffold implantation

While the location is determined, the sleeve can be brought onto the surface. During arthrotomy, visual guidance is required to place the sleeve perpendicular. The superficial cartilage layer is soft enough to press the sleeve in manually. However, this does not create enough stability to keep the drill located without sliding over the surface.

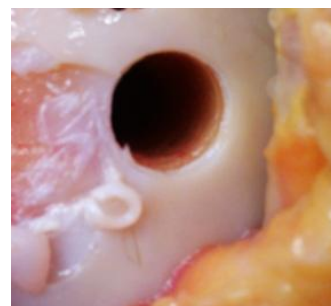


Fig. 5. Result of defect creation

Using a hammer, the sleeve can be brought 4-6 mm deep into the cartilage and create stable fixation. The parallel bands on the sleeve allow determination of the exact depth and perpendicularity of the sleeve.

During arthroscopy, the technique of defect creation is basically similar, but practical implementation differs from the technique described above.

Localization of the defect is more challenging; therefore a thorough investigation of the joint surface is required to determine the optimal placement of the sleeve. The incision must be made exactly above the desired location. Inserting a needle can be helpful to determine the position of the incision. The incision must be tapered towards the skin, to ensure gas or fluid leakage towards the subcutaneous layer. Penetration of the sleeve should be performed with care, to avoid scratching surrounding cartilage surface. Positioning is determined by using parallel bands on the sleeve that can be viewed by arthroscopic camera as guidance for perpendicularity, as described above. Again, a hammer is needed to ensure placement of the sleeve 6 mm into the cartilage.

The drill bit has to be adapted to the desired depth. The drill with drill bit can now be inserted into the sleeve while the sleeve is maintained in position. It is important to turn on the drilling machine gently while the drill bit anchors to the cartilage. Thereafter, drilling should be continued on maximal speed to limit heat production. Swath material on the drill bit is then removed through the sleeve and the sleeve stays positioned for scaffold implantation.

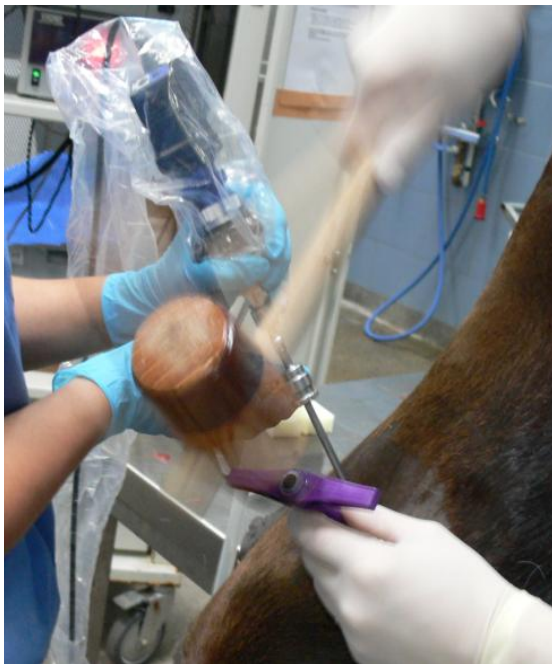


Fig. 6. Hammering the sleeve into the cartilage

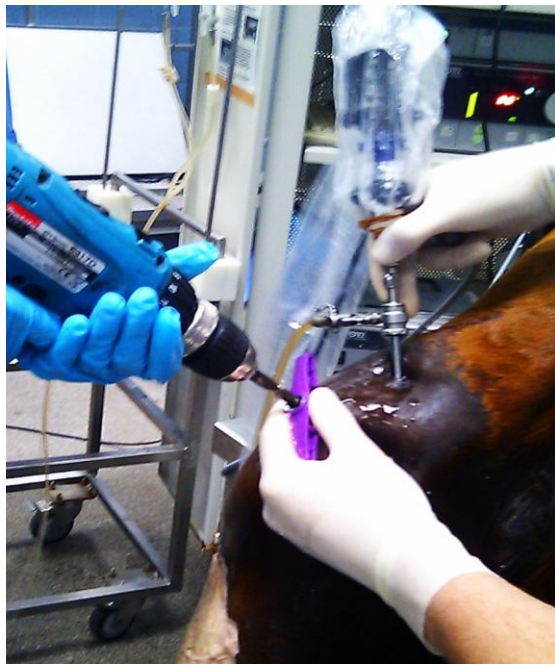

Fig. 7. Arthroscopic defect creation

Scaffolds for implantation exist in different compositions. Most used scaffolds are in either gel, sponge-like or firm porous composition. For implantation of a gel composition, the defect surface needs to be dried with a sterile swab through the sleeve. After, the gel can be injected through the sleeve using a long pipette. A sponge-like scaffold needs to be secured into the defect by using an adhesive like fibrin glue (Bhosale, 2008) or autologous

fibrinogen (McIlwraith, 2005). After depositing fibrin glue the scaffold is inserted into the sleeve and is pushed toward the defect with a non-sharp device that is at least the same diameter as the scaffold, to avoid damaging the scaffold (Anbari, 2008). A firm porous scaffold can be secured in place by press-fitting. The size of the sleeve has to be one millimeter larger than the scaffold used to allow the scaffold to fit through the sleeve (Anbari, 2008). The scaffold has to be the same diameter as the created defect, which is one millimeter larger than the size of the drill bit used, although the length of the scaffold has to be one millimeter shorter than the depth of the defect.

5. Post-operative management

5.1 Complications: per- and postoperative complications

During any surgical procedure complications like bleeding, sepsis or anesthetic related problems may occur. There are specific intraoperative complications described while performing arthroscopy. The most common are hemarthrosis, obstruction of view by synovial villi, extravasation of fluid or gas, iatrogenic damage to the articular cartilage and other tissues and intrasynovial instrument breakage. Hemarthrosis and obstruction of the view by synovial villi is minimized with distention, particularly while using gas as a distention medium. The extravasation of fluid or gas into the subcutis and other fascial layers is mainly caused by the shape of the instrument portals. There is an excessive perfusion pressure in the presence of obstructed outflow. A tapered shaped incision should be made to minimize the amount of fluid or gas extravasation. Care should be taken when manipulating the instruments in the joint space. Iatrogenic damage to the articular cartilage mostly occur when the joint is not maximally distended (McIlwraith, 2005). When determining the location for defect creation it is important to keep the Arthrex sleeve in view and to create the incision in the required angle to the trochlear ridge, to minimize cartilage damage.

Besides these complications, specific problems related to joint surgery, like septic joint infection, wound infection and cellulitis may occur post-operatively (Auer, 2006). Post-operative surgical site infections are a serious complication and a major source of morbidity and potentially mortality. Despite aseptic procedures and prophylactic antibiotics, post surgical infections remain problematic in the horse. Infection occurs within 30 days after surgical procedure and may involve only the skin or subcutaneous tissue or also deeper tissues like fascial and muscle layers. If an implant is left in place an infection can occur within one year post-surgery. Bacteria are the most common agents capable of causing surgical site infections in horses. The larger the incision made during mini-arthrotomy the greater the risk of surgical site infection compared to small incision portals made during arthroscopy. The most common pathogens after joint surgery are *Staphylococci*, *Enterobacteriaceae*, *Streptococcus*, *Pseudomonas* and anaerobes (Auer, 2006). Swabbing the infection site to culture the causative agent and an antibiogram can be performed is recommended so that an appropriate antibiotic can be selected. Also Methicilline-Resistant-*Staphylococcus Aureus* (MRSA) can be a serious problem in the equine patient because they are unresponsive to most antibiotics. When the implant or suturing material is infected the infection cannot be eliminated with antibiotics until the implant or suture material is removed. Suturing material will dissolve or removed within

10 days, where the implant is required to stay in place for a much longer period, depending on the scaffold used, and is therefore a much more serious problem. Septic joint infection is another risk after stifle surgery. Clinical signs are joint effusion and severe lameness. Palpation of the joint is painful and the horse usually has a fever at the initial stage of joint infection. The diagnosis can be confirmed by synovial fluid aspiration using aseptic technique. White blood cell count is over 75.000 cells/dL, where normal synovial fluid contains less than 300 white blood cells/dL. Gross appearance of the synovial fluid can be cloudy. Also the relative neutrophils are raised from 10% in healthy synovial up to 80-90% in a septic joint. A rapid treatment exists of (repeated) joint lavage and intra-articular antibiotics. Costs of these procedures are high and prognosis for athletic use is 50% (Auer, 2006). A problem unique to the stifle is that edema and inflammation between the fascial layers of the stifle can cause cellulitis and/or fasciitis. Therefore NSAID's are administered for 5 to 7 days post surgery as well as antimicrobial drugs (McIlwraith 2005, McIlwraith 1987).

5.2 Post-operative medicine

Post-operative antibiotics and anti-inflammatory medicine are indicated after mini-arthrotomy and arthroscopy to prevent bacterial joint infection. Broad spectrum antibiotics are indicated where opportunistic bacteria are present at the site of surgery. An example for antibiotic treatment is Penicillin and Gentamycin. To attain a high titer during surgery, prophylactic antibiotics should be given pre-operatively. As a Penicillin, Benzyl-Penicillin is available for intra-venous administration. Procaine-penicillin suspension can be administered intramusculair after surgery daily for 5 days, starting after wound closure during surgery. Gentamycin is available for intra-venous use, and should be given pre-operative and daily for 5 days post-surgery.

For management of post operative inflammation NSAID's are indicated. These NSAID's inhibit COX-1 and COX-2 production and therefore the production of prostaglandine E (PGE), which is the main factor involving in pain, inflammation, altered cartilage metabolism and joint damage (Auer, 2006). Therefore it is advisable to administer a NSAID for the first 5 days post-operative. This therapy could be extended if clinical parameters, like joint effusion or pain, are present.

5.3 Rehabilitation

Rehabilitation after cartilage repair surgery is an important factor to accomplish the best recovery of function. In human, there is much interest in the best possible rehabilitation method to return an athlete back into sporting activity (Mithoefer, 2011). The healing process is divided into multiple stages. The first 2 weeks are termed the inflammatory phase (Reiss, 2011) and is based on a grafts integration and stimulation. An implant needs time to become viable with its surrounding tissue (García-Sanz, 2011). In this stage protection of the joint and inserted scaffold is of great importance. High compressive stresses should be avoided, although passive motion of the joint promotes cartilage formation. The range of motion and the amount of weight bearing allowed is at this stage determined by size, but more so the location of the cartilage defect, but should be limited. Athletes with defects in the non-weight bearing femoropatellar joint are allowed to load

weight almost immediately after surgery, where defects on the weight-bearing femoral surfaces need protection (Kuroki, 2011). Also the angle of bearing weight differs for each location. Anterior femoral lesion should not be loaded in extension, where posterior condyle lesions and trochlear lesion should not be loading weight while flexed at angles more than 30 degrees (Karnatzikos, 2011). Of course the clinical signs of an individual should be used as a guide for rehabilitation management. Joint effusion and pain should be noted as they can be an indication of overload of the cartilage repair tissue (Mithoefer, 2011). The second stage, called remodeling phase at week 3-7 (Reiss, 2011), controlled exercise is needed to stimulate cellular metabolism, proteoglycan and collagen deposition and organization of the matrix. In this stage also neuromuscular restoration is critical, because it helps prevent re-injury by stabilizing the joint. Exercise should gradually progress as the repair cartilage tissue needs to adapt to the increased mechanical stresses. In the next rehabilitation stage, regenerating cartilage needs to mature and gain rigidity by further proteoglycan cross linking, collagen production and cellular organization (Mithoefer, 2011). Therefore this phase is called load progression. (Reiss, 2011) Finally, a patient needs to be able to return to its normal daily exercise schedule. Sport-specific exercises should also be increased gradually and should always be guided by clinical signs such as joint effusion and pain (Mithoefer, 2011).

Different studies have shown that flexion, rotating or sliding velocity on the surface of the cartilage scaffold up-regulates protein expression of lubricin and proteoglycans (Grad, 2011). Lubricin keeps the joint fluid lubricated, and therefore prevents friction that could lead to damage to the articular cartilage layer. Proteoglycans provide osmotic resistance necessary to resist compressive loads on cartilage (Sciliari, 2011). Also, movement of the synovial fluid can support chondrocyte physiology (García-Sanz, 2011). Complications of full immobilization include arthrofibrosis, joint adhesions, pain and muscle atrophy (Kreulen, 2011). Because of positive effects of joint motion, continuous passive motion (CPM) is used for rehabilitation in human after cartilage surgery in the knee. This home-use machine flexes the knee joint at set angles. Usually, the angle increases from 30 degrees on the first day after surgery, until 90 degrees at week 8 (Quanyi, 2011). Weight bearing is adapted gradually, as humans are able to use one or two crutches and a brace. Starting to bear 20% weight in the second week after surgery will lead to full weight bearing at week 8, with sensing least pain on a VAS pain scale (Ebert, 2011).

Rehabilitation of horses after undergoing arthroscopy of mini-arthrotomy is very different to human. In contrast to human, the affected limb of a horse does not get protected for weight bearing or restricted in range of motion after surgery, but joint loading start as early as during recovery from anesthesia (Chu, 2010).

In clinical studies, different exercise protocols are used for different joint locations and treatments. In general, all horses get stall confinement for at least the first two weeks after surgery, until the stitches are allowed to be taken out. In an experiment of intra-articular administration on autologous conditioned serum during bilateral arthroscopic surgery of the middle carpal joint horses started exercising on a treadmill on day 15. The horses underwent trotting and galloping for 6 minutes 5 days a week to simulate race training (Frisbie, 2007).

Postoperative procedure in arthroscopically performed defect creation in carpi and stifles contained 2 weeks of stall confinement to keep compressive forces as low as possible. After, hand-walking gets increased with 5 minutes daily up to 30 minutes daily. 4 months

after surgery treadmill exercise was added to simulate athletic exercise. Also, pasture turnout could be an alternative for treadmill exercise if athletic exercise is not necessary for the study (McIlwraith, 2011). Nixon et al. (2011) required 4 weeks of stall confinement followed by 4 weeks of brief hand walking after a femoropatellar mini-arthrotomy to investigate cartilage repair after autologous chondrocyte implantation in full- thickness and partial-thickness defects (Nixon, 2011). Because mini-arthrotomy is more invasive compared to arthroscopy, a slower rehabilitation is often required for wound healing. Some surgeons do not only require stall rest after a mini-arthrotomy, but maintain the horse in standing position for the first 2-3 weeks after surgery. This could be achieved by attaching a lead shank to a wire across the stall. Stall rest with brief hand walking is allowed until week 6, and after the horses can be turned out in a small paddock. Training is not resumed until the 4th month after surgery (McIlwraith, 1987).

Decision about the ideal rehabilitation procedure remains empiric but it is important to create a standardized rehabilitation process to compare different osteochondral defect treatments to achieve valuable, comparable results. It would be preferable to translate the human studies after best rehabilitation methods into exercise schedules for horses. Although because of the size of a horse and its temperament this might be hard to realize. The best practical solution for a more controlled recovery is to assist the horse while raising with ropes on the head and tail. This is the best way to prevent the horse from falling down again after getting up. If defects are created in the femoropatellar joint, stall-rest and hand walking is considered to be non- weight bearing (Ahern, 2009). Also, wound sutures should be taken out before the horse is allowed to exercise. Complete stall rest for the first week is therefore required. Week 2 should still be considered as inflammatory phase and stall rest should be advised during this period as well. Because passive motion does promote cartilage production it is not possible to keep the horse tied. Moving around in a box stall on a thick layer of bedding could be considered as passive motion. Although, if the horse's temperament does not allow it to behave quietly in a box stall, a small dose of sedation could be administered when needed. After the inflammatory phase the remodeling phase starts. Now it is important to start limited exercise to promote cartilage formation. Hand walking should be started and increased with 5 minutes per week. It is again important to keep the horse quiet and sharp turns should be avoided to prevent the stifle joints from loading extra weight. After 6 weeks load progression is needed to organize matrix formation. Treadmill exercise is a useful tool to achieve controlled exercise. Again, starting and increasing with 5 minutes of trot per week, up to 30 minutes, should be sufficient to let the repair tissue adapt to increased weight bearing. Cantering could be added with 2 minute bouts at 12 weeks after exercise. Turnout is unadvisable because horses are likely to perform abrupt movements, even in a small paddock. Also, gradual increase of exercise is hard to achieve with turnout. After approximately 4 months the horse should be able to return to full exercise. Clinical signs like joint effusion or pain should always be used as a guide, and the training schedule should be adjusted if any of these signs are present.

6. Conclusion

A standardized model for (osteo-)chondral defect creation and scaffold implantation needs to be developed. In this study an attempt was made to develop an optimal surgical protocol

that would allow replication by other researchers. Arthroscopy while using gas as a distention medium is preferred for scaffold implantation because it is minimally invasive, although this technique is more challenging than mini-arthrotomy and therefore it is difficult to elicit variation between different surgeons. Also, because of individual anatomic differences in horses the location for defect creation can vary. Using a diamond drill bit through an Arthrex sleeve allows proper positioning, exact depth measuring, minimizes spilling of swath material in the joint space and gas leakage. To standardize a rehabilitation protocol, human studies of rehabilitation after cartilage repair can be used, although limitations are present because of the inherent characteristics of the horse namely its size and character. Further research in both cadaveric and in vivo models should be performed after surgical cartilage repair procedures to be able to standardize a (osteo-)chondral defect model.

7. References

- Ahern B.J. et al. (2009). Preclinical animal models in single site cartilage defect testing: A systemic review. *Osteoarthritis and Cartilage*, 17(6), 705-713.
- Anbari A. et al. (2008). Osteochondral autograft transplantation. *Procedure* 11, 180-190.
- Auer A., Stick J., (2006) Equine Surgery 3th edition, *Elsevier Inc.*
- Boening K.J., Niederhofer M., (2005). How to use gas distension in equine arthroscopy. *AAEP Proceedings*, 51.
- Bramlage L., (2009). The effect of traumatic and developmental fragmentation in the joint. *Proceedings 55th Annual Convention of the American Association of the Equine Practitioners*, December 5-9.
- Brommer H. et al. (2005). Influence of age, site, and degenerative state on the speed of sound in equine articular cartilage. *American Journal of Veterinary Research*, 66(7), 1175-1180.
- Changoor A. et al. (2006). Mapping of donor and recipient site properties for osteochondral graft reconstruction of subchondral cystic lesions in the equine stifle joint. *Equine Veterinary Journal*, 38(4) 330-336.
- Chu C.R. et al. (2010). Animal models for cartilage regeneration and repair. *Tissue Engineering – Part B: Reviews*, 16(1), 105-115.
- Convery F.R. et al. (1972). The repair of large osteochondral defect. An experimental study in horses. *Clinical Orthopaedics and Related Research*, 82, 253-262.
- Ebert J. et al. (2011). Clinical, radiological and biomechanical outcomes of a randomized comparison of conservative and accelerated approaches to post-operative weight bearing rehabilitation following MACI®. *International cartilage repair society*, issue 14, 29-30.

- Fackelman G. E. et al. (2000). Principles of equine osteosynthesis. *Thieme, Stuttgart*.
- Frisbie D.D. et al. (2006). A comparative study of articular cartilage thickness in the stifle of animal species used in human pre-clinical studies compared to articular cartilage thickness in the human knee. *Veterinary and Comparative Orthopaedics and Traumatology*, 19(3), 142-146.
- Frisbie D.D. et al. (2007). Clinical, biochemical, and histological effects of intra-articular administration of autologous conditioned serum in horses with experimentally induced osteoarthritis. *American Journal of Veterinary Research*, 68(3), 290-296.
- García-Sanz F. et al. (2011). Physiotherapy after cartilage repair: experience from Clinica CEMTRO (Spain). *International cartilage repair society, issue 14*, 35.
- Gleeson J.P. et al. (2012). Layered scaffold suitable for osteochondral repair. *Patent application publication*.
- Goodrich L.R., Nixon A.J. (2006). Medical treatment of osteoarthritis in the horse – A review. *Veterinary Journal*, 171(1), 51-69.
- Grad S. et al. (2011). Rehabilitation-*in vitro* investigations at the cellular level. *International cartilage repair society, issue 14*, 26-27.
- Gruenwald J.M. (1990). Fatal air embolism during arthroscopy. *Journal of Bone Joint Surgery*, 72-B: 929.
- Harmel J.L. et al. (2004). An assessment of equine cartilage degeneration. *Biomed Sci Instrum*. 40, 261-5.
- Hurtig M.B. et al. (1988). Effects of lesion size and location on equine cartilage repair. *Canadian Journal of Veterinary Research*, 52(1), 137-146.
- Jurvelin J.S. et al. (1995). Comparison of optical, needle probe and ultrasonic techniques for the measurement of articular cartilage thickness. *Journal of Biomechanics*, 28(2), 231-235.
- Karnatzikos G. et al. (2011). Rehabilitation protocol after cartilage repair with BMAC and a collagen-based matrix. *International cartilage repair society, issue 14*, 36-38.
- Kirpensteijn J., Klein W.R. (2006). The cutting edge. Basis operating skills for the veterinary surgeon. *Roman house publishers, London*.
- Kreulen C. et al. (2011). Post-operative matrix-induced autologous chondrocyte implantation of the talus rehabilitation. *International cartilage repair society, issue 14*, 38-39.

Kuroki H. et al. (2011). Care should especially be taken concerning knee joint angle and the contact area in rehabilitation planned following autologous osteochondral grafting for knee cartilage lesions: A report of two cases. *International cartilage repair society, issue 14*, 41-42.

Latorre R. et al. (2006). Correlation of magnetic resonance images with anatomic features of the equine tarsus. *American Journal of Veterinary Research*, 67(5), 756-761.

Luciani A. et al. (2008). High pressure gas distension in equine arthroscopy: technique and review. *Proceedings of the 10th International Congress of World Equine Veterinary Association*, 504-506.

Martin I.M. et al. (2006). Review: Osteochondral tissue engineering. *Journal of biomechanics*, 40(2007), 750-765.

Mithoefer, K. et al. (2011). Principles of rehabilitation after articular cartilage repair in the athlete. *International cartilage repair society, issue 14*, 22-23.

Murray R.C. et al. (2005). Validation of magnetic resonance imaging for measurement of equine articular cartilage and subchondral bone thickness. *American Journal of Veterinary Research*, 66(11), 1999-2005.

Nixon A.J. et al. (2011). Autologous chondrocyte implantation dries early chondrogenesis and organized repair in extensive full- and partial-thickness cartilage defects in an equine model. *Journal of Orthopaedic Research*, 29(7), 1121-1130.

Mellwraith W., Turner S. (1987). Equine surgery. Advanced techniques. *Lea & Febiger, Philadelphia (215) 922-1330*, 141-149.

Mellwraith W. (1996). General Pathobiology of the Joint and Response to Injury In: Trotter M, ed, *Joint Disease in the Horse*. Saunders, 40-70.

Mellwraith W., Nixon J., Wright I., Boening K. (2005). Diagnostic and surgical arthroscopy in the horse, 3rd edition, Elsevier.

Mellwraith W. et al. (2011). Equine models of articular cartilage repair. *Cartilage*, 2(4), 317-326.

O'Brien F.J. (2011). Biomaterials & scaffolds for tissue engineering. *Materials Today*, 14(3), 88-95.

Quanyi G. et al. (2011). CPM or not CPM after autologous chondrocyte transplantation? *International cartilage repair society, issue 14*, 27-28.

Reiss E., Kessler-Schär C., (2011). Customised postoperative therapy has a crucial impact

on the outcome of cartilage surgery. *International cartilage repair society, issue 14*, 31-33.

Sciliari A., (2011). Progressive joint loading after cartilage repair with autologous matrix-induced chondrogenesis (AMIC) with platelet rich plasma (PRP) augmentation: clinical experience in 220 patients. *International cartilage repair society, issue 14*, 31.

Strobel M.J., (2002). Manual of arthroscopic surgery. *Springer-Verlag, Berlin*, 52-54.

Weeren P.R. van, et al. (2010). Pain in osteoarthritis. *Veterinary Clinics of North America – Equine Practice*, 26(3), 619-642.

Wilke M. et al. (2007). Enhanced early chondrogenesis in articular defects following arthroscopic mesenchymal stem cell implantation in an equine model. *Journal of orthopaedic research*, 913-925.